



Launch issue
December 2015!

Reprints in Dermatology

A collection of Dermatology content
to test your diagnostic skills.
Written and peer reviewed by specialists for GPs

Reprints in Dermatology

Backed by more than fifty years of editorial excellence...

Medicine Today (formerly *Modern Medicine*) has been continuously published in Australia since 1957. Its publishers launched *Reprints in Dermatology* to provide a topic-specific, focused publication for GPs and other specialists.

Reprints in Dermatology delivers a dedicated dermatology-specific environment to showcase products directly to a targeted audience. Written and peer reviewed by specialists for a GP audience, and originally published in *Medicine Today*, the editorial content provides authoritative, practical clinical information and is commissioned following discussions with the Editorial Advisory Board and other senior consultants. All invited authors hold senior roles in their respective fields of medicine.

Reprints in Dermatology brings the most important clinical information to the forefront of doctors' minds in a peer reviewed publication devoted to dermatology.

What is Reprints in Dermatology and why does it matter to both GPs and dermatologists?

Dermatological disorders are estimated to represent 20% of conditions seen in general practice. Atopic dermatitis involves about 20% of children and psoriasis about 2% of the whole population. The Australian population is highly affected by skin cancer and conditions related to sun damage. Additionally, the issue of cosmetic dermatology is becoming a real issue with the ageing population. It is an exciting time in dermatological therapeutics with new biological agents to treat the more severe inflammatory skin diseases and laser therapy for a range of cosmetic conditions. The GP plays a key role in the diagnosis of dermatological conditions and provides shared care with the specialist. *Reprints in Dermatology* helps the Australian GP to readily access and consider up-to-date clinically relevant information from specialists in the dermatology field. Reader-friendly feature articles are used to support and upskill primary care health professionals in modern dermatology practice.

Reprints in Dermatology Editor-in-Chief...

**Associate Professor
Gayle Fischer**

MB BS, MD, FACD

Editor-in-Chief and Chair
of the Editorial Advisory
Board, Dermatology



Biography

Associate Professor Gayle Fischer is a senior Gynaecological and Paediatric Dermatologist at The Royal North Shore Hospital and an Associate Professor of Dermatology, Sydney Medical School Northern, The University of Sydney. Her main clinical and research interest is vulvovaginal skin disease. She has been working and researching in this field for more than 20 years and holds a Doctor of Medicine degree from the University of Sydney for her thesis 'Vulval disease in children and adults'. She is a member of Research Gate with a score in the top 10% of members. She has published more than 100 original scientific research articles in peer-reviewed journals and has been an invited speaker at local and international conferences. She is the co-author of a textbook on vulval disease and also a patient-focussed website, Care Down There. Associate Professor Fischer supervises PhD, Masters and Honours students. She has been Chief Examiner and Dean of Education as well as Board member of the Australasian College of Dermatologists and is a past president of the Australia and New Zealand Vulvovaginal Society. She is currently a member of the International Society for the Study of Vulvar Disease and the Society for Pediatric Dermatology.

Reprints in Dermatology

What our peer review process means to you...

Providing accuracy, credibility and independence, the peer review process is an indispensable part of *Medicine Today's* editorial process. Borrowing from this proven method, every article published in *Reprints in Dermatology* has been rigorously peer reviewed by a minimum of two expert consultants and by one general practitioner, who represents our main readership.

The reviewers provide instructive comments, suggestions and recommendations on the suitability for publication for each article. Authors receive detailed reports requesting revisions and responses to the comments before articles are accepted for publication.

The result is a consensus on each *Reprints in Dermatology* topic – meaning you can be sure your product message is delivered in the most credible, authoritative environment available to reach your target audience.

Every article is a basis for action, providing doctors with the most relevant, insightful and accurate consensus information achievable.

Editorial Advisory Board ... behind the scenes

Having major input into *Reprints in Dermatology* peer review process, commissioning program and author suggestions, the Editorial Advisory Board has a vital role in maintaining the journal's high editorial standards.

Advertising Standards

Advertisements submitted to *Reprints in Dermatology* are subject to editorial approval and have no influence on editorial content or presentation. Advertisers are responsible for ensuring that advertisements comply with Commonwealth and State and Territory laws and any industry code of conduct.

Editorial Policy

Reprints in Dermatology is a peer reviewed clinical journal and the editorial content is completely independent of advertising. All editorial material is embargoed before publication.

DERMATOLOGY CLINIC PEER REVIEWED

Loss of skin colour on a young girl's hands

ANDREW LEE MD
GAYLE FISHER MD

Test your diagnostic skills in our regular dermatology quiz. What is the cause of this loss of skin colour on a girl's hands?

Case presentation
A 10-year-old girl presents with multiple areas of asymptomatic loss of skin colour on both of her hands that has been present for some months (Figure). No hair has otherwise waned.

Differential diagnosis
Conditions to include in the differential diagnosis include the following:

- **Post-inflammatory hyperpigmentation.** An inflammatory process or injury typically results in darkening of the skin, not loss of skin colour. It is typically seen in areas of previous inflammation, such as the face, neck, and arms. It is not associated with hair loss.
- **Hereditary hypochromism.** This is a rare, autosomal recessive condition that results in loss of skin colour. It is typically seen in areas of previous inflammation, such as the face, neck, and arms. It is not associated with hair loss.

Diagnosis
The correct diagnosis is **vitiligo**. This is a chronic, autoimmune condition that results in loss of skin colour. It is typically seen in areas of previous inflammation, such as the face, neck, and arms. It is not associated with hair loss.



Figure shows areas of loss of skin colour on a girl's hands.

DERMATOLOGY CLINIC PEER REVIEWED

A boy with a purpuric rash of sudden onset

ANDREW LEE MD
GAYLE FISHER MD

Test your diagnostic skills in our regular dermatology quiz. What is the cause of this purpuric rash?

Case presentation
A 10-year-old boy presents to the emergency department of his local hospital with a purpuric rash of sudden onset on his hands and legs (Figure 1 and 2). He has fever and headache.

Differential diagnosis
Conditions to include in the differential diagnosis for a child of this age include the following:

- **Leukocytoclastic vasculitis.** This is the most common small vessel vasculitis. It is characterized by a purpuric, non-thrombocytopenic rash. It is typically seen in areas of previous inflammation, such as the face, neck, and arms. It is not associated with hair loss.
- **Henoch-Schönlein purpura.** This is a relatively common small vessel vasculitis. It is characterized by a purpuric, non-thrombocytopenic rash. It is typically seen in areas of previous inflammation, such as the face, neck, and arms. It is not associated with hair loss.

Diagnosis
The correct diagnosis is **Henoch-Schönlein purpura**. This is a relatively common small vessel vasculitis. It is characterized by a purpuric, non-thrombocytopenic rash. It is typically seen in areas of previous inflammation, such as the face, neck, and arms. It is not associated with hair loss.



Figure 1 and 2: The purpuric rash on the patient's hands and legs (see text).

78 | **Medicine Today** | AUGUST 2014, VOLUME 10, NUMBER 8

© 2014 by the Australian Medical Association. All rights reserved. Reproduction in whole or in part is prohibited without the prior written permission of the Australian Medical Association. For more information, please contact the Australian Medical Association, Locked Mail Bag 961, North Sydney, NSW 1585.

Reprints in Dermatology

Booking & Material Deadlines 2015

Issue	Booking Deadline	Material Deadline
December 2015	09 December 2015	16 December 2015
June 2016	07 May 2016	14 May 2016
December 2016	09 December 2016	16 December 2016

Circulation

General Practitioners	21,894
Dermatologist Specialists	496
Immunologists & Allergists	133
Miscellaneous subscribers (overseas doctors, etc)	491
Advertisers/agencies	609
TOTAL	23,623

4 Colour Display Advertising

All quoted rates are GST exclusive

Space	Rate (\$)
DPS	15,790
Junior DPS/Fireplace	12,100
Full page	7570
2/3 vertical	6980
1/2 horizontal*	5490
1/2 junior	5130
1/2 vertical	4970
1/3 horizontal*	4130
1/3 vertical	3250

* 1/2 and 1/3 page horizontals are available as nonbleed ads only, except when purchased as double page spreads.

Position Loadings

IFC, OBC an additional \$2000 (ex GST)

Note: where IFC is booked as spread, loading applies on second page only, i.e. an additional \$2000.

Fixed inserts*

2pp fixed insert: \$9841 (ex GST)

4pp fixed insert: \$19,682 (ex GST)

*printing additional, can be quoted on request.

Booking and delivery of material:

Prue Anderson, Group Sales & Marketing Manager
 Sarah Wylie, Sales Manager
 Cheree Lloyd, Sales & Marketing Coordinator
Reprints in Dermatology
 Suite 3, 134 Military Road, Neutral Bay NSW 2089
 PO Box 1473, Neutral Bay, NSW 2089
 Telephone: 02 9908 8577
 prueanderson@medicinetoday.com.au
 sarahwylie@medicinetoday.com.au
 chereelloyd@medicinetoday.com.au

Trading Terms

Agency commission of 10% is paid to advertising agencies for all accounts settled within 30 days from the end of the month of invoice.

Reprints in Dermatology

Mechanical Specifications

Reprints in Dermatology prefers ad material via Quickcut, a service provider for electronic delivery of digital files that has proven to be the most effective method of receiving and tracking your ad. As Quickcut provides the facility to check for errors, *Reprints in Dermatology* recommends that you use this service to avoid print errors.

Material delivery

- Quickcut – visit www.quickcut.com.au for more information
- Via email (up to 15 MB only) to:
prueanderson@medicinetoday.com.au
chereelloyd@medicinetoday.com.au
maria@medicinetoday.com.au
- CD

Material instructions

- Publication name (*Reprints in Dermatology*)
- Issue date
- Key number
- Ad size
- Special instruction/positioning

Electronic File Requirements (Hi-res Acrobat PDF only)

Hi-res Pdfs must be supplied with a minimum of 3 mm bleed and visible crop marks. Colour bars, crop marks and registration marks must be at least 5 mm away from trim.

CHECK LIST

Screen

- **Four colour** – 133 lines per inch

Colour

- Hi-res Pdfs must be supplied in CMYK
- RGB, PMS and Spot colours must be converted to process colour
- Total ink weight should not exceed 310% with a 90% black maximum

Images

- CMYK
- JPG or TIFF format
- Hi-resolution required, minimum of 300 dpi at 100% scaling
- Black and white line art, minimum 1200 dpi at 100% scaling
- All transparencies must be flattened

Type

- Postscript fonts or outline fonts should be used – do not use TrueType fonts
- All fonts should be embedded
- All live copy must be kept 10 mm from all edges
- Any type less than 10 pt bold is not suitable for reverse printing
- Body copy text that is black should be set to 100% black,

not a

4 colour makeup of black

- Solid black background areas should have an additional 30% of cyan tint to provide additional density

Proofs

- Supply a 3DAP digital colour proof of the artwork at 100%.

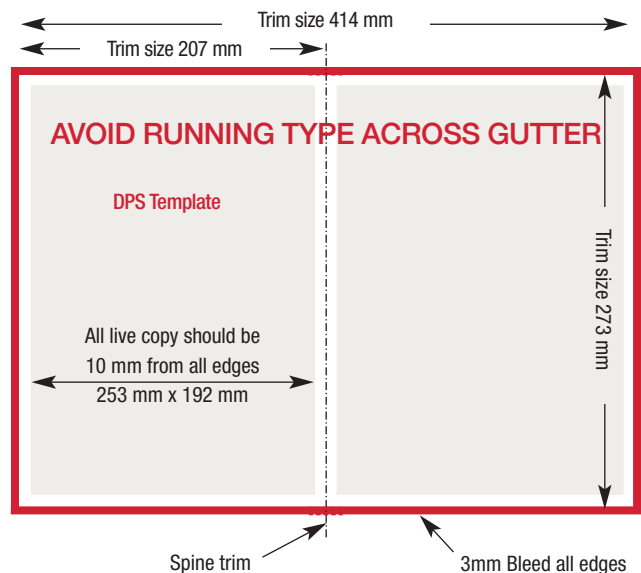
Note. *Reprints in Dermatology* cannot be held responsible for colour discrepancies in print if there are inaccuracies in electronic files supplied to us or if an industry standard proof is not provided.

If further technical information is required, visit: www.3dap.com.au

Although the internal production process may verify that material is within specification, the onus is placed firmly on the tradehouse/ sender to supply material to specification. It is also a requirement that advertising material is delivered on time so quality control measures can take place. Late material may miss these checking procedures that could pick up possible problems/errors.

Important Notes for Designers of Double Page Spreads (DPS) – Saddle Stitched

- DPS must be supplied as two single pages, left and right
- Include 3 mm bleed on all edges
- Avoid running type across the gutter on a DPS
- Spacing of letters in headings or large text should clear the gutter
- All live copy must be kept at least 10 mm from outer edges



Reprints in Dermatology

Journal Size

Trimmed size is 273 mm deep x 207 mm wide, saddle stitched.
Include 3 mm bleed on all edges.
All live copy must be kept at least 10 mm from outer edges.

Advertisement Sizes

See list of ad sizes on this page. Other sizes may be available upon application.

The grid displays 18 advertisement size templates, each with a grey rectangular area and a red border. The templates are arranged in four rows. Each template is surrounded by a grid of 'texttext' labels to indicate content placement. The sizes shown are:

- DPS 273 x 414
- Full Page 273 x 207
- 2/3 Vertical 273 x 132
- 1/2 Horizontal 125 x 174
- 1/2 Horizontal DPS 132 x 414
- 1/2 Vertical 273 x 102
- 1/2 Junior 185 x 132
- Junior Fireplace 185 x 264
- 1/3 Vertical 273 x 72
- 1/3 Horizontal 80 x 174
- 1/3 Horizontal DPS 90 x 414
- 1/3 Square 134 x 114
- Cameo 75 x 55

Ad sizes

(Depth x width)

DPS	Trim size	273 mm x 414 mm
	Bleed size	279 mm x 426 mm
	Type	253 mm x 374 mm
Full page	Trim size	273 mm x 207 mm
	Bleed size	279 mm x 213 mm
	Type	253 mm x 187 mm
2/3 page vertical	Trim size	273 mm x 132 mm
	Bleed size	279 mm x 138 mm
	Type	253 mm x 115 mm
1/2 page horizontal **	Trim size	125 mm x 174 mm
	Bleed size	-
	Type	115 mm x 174 mm
1/2 page junior *	Trim size	185 mm x 132 mm
	Bleed size	188 mm x 138 mm
	Type	165 mm x 110 mm
Junior fireplace *	Trim size	185 mm x 264 mm
	Bleed size	188 mm x 276 mm
	Type	165 mm x 220 mm
1/2 page vertical	Trim size	273 mm x 102 mm
	Bleed size	279 mm x 108 mm
	Type	253 mm x 85 mm
1/3 page horizontal **	Trim size	80 mm x 174 mm
	Bleed size	-
	Type	80 mm x 174 mm
1/3 page horizontal DPS *	Trim size	90 mm x 414 mm
	Bleed size	93 mm x 426 mm
	Type	80 mm x 374 mm
1/3 page vertical	Trim size	273 mm x 72 mm
	Bleed size	279 mm x 78 mm
	Type	253 mm x 55 mm
1/6 page vertical †	Trim size	120 mm x 55 mm
	Bleed size	-
	Type	120 mm x 55 mm
Cameo	Trim size	75 mm x 55 mm
	Bleed size	-
	Type	75 mm x 55 mm

* Not available for PI.

† Available as nonbleed ad only, except when purchased as a spread.

‡ Available for PI only.