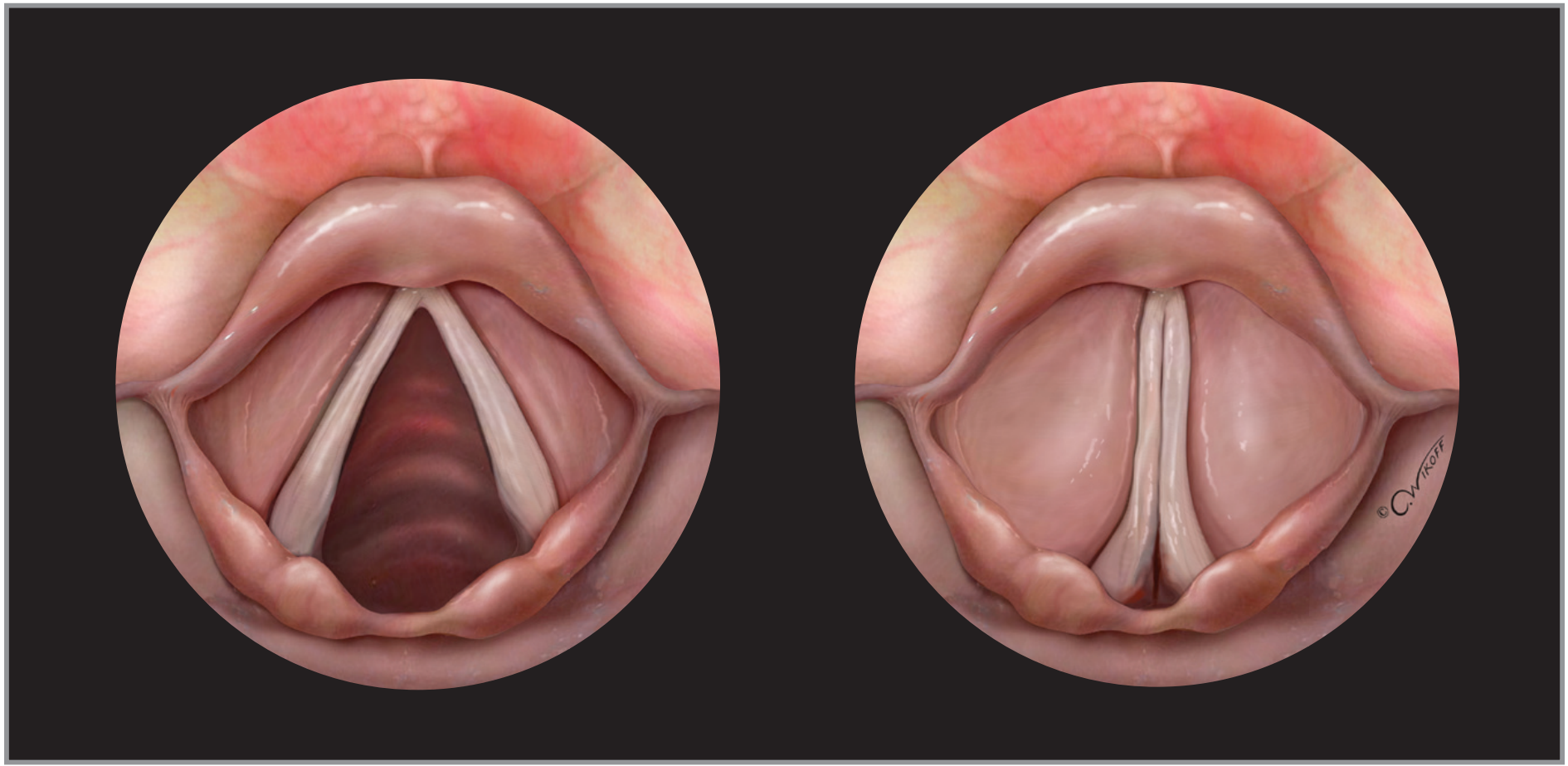

© CHRIS WIKOFF, 2017

Figures 1 a and b. The vocal cords. a (left) Normal vocal cords. b (right) Vocal cord dysfunction is characterised by abnormal adduction of the vocal cords.