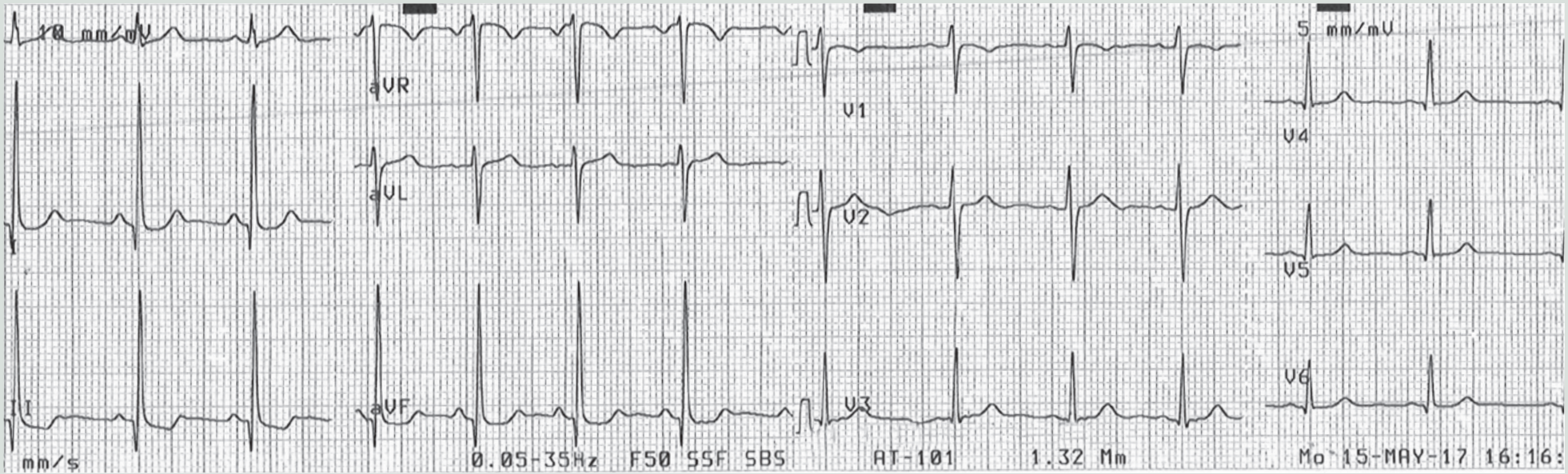

Figure. ECG in a 16-year-old-girl with postural orthostatic tachycardia syndrome.