

# Hidradenitis suppurativa

## What's new in pathogenesis and management

**KIRSTY J.L. WARK** BMedSci, BMed, MMed(ClinEpi)  
**GEOFFREY D. CAINS** MB BS, PhD, FACD

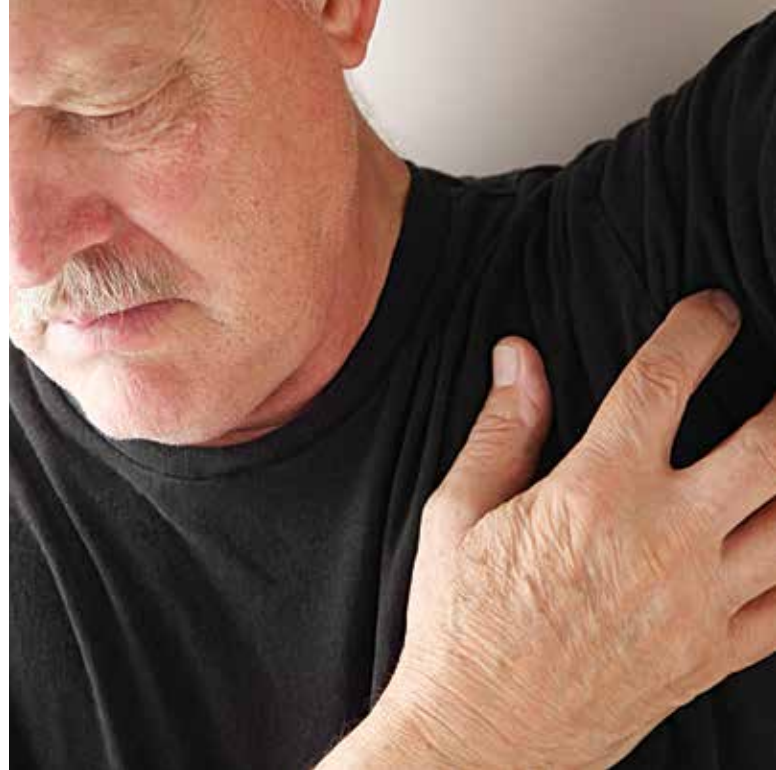
**Hidradenitis suppurativa is a chronic auto-inflammatory skin condition with significant comorbidities. Advances in our understanding of its pathogenesis are leading to new potential treatments.**

**H**idradenitis suppurativa (HS) is a chronic, autoinflammatory skin condition characterised by the development of inflammatory nodules and abscesses in intertriginous, hair-bearing areas.<sup>1</sup> It is associated with several comorbidities, including metabolic syndrome, polycystic ovary syndrome, inflammatory bowel disease (IBD) and depression.<sup>2-6</sup> The prevalence of HS is 1 to 4%, and it affects three times as many women as men.<sup>1</sup> HS is associated with a reduced quality of life, psychosocial impact and physical pain.<sup>7</sup> There is often a significant delay between disease onset and diagnosis, and this may be due to lack of recognition of the disease in its early stages in addition to poor awareness of HS among medical practitioners and the general public.

Over the past few years, our understanding of the pathogenesis of HS has evolved. This review focuses on evolving and emerging concepts of HS pathogenesis and its implications for management with biologic treatments. Diagnosis and first-line management of HS are summarised in the Box.

MedicineToday 2020; 21(2): 19-23

Dr Wark is a Dermatology Research Registrar at Liverpool Hospital; Conjoint Associate Lecturer in the School of Medicine, UNSW; and Member of the Dermatology Research Group, Ingham Institute of Applied Medical Sciences, Sydney. Associate Professor Cains is a Consultant Dermatologist in the Department of Dermatology, Liverpool Hospital; Associate Professor in the School of Medicine, UNSW; and Head of the Dermatology Research Group, Ingham Institute of Applied Medical Sciences, Sydney, NSW.



### KEY POINTS

- Hidradenitis suppurativa (HS) is an autoinflammatory skin condition involving the innate immune system.
- The pathogenesis of HS is not fully understood; inflammation has been regarded as secondary to follicular occlusion but is now considered the likely initial event.
- Genetics, the skin and gut microbiome and biofilms are also likely to play significant roles in HS pathogenesis.
- HS is part of the follicular occlusion tetrad, and evidence is emerging that the other members (acne conglobata, dissecting cellulitis of the scalp and pilonidal sinus) are anatomical variants of HS.
- Biologics such as interleukin-23 and interleukin-1 are emerging off-label treatments for patients with HS, although large-scale randomised clinical trials are lacking.

### Evolving models of pathogenesis of HS

The pathogenesis of HS is not fully understood. Classically, it has been considered an inflammatory skin disease triggered by occlusion of hair follicles, with secondary inflammation. New evidence suggest that HS should be considered a disease with multifactorial causes including genetic factors, the skin and gut microbiome, skin biofilms and dysregulation of the innate immune system.

### Genetic factors

About one-third of patients with HS have a family history of the disease.<sup>8</sup> Several genetic variants have been identified in the genes encoding the gamma-secretase enzyme complex, which regulates the function of the Notch cell membrane protein. Notch is responsible for normal skin function in humans and animals, and disruption of gamma-secretase function in mice has been shown to result in the formation of epidermal cysts and epidermal hyperplasia reminiscent of HS in humans.<sup>9</sup> However, most patients with

**DIAGNOSIS AND FIRST-LINE MANAGEMENT OF HIDRADENITIS SUPPURATIVA****Diagnosis of hidradenitis suppurativa**

Hidradenitis suppurativa (HS) is diagnosed based on history and clinical findings. There is no diagnostic test available.

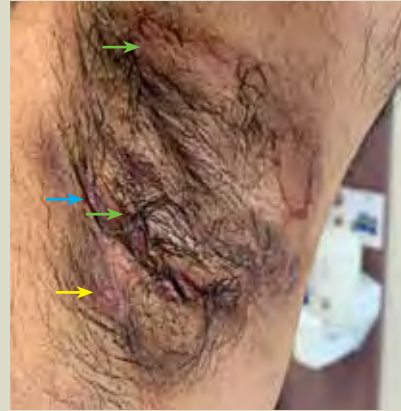Most commonly, patients report a history of recurrent painful 'boils' or abscesses in their axilla, groin, inframammary or abdominal fold areas. These lesions may have a malodorous exudate. Less commonly, patients with more extensive disease develop lesions in other areas, such as posterior ears, neck, limbs and trunk.

On examination, nodules and abscesses are usually present, with sinuses and hypertrophic scarring in more severe cases (Figure 1). Double-headed comedones are highly suggestive of HS, and their presence in the absence of inflammatory lesions suggests early or quiescent disease.

Common differential diagnoses for HS include acne, folliculitis and *Staphylococcus aureus* skin infections.

**First-line management**

- Antimicrobial chlorhexidine or triclosan-based body washes and gels, which are available over the counter, can be used daily.
- Topical clindamycin gel is appropriate to use in affected areas in patients with active inflammation, such as during flares.
- Oral doxycycline 100 mg daily or minocycline 50 mg twice daily should be used for three to four months to assess for response. If the patient's condition does not improve on treatment with one antibiotic, the other should be tried.
- Patients with HS should be assessed for comorbidities such as metabolic syndrome, polycystic ovary syndrome, depression and anxiety.
- Patients who smoke should receive smoking cessation counselling.
- Patients with a body mass index in the overweight or obese range should be encouraged to lose weight and referred where appropriate to a dietitian, physiotherapist or exercise physiologist to facilitate this. Low-friction exercise (such as swimming and aquarobics) is better tolerated by those with painful lesions and reduces the risk of worsening skin lesions.



**Figure 1.** Axilla in a patient with hidradenitis suppurativa, showing abscesses (green arrows), a draining sinus (yellow arrow) and early hypertrophic scarring (blue arrow).

- Most patients with HS should be referred to a dermatologist to confirm the diagnosis and facilitate access to biologic treatment for those with moderate-to-severe disease resistant to antibiotic therapy.
  - As well as antibiotics, antimicrobials and biologic therapies, other treatments for HS include:
    - antiandrogens in women
    - laser therapies
    - intralesional corticosteroid injections
    - short-term oral corticosteroids
    - surgical treatments, including incision and drainage, local excision and wide excision with skin grafting and deroofting.
- Most of these treatments should be guided by a dermatologist.
- Several hospitals across Australia run specialist HS clinics; contact your local hospital dermatology department for further information.

HS do not have mutations in the gamma-secretase complex genes, suggesting that pathogenesis is multifactorial.<sup>10</sup> Additionally, Notch disruption in mice via knock-out is associated with disrupted barrier function, epidermal differentiation and alopecia, which are not seen in humans with HS.<sup>11</sup> Caution is needed in interpreting results from animal models of HS.

**The skin microbiome and biofilms**

HS has previously been viewed as an infective disease. However, it is now recognised as an autoinflammatory condition with a significant burden of comorbidities associated with systemic inflammation.

Although the role of bacteria in disease pathogenesis requires further elucidation, the inflammatory process is thought to be driven by cutaneous microbiome dysbiosis.<sup>12</sup> A study showed that perilesional skin in affected individuals has greater microbial diversity than lesional skin.<sup>13</sup> The axillary microbiome has also been shown to be altered, with reduced diversity, in prelesional skin in affected individuals versus healthy controls.<sup>14</sup>

Biofilms, composed of bacteria and the extracellular matrix that they produce, have been identified in both chronic HS lesions and perilesional skin and are often associated with treatment resistance.<sup>15</sup> The

development of a biofilm may partly explain the chronicity and treatment resistance of lesions, as well as disease recurrence after surgical excision. Additionally, biofilms may be implicated in disease progression over time. It is known from chronic wound studies that biofilms cause host immune alterations and induce the release of proinflammatory cytokines.<sup>15</sup>

The cutaneous microbiome is a growing area of scientific interest in a number of skin diseases, and establishing what constitutes the 'normal' microbiota is a crucial next step. Similarly, ongoing research is needed to identify the role of biofilms in HS pathogenesis, progression and treatment resistance.

**TABLE. PHENOTYPES OF HIDRADENITIS SUPPURATIVA\*<sup>25</sup>**

	Paediatric group	Female group	Male group	Genetic group
Clinical presentation	<ul style="list-style-type: none"> <li>• Early onset</li> <li>• Axillary, groin and gluteal areas most often affected</li> </ul>	<ul style="list-style-type: none"> <li>• Predominantly axillary and inframammary involvement (Figure 2)</li> </ul>	<ul style="list-style-type: none"> <li>• Predominantly gluteal involvement</li> </ul>	<ul style="list-style-type: none"> <li>• Extensive, variable and severe cutaneous involvement</li> <li>• May involve typical areas (axillary, inguinal and gluteal) and atypical areas (posterior ears, neck and limbs, Figure 3)</li> </ul>
Disease associations	<ul style="list-style-type: none"> <li>• Often associated with latent metabolic conditions such as insulin resistance and PCOS</li> <li>• Patients usually overweight rather than obese</li> </ul>	<ul style="list-style-type: none"> <li>• Usually overweight or obese</li> <li>• Metabolic syndrome and PCOS</li> <li>• Often the highest burden of comorbidities and psychological distress</li> </ul>	<ul style="list-style-type: none"> <li>• Usually current smoker</li> <li>• Visceral rather than central adiposity</li> <li>• Associated with hyperlipidaemia</li> </ul>	<ul style="list-style-type: none"> <li>• Usually strong family history</li> <li>• Some cases may be a recognised syndromic variant, but not all fit these categories</li> </ul>
Management implications	<ul style="list-style-type: none"> <li>• Likely to progress in severity without aggressive management</li> <li>• Weight loss beneficial in halting progression to type 2 diabetes and normalising hormones</li> <li>• Laser hair removal may be of benefit in long term</li> </ul>	<ul style="list-style-type: none"> <li>• The most difficult phenotype to treat</li> <li>• Indication for early rather than late surgery to control disease</li> </ul>	<ul style="list-style-type: none"> <li>• Some individuals experience disease 'burn out'</li> </ul>	<ul style="list-style-type: none"> <li>• Evidence supports management with anti-IL-1-beta therapies</li> <li>• Should be referred for genetic counselling</li> </ul>

Abbreviations: IL-1-beta = interleukin 1-beta; PCOS = polycystic ovary syndrome.

\* Adapted from Vekic et al (2018).<sup>25</sup>

### Inflammatory pathways

Classically, HS has been considered a cutaneous disease characterised by follicular occlusion with a secondary inflammatory response. However, some evidence suggests that follicular occlusion is secondary to the underlying inflammatory process, thought to be driven by interleukin (IL)-1.<sup>12</sup> Additionally, the interleukins IL-12, IL-17 and IL-23 and tumour necrosis factor- $\alpha$  (TNF- $\alpha$ ) have all been identified in active HS lesions.<sup>16</sup> Phase 3 studies are now underway to assess the efficacy and safety of anti-IL-17 and anti-IL-23 treatments in patients with HS.

### The skin-gut-brain axis

The evolving skin-gut-brain axis model of skin disease may be applicable to HS. Neural and systemic inflammation secondary to gut dysbiosis may contribute to the association between HS and depression and anxiety via bidirectional signalling, rather than the link being exclusively a result of the experience of the physical symptoms and associated emotional impact of HS. Research in germ-free mice models has

shown depressive-like behaviours after transplantation of faecal microbiota from patients with major depressive disorder versus microbiota from healthy controls.<sup>17</sup>

Alterations in the gut microbiome can increase gut permeability, resulting in local and systemic inflammation through bacterial translocation, as seen in patients with non-alcoholic fatty liver disease.<sup>18</sup> Gastrointestinal microflora can also be associated with skin disease, as seen in the association between rosacea and *Helicobacter pylori*.<sup>19</sup>

The skin-gut axis may also explain the association between IBD and HS through alterations to gut microflora. IBD is associated with gut dysbiosis and impaired gut epithelial function.<sup>20</sup> Further research is required to establish this relationship.

### Emerging concepts in HS

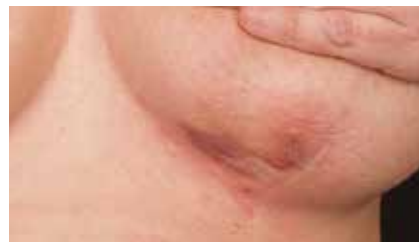#### Follicular occlusion tetrad

HS belongs to the follicular occlusion tetrad, which also includes acne conglobata, dissecting cellulitis of the scalp and pilonidal sinus. All four diseases in this tetrad share common histological and cytochemical findings, indicating that they

are likely to represent anatomical variants of a single disease process.<sup>21,22</sup> Further studies comparing histological, inflammatory mediator and clinical outcomes in these diseases are necessary to elucidate the true relationship.<sup>23</sup> It is likely that the local skin microbiome is involved.

### HS phenotypes

HS is not a homogeneous disease.<sup>10</sup> There is preliminary work on differentiating HS phenotypes.<sup>24</sup> A recent simple classification system into paediatric, female, male and genetic forms is based on age of onset, body site involvement and associated comorbidities (Table, Figure 2 and Figure 3).<sup>25</sup> It is



**Figure 2.** Inframammary lesions in a 38-year-old woman with hidradenitis suppurativa.

hoped that an improved definition of phenotypes will allow more targeted therapies and better understanding of prognosis.

Precise correlation between HS phenotype and genotype is not currently possible. This probably reflects the multiple factors involved in HS pathogenesis.

### Emerging treatments

Current systemic treatments for patients with HS include oral antibiotics and the TNF- $\alpha$  blocker adalimumab. Patients whose condition fails to respond adequately to these treatments currently have no alternative biologic treatment options available through the PBS in Australia. Recognition of the role of interleukins in HS has led to trials of interleukin inhibitors in the treatment of patients with HS. Some of these are available off-label and on compassionate grounds for patients with HS.

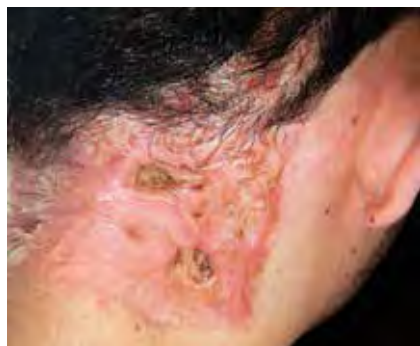Ustekinumab, an IL-12 and IL-23 inhibitor, was shown in a small open-label study to be effective in treating patients with HS. In this study, 47% of patients achieved a 50% or greater reduction in inflammatory lesion count.<sup>26</sup> Ustekinumab is not PBS listed for HS and is used off-label in Australia for these patients. Other IL-23 inhibitors such as tildrakizumab are used in Australia off-label via compassionate access. At present, several phase II trials of IL-23 inhibitors are underway.

Anakinra, an antagonist of IL-1 (a central proinflammatory cytokine), was shown in a small randomised controlled trial to be

effective in patients with moderate to severe HS; 78% of participants achieved a 50% or greater reduction in inflammatory lesion count.<sup>27</sup> Anakinra may be available via compassionate access for patients with treatment-resistant HS through dermatologists. It is not PBS listed for HS. Administration requires a daily injection, which some patients find painful.

Interleukin-17 has been identified in HS lesions, along with IL-1 and TNF- $\alpha$ .<sup>28</sup> The

efficacy and safety of anti-IL-17 biologic treatments in HS is under investigation, with phase III trials currently or soon to be underway. However, the association of HS with IBD is a concern. IL-17 is gut protective in mice models, with blocking of IL-17 associated with increased gut permeability.<sup>29</sup> As discussed above, increased gut permeability is implicated in bacterial translocation and disease pathogenesis. Exacerbations of IBD have been observed in trials of IL-17 biologics



**Figure 3.** Lesions on the back of the neck, an atypical area, in a 35-year-old man with hidradenitis suppurativa.

in patients with psoriasis, and their use is therefore avoided in those who have psoriasis and concomitant IBD.<sup>30</sup> Further human studies are required to assess whether IL-17 plays a similar role in gut homeostasis in humans as in mice.

### Implications for practice

Patients with HS should be screened extensively for comorbidities, such as metabolic syndrome, depression and

hyperandrogenism. Optimising treatment of these comorbidities is important to reduce HS disease severity and decrease systemic inflammation. Smoking cessation and weight loss should be strongly encouraged for the same reason. All patients with HS benefit from low-friction exercise such as swimming, as this improves concurrent metabolic syndrome and facilitates weight loss.

Additionally, patients with common comorbidities such as metabolic syndrome

and polycystic ovary syndrome should be screened for HS. This will help identify patients with mild HS, in whom treatments are more efficacious, and aggressive early management is likely to lead to optimal long-term outcomes. Patients with these comorbidities should be asked about blackheads, abscesses, nodules and pustular lesions in their axillary, inguinal and gluteal regions, and should also be examined for the presence of these lesions.

At present, the only biologic treatment for moderate-to-severe HS that is available on the PBS is adalimumab, a TNF- $\alpha$  blocker. This is a nonspecific targeted therapy that is used in other inflammatory conditions such as IBD and rheumatoid arthritis.

All patients with known or suspected HS should be referred to a dermatologist for review and specialist management. This will enable patients to access adalimumab, in addition to off-label and clinical trial treatments when clinically indicated.

### Conclusion

HS is a complex autoinflammatory disease associated with debilitating cutaneous manifestations and a high burden of comorbidities. Patients with HS should be extensively screened for associated comorbidities. Likewise, screening for HS should be part of standard care for patients with common comorbidities such as metabolic syndrome, to identify those with latent and early cases of HS.

Ongoing research examining pathways of disease pathogenesis in HS is required, particularly to identify the inciting causes of HS and determine why it progresses in severity. This will enable us to optimise patient outcomes through new treatments, and allow us to identify how best to prevent the disease and disease progression. **MT**

### References

A list of references is included in the online version of this article ([www.medicinetoday.com.au](http://www.medicinetoday.com.au)).

COMPETING INTERESTS: Dr Wark has received a research grant from Sun Pharma and has undertaken paid consultancy work for AbbVie. Associate Professor Cains is a member of the AbbVie Hidradenitis Suppurativa Advisory Board.

# Hidradenitis suppurativa

## What's new in pathogenesis and management

**KIRSTY J.L. WARK** BMedSci, BMed, MMed(ClinEpi); **GEOFFREY D. CAINS** MB BS, PhD, FACD

### References

- Jemec GB. Hidradenitis suppurativa. *N Engl J Med* 2012; 366: 158-164.
- Miller IM, Ellervik C, Vinding GR, et al. Association of metabolic syndrome and hidradenitis suppurativa. *JAMA Dermatol* 2014; 150: 1273-1280.
- Chen WT, Chi CC. Association of hidradenitis suppurativa with inflammatory bowel disease: a systematic review and meta-analysis. *JAMA Dermatol* 2019; July 10. Epub ahead of print.
- Phan K, Charlton O, Smith SD. Hidradenitis suppurativa and polycystic ovarian syndrome: systematic review and meta analysis. *Australas J Dermatol* 2019; July 1. Epub ahead of print.
- Phan K, Charlton O, Smith SD. Hidradenitis suppurativa and metabolic syndrome – systematic review and adjusted meta analysis. *Int J Dermatol* 2019; 58: 1112-1117.
- Machado MO, Stergiopoulos V, Maes M, et al. Depression and anxiety in adults with hidradenitis suppurativa: a systematic review and meta-analysis. *JAMA Dermatol* 2019; June 5. Epub ahead of print.
- Esmann S, Jemec GB. Psychosocial impact of hidradenitis suppurativa: a qualitative study. *Acta Derm Venereol* 2011; 91: 328-332.
- Deckers IE, van der Zee HH, Boer J, Prens EP. Correlation of early-onset hidradenitis suppurativa with stronger genetic susceptibility and more widespread involvement. *J Am Acad Dermatol* 2015; 72: 485-488.
- Pink AE, Simpson MA, Desai N, Trembath RC, Barker JN.  $\gamma$ -Secretase mutations in hidradenitis suppurativa: new insights into disease pathogenesis. *J Invest Dermatol* 2013; 133: 601-607.
- Frew JW, Vekic DA, Woods J, Cains GD. Phenotypic heterogeneity implies heterogeneous pathogenic pathways in hidradenitis suppurativa. *Exp Dermatol* 2015; 24: 338-339.
- Frew JW. Commentary: hidradenitis suppurativa: a systematic review integrating inflammatory pathways into a cohesive pathogenic model. *Front Immunol* 2019; 10: 302.
- Frew JW, Hawkes JE, Krueger JG. Topical, systemic and biologic therapies in hidradenitis suppurativa: pathogenic insights by examining therapeutic mechanisms. *Ther Adv Chronic Dis* 2019; 10: 2040622319830646.
- Ring HC, Thorsen J, Saunte DM, et al. The follicular skin microbiome in patients with hidradenitis suppurativa and healthy controls. *JAMA Dermatol* 2017; 153: 897-905.
- Ring HC, Bay L, Kallenbach K, et al. Normal skin microbiota is altered in pre-clinical hidradenitis suppurativa. *Acta Derm Venereol* 2017; 97: 208-213.
- Ring H, Bay L, Nilsson M, et al. Bacterial biofilm in chronic lesions of hidradenitis suppurativa. *Br J Dermatol* 2017; 176: 993-1000.
- Schlapbach C, Hänni T, Yawalkar N, Hunger RE. Expression of the IL-23/Th17 pathway in lesions of hidradenitis suppurativa. *J Am Acad Dermatol* 2011; 65: 790-798.
- Zheng P, Zeng B, Zhou C, et al. Gut microbiome remodeling induces depressive-like behaviors through a pathway mediated by the host's metabolism. *Mol Psychiatry* 2016; 21: 786-796.
- Marchesi JR, Adams DH, Fava F, et al. The gut microbiota and host health: a new clinical frontier. *Gut* 2016; 65: 330-339.
- Gravina A, Federico A, Ruocco E, et al. Helicobacter pylori infection but not small intestinal bacterial overgrowth may play a pathogenic role in rosacea. *United European Gastroenterol J* 2015; 3: 17-24.
- Parekh PJ, Balart LA, Johnson DA. The influence of the gut microbiome on obesity, metabolic syndrome and gastrointestinal disease. *Clin Transl Gastroenterol* 2015; 6: e91.
- Von Laffert M, Stadie V, Ulrich J, Marsch WC, Wohlrab J. Morphology of pilonidal sinus disease: some evidence of its being a uniloculated type of hidradenitis suppurativa. *Dermatology* 2011; 223: 349-355.
- Branisteanu DE, Molodoi A, Ciobanu D, et al. The importance of histopathologic aspects in the diagnosis of dissecting cellulitis of the scalp. *Rom J Morphol Embryol* 2009; 50: 719-724.
- Frew J, Navrazhina K. Into the (gluteal) fold: pilonidal disease and hidradenitis suppurativa-association or continuum? *Br J Dermatol* 2019; 181: 1121.
- Canoui-Poitrine F, Le Thuaut A, Revuz JE, et al. Identification of three hidradenitis suppurativa phenotypes: latent class analysis of a cross-sectional study. *J Invest Dermatol* 2013; 133: 1506-1511.
- Vekic DA, Frew J, Cains GD. Hidradenitis suppurativa, a review of pathogenesis, associations and management. Part 1. *Australas J Dermatol* 2018; 59: 267-277.
- Blok J, Li K, Brodmerkel C, Horvátovich P, Jonkman M, Horváth B. Ustekinumab in hidradenitis suppurativa: clinical results and a search for potential biomarkers in serum. *Br J Dermatol* 2016; 174: 839-846.
- Tzanetakou V, Kanni T, Giatrakou S, et al. Safety and efficacy of anakinra in severe hidradenitis suppurativa: a randomized clinical trial. *JAMA Dermatol* 2016; 152: 52-59.
- Frew JW, Hawkes JE, Krueger JG. A systematic review and critical evaluation of inflammatory cytokine associations in hidradenitis suppurativa. *F1000Res* 2018; 7: 1930.
- Lee JS, Tato CM, Joyce-Shaikh B, et al. Interleukin-23-independent IL-17 production regulates intestinal epithelial permeability. *Immunity* 2015; 43: 727-738.
- Hohenberger M, Cardwell LA, Oussedik E, Feldman SR. Interleukin-17 inhibition: role in psoriasis and inflammatory bowel disease. *J Dermatolog Treat* 2018; 29: 13-18.