Managing patients with rhinosinusitis

YURESH NAIDOO BE (Hons), MB BS, FRACS, PhD

Rhinosinusitis is a common disorder that ranges from acute to chronic, with GPs at the forefront of patient management. There have been recent developments in the understanding of this heterogeneous disease, and as such it is important that GPs are aware of the latest medical and surgical treatments that have evolved in order to better inform and manage patients under their care.

Rhinosinusitis is a common presenting complaint to primary care physicians. The term 'rhinosinusitis' describes a constellation of disease entities with a common feature – inflammation of the mucosa lining the nasal cavity and the paranasal sinuses. Rhinosinusitis is best characterised as acute, subacute, recurrent acute or chronic according to the duration of symptoms (Table). Acute rhinosinusitis (ARS) is estimated to affect between 6 and 15% of the population and a recent national health survey has shown that 10% of people in Australia suffer from chronic rhinosinusitis (CRS).[1]

Acute rhinosinusitis

ARS is a common disorder that is frequently caused by an acute viral infection associated with the common cold, but bacteria have also been implicated primarily, or as a result of secondary infection after a viral upper respiratory tract infection (Figure 1). The principal bacterial pathogens involved in ARS are *Streptococcus pneumoniae, Haemophilus influenzae, Moraxella catarrhalis* and *Streptococcus pyogenes*.[2] Key diagnostic criteria include symptoms after upper respiratory tract infection, purulent nasal discharge, unilateral maxillary sinus tenderness, maxillary tooth or facial pain and a history of initial improvement followed by a worsening of symptoms.[3] Other nonspecific symptoms include malaise, halitosis, nasal congestion, hyposmia/anosmia, fever and cough. Allergic inflammation and cigarette smoking are thought to predispose patients to ARS due to decreased ciliary motility and function.

Management of acute rhinosinusitis

Meta-analyses have shown that ARS resolves without antibiotic treatment in many patients.[4] Symptomatic treatment and reassurance is the preferred initial management strategy for patients with mild symptoms as most of these are viral in origin. Antibiotic therapy should be reserved for patients with severe ARS, especially with the presence of high fever or severe unilateral facial pain (Flowchart 1).[5] Medical practitioners need to weigh the moderate benefits of antibiotic treatment against the potential for adverse effects. For initial treatment, the most narrow-spectrum agent active against the likely pathogens (*S. pneumoniae* and *H. influenzae*) should be used. Amoxicillin is usually an excellent first-line therapeutic choice, with a beneficial effect seen in up to 90% of cases; amoxicillin/clavulanic acid has greater efficacy against beta-lactamase-producing *H. influenzae*, and can be used when amoxicillin fails. Treatment should be given for five days only as meta-analyses have shown no benefit from more prolonged therapy.

Intranasal corticosteroids are effective and can be used together with oral antibiotics. Oral corticosteroids are indicated for short-term relief of headache, facial pain and other acute symptoms. Surgery is reserved exclusively for complications of ARS such as orbital or intracranial spread.

MedicineToday 2020; 21(5): 42-46

Associate Professor Naidoo is Head of the Department of Otolaryngology Head and Neck Surgery at North Shore Private Hospital, Sydney; Supervisor of Training at Concord Hospital, Sydney; NSW State Chair of the Australian Society of Otolaryngology Head and Neck Surgery; and Clinical Associate Professor at Macquarie University, Sydney, NSW.

TABLE. CLASSIFICATION OF RHINOSINUSITIS

Classification	Duration of symptoms
Acute rhinosinusitis	Up to four weeks
Subacute rhinosinusitis	Between four and 12 weeks
Recurrent acute rhinosinusitis	Four or more episodes per year with complete resolution between episodes. Each episode lasts at least seven days
Chronic rhinosinusitis	12 weeks or longer

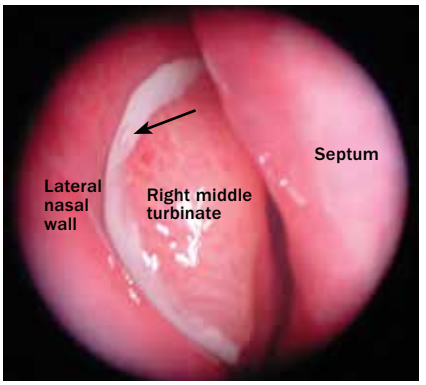

Figure 1. Nasendoscope photograph of acute rhinosinusitis with mucopurulent discharge in the right middle meatus (arrow).

Chronic rhinosinusitis

Although many of the symptoms are similar, understanding the distinction between the acute and chronic forms of rhinosinusitis has both clinical and scientific importance. In chronic rhinosinusitis (CRS) (Figure 2) the duration of symptoms is greater than 12 weeks, and although disease fluctuations occur, the signs and symptoms of CRS never completely resolve, setting CRS apart from ARS, subacute rhinosinusitis and recurrent ARS. Patients complain that it seems like they have a constant cold that never completely gets better despite multiple attempts at medical therapy. The criteria for the diagnosis of CRS are summarised in Box 1.[5]

CRS has significant socioeconomic implications, with an estimated annual direct health care cost in the US of $US 5.8 billion. Patients with CRS visit primary care clinicians twice as often as those without

1. MANAGEMENT OF ACUTE RHINOSINUSITIS*

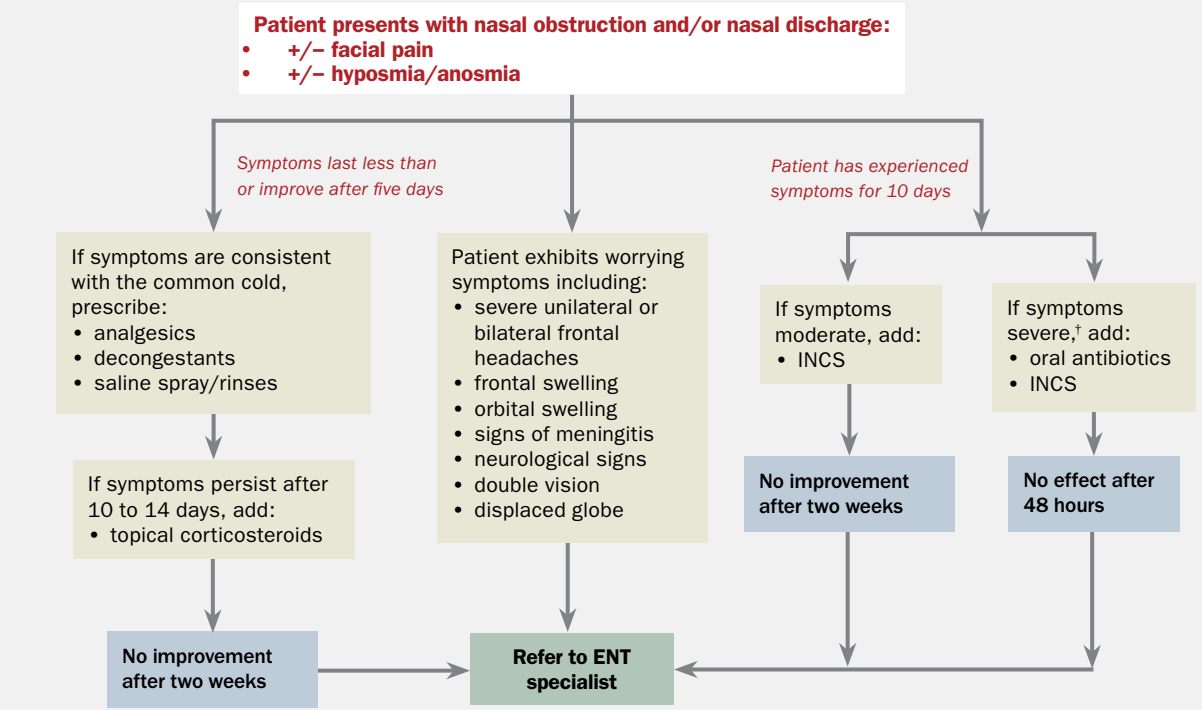

Abbreviation: INCS = intranasal corticosteroids.

* Adapted from Fokkens WJ, Lund VJ, Mullol J, et al. EPOS 2012: European position paper on rhinosinusitis and nasal polyps 2012. A summary for otorhinolaryngologists. Rhinology 2012; 50: 1-12.[5]

† Severe symptoms include pain, fever, elevated C-reactive protein and/or white cell count on blood test.

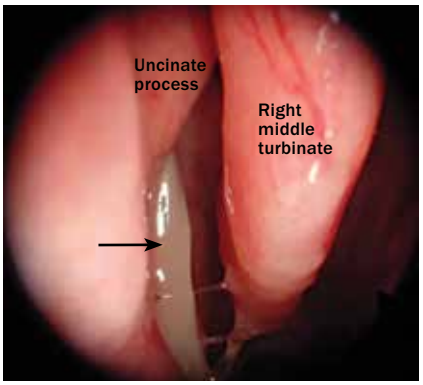

Figure 2. Nasendoscope photograph of chronic rhinosinusitis with mucopurulent discharge leaving the maxillary sinus and entering the middle meatus (arrow).

the disorder, and have five times as many prescriptions filled.[6] CRS is the second most prevalent chronic health condition in the US.[7-9] Although there are no directly comparable statistics for the Australian population, a recent study suggests that the productivity costs of CRS in the Australian context are higher than for common chronic conditions such as diabetes, chronic pain and migraine, and severe asthma, and represent a significant economic burden, estimated at almost $11,000 per patient per year.[10] CRS is also extremely detrimental to the quality of life of those who have it, with quality of life measures similar to or worse than those for chronic obstructive pulmonary disease (COPD), chronic back pain and congestive cardiac failure.[11]

1. EUROPEAN POSITION PAPER ON RHINOSINUSITIS AND NASAL POLYPS 2012 CRITERIA FOR THE DIAGNOSIS OF CHRONIC RHINOSINUSITIS[5]

Symptoms

Patient must have two or more of the following symptoms for longer than 12 weeks:

- nasal blockage/obstruction/congestion*
- nasal discharge (anterior/posterior nasal drip)*
- facial pain/pressure
- reduction or loss of smell

Special assessment

- Endoscopic assessment
- Nasal polyposis†
- CT scan of sinuses†
- Allergy testing if history suggestive

* Must include at least one of these symptoms.
† Must include at least one endoscopic or radiological finding.

Management of chronic rhinosinusitis

Treatment of CRS is medical in the first instance, as outlined in Flowchart 2. Empirical antibiotics, systemic and intranasal topical corticosteroids and saline douches are used as the first-line treatment and about 30% of patients respond to this treatment alone. There is no agreed upon antibiotic regime for patients with CRS. In a multicentre randomised trial, amoxicillin/clavulanic acid (875 mg/125 mg twice daily) was shown to have a higher clinical response rate (95% *vs* 88%) and a lower relapse rate (0% *vs* 8%) than cefuroxime axetil (500 mg twice daily).[12] In a double-blind study, ciprofloxacin and amoxicillin/clavulanic acid were shown to have similar clinical cure (60%) and bacterial eradication rates (90%).[13] However, ciprofloxacin had a much higher cure rate at 40 days after treatment and with fewer gastrointestinal complaints. The author recommends low-dose doxycycline (100 mg daily) for 21 days. Doxycycline is a tetracycline antibiotic and confers immunomodulation at subantimicrobial doses. Doxycycline has been shown to reduce postnasal drip and the size of nasal polyps – an effect that is sustained for up to 12 weeks after treatment.[14]

Intranasal corticosteroids (INCS) and saline irrigations have been shown in multiple studies to improve symptoms and outcomes in patients with and without underlying allergic rhinitis. INCS should

2. MANAGEMENT OF CHRONIC RHINOSINUSITIS*

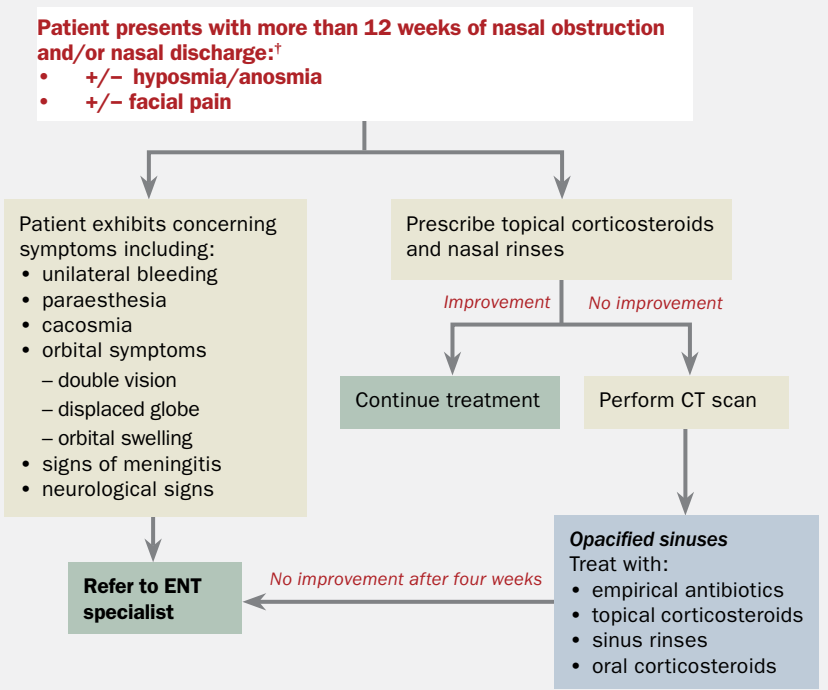

Abbreviation: CRS = chronic rhinosinusitis.
* Adapted from Fokkens WJ, Lund VJ, Mullol J, et al. EPOS 2012: European position paper on rhinosinusitis and nasal polyps 2012. A summary for otorhinolaryngologists. Rhinology 2012; 50: 1-12.[5]
† Patient must have at least one of these symptoms.

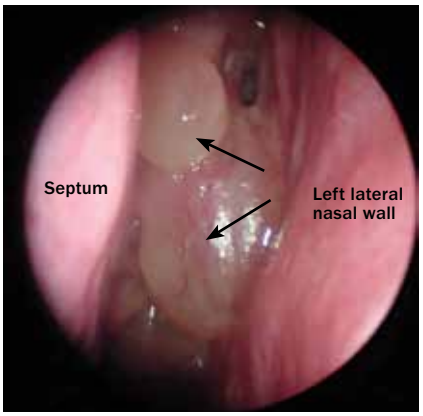

Figure 3. Nasendoscope photograph of chronic rhinosinusitis with polyps. Polyps can be observed filling the left middle meatus (arrows).

be continued after cessation of symptoms in patients with underlying allergic rhinitis to reduce the risk of further exacerbations. Immunotherapy might also be of long-term benefit in this group of patients.

In patients with CRS with polyps (Figure 3), systemic corticosteroids are beneficial but the effect is often short lived and therefore their use must be weighed against the potential for long-term side effects. In CRS without polyps, there is some evidence to support use of long-term, low-dose macrolide antibiotics for 12 weeks. Patients with a normal serum IgE levels are most responsive to this treatment.[5,15]

Role of surgery

Until recently, CRS has been attributed almost entirely to lack of ventilation (Figure 4), with endoscopic sinus surgery (ESS) the accepted treatment of choice for CRS refractory to medical treatment. ESS has been shown to be a more effective intervention at improving overall quality of life at a lower overall cost compared with continued medical therapy for patients with refractory CRS.[16,17] However, a small but nonetheless significant number of patients fail to see improvements in symptoms despite adequate 'ventilation' surgery and often undergo multiple surgeries without durable results.

We now know that CRS is a heterogeneous disease and multiple factors contribute to inflammation of the sinuses (Box 2). The role of sinus surgery has therefore evolved to acknowledge that inflammation and mucostasis are the major pathophysiological processes involved in CRS. Surgery is merely a tool to intervene in this process. The goals of ESS are to reventilate the sinuses, remove inflammatory mediators and facilitate topical therapy.

There are a number of factors affecting the 'inflammatory load' in the sinuses including biofilm formation, eosinophilic mucin and fungal antigens (Figure 5).[18] Leaving inflammatory mediators behind by not addressing a sinus when it is diseased exposes the patient to persistent symptoms. Surgery not only allows for intraoperative removal of this inflammatory load, it also dramatically improves penetration of topical therapy to the sinuses. Topical therapy is key to the long-term reduction of sinonasal mucosal

2. FACTORS CONTRIBUTING TO HETEROGENEITY OF CHRONIC RHINOSINUSITIS

Patient factors
- Systemic disease
  - asthma
  - Samter's triad
  - Churg-Strauss vasculitis
  - diabetes
  - cystic fibrosis
  - primary ciliary dyskinesia
- Smoking
- Allergies

Anatomical factors
- Concha bullosa
- Haller cells
- Supra agger frontal cells
- Severely deviated septum

Disease factors
- Extent of disease (number of sinuses involved and magnitude of opacification)
- Polyps *vs* nonpolyp inflammation
- Presence or absence of fungus
- Neutrophilic *vs* eosinophilic inflammation

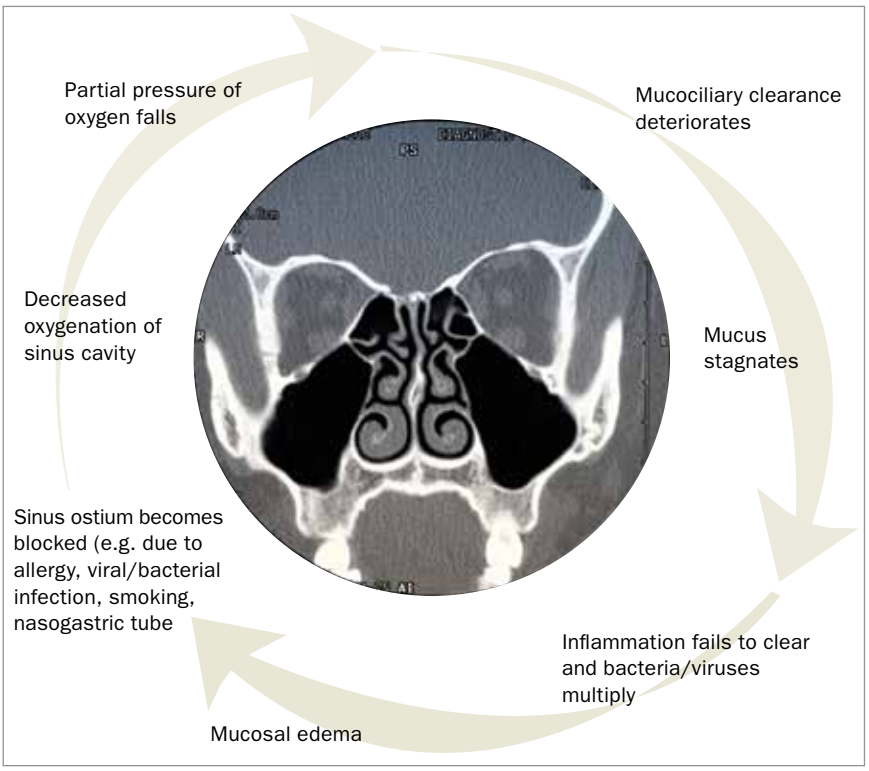

Figure 4. Original theory of chronic rhinosinusitis.

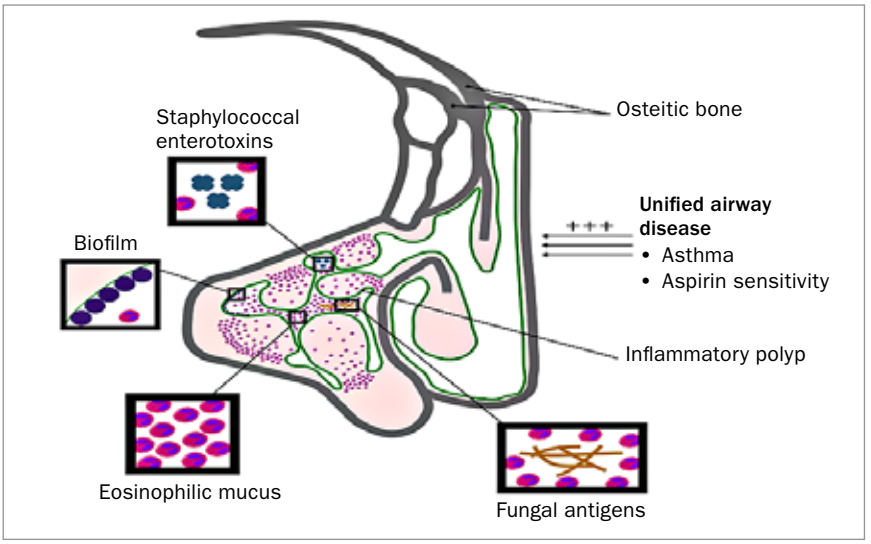

Figure 5. Factors contributing to the overall local inflammatory load in chronic rhinosinusitis.

Reproduced with permission from The American Laryngological, Rhinological, and Otological Society, Inc. Copyright © 2011. Bassiouni A, Naidoo Y, Wormald PJ. Laryngoscope 2012; 122: 460-466.[16]

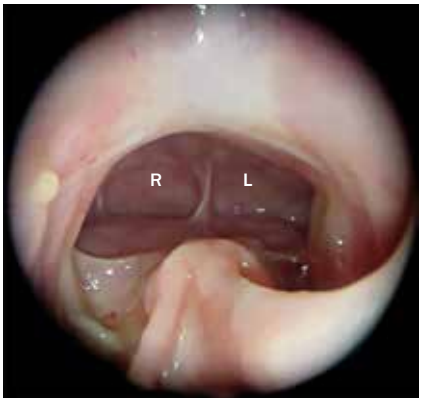

Figure 6. Nasendoscope photograph of Endoscopic Modified Lothrop's Procedure cavity. The frontal sinus opening (R = right frontal sinus; L = left frontal sinus) has been maximised. The superior part of the septum and floor of the frontal sinus have been removed to unite the left and right frontal sinuses. This allows intraoperative clearance of all protruding cells and inflammatory mediators. Postoperative debridement and topical treatment are enhanced.

inflammation, improvement in mucociliary clearance and reduction in mucostasis.

A number of new techniques have been devised to achieve total clearance of all inflammatory mediators. In particular, the Endoscopic Modified Lothrop's Procedure (EMLP) has been increasingly used to treat the chronically diseased frontal sinus. The EMLP unites the left and right frontal sinus through a common opening by removing the floor of the frontal sinus and superior part of the nasal septum (Figure 6).[19,20] Its success in treating recalcitrant disease is thought to be through facilitating complete removal of inflammatory mediators within the frontal sinus intraoperatively and allowing topical treatment postoperatively.

RHINOSINUSITIS AND COVID-19

Although there is no evidence that an otherwise healthy patient (without any underlying comorbidities) presenting with symptoms of acute rhinosinusitis (ARS) or chronic rhinosinusitis (CRS) is at increased risk of acquiring COVID-19 or having a worse outcome should they acquire it, GPs should be aware that CRS, allergic rhinitis and asthma often coexist. Patients with CRS who have an underlying respiratory condition such as asthma are at increased risk of poorer outcomes if they acquire the virus.

Also, acute loss of smell and taste are now known to be one of the presenting complaints of patients with COVID-19 and this symptom is also often seen in patients with both ARS and CRS.

If a patient presents with acute hyposmia and anosmia, they should be tested for COVID-19 and presumed to be COVID-positive with strict isolation until definitive swab results are obtained.

New treatment modalities

Eosinophilic lower airways disease (i.e. eosinophilic asthma) often coexists in patients with CRS. Indeed, the chronic sinus disease they suffer from can be considered a form of 'asthma of the nose'. Often, they struggle with both upper and lower airways inflammation, despite adequate surgery, long-term topical corticosteroid therapy and immunotherapy.

Dupilumab is a monoclonal antibody that inhibits signalling of interleukin (IL)-4 and IL-13, key drivers of type 2 inflammation, and has been approved for use in atopic dermatitis and asthma. In a recent randomised double-blind placebo-controlled trial, dupilumab was shown to reduce polyp size, sinus opacification and severity of symptoms, and was well tolerated.[21] These results support the use of dupilumab for patients with severe CRS with polyps who might otherwise have few therapeutic options.

Conclusion

Rhinosinusitis is a common disorder with a significant impact on health and quality of life. The diagnosis is made using a combination of symptoms, signs and radiological findings. Medical treatment alone is often sufficient to resolve symptoms. Surgical treatment is reserved for cases that fail medical treatment or with acute complications. ESS has evolved dramatically over the past five years, with a focus now on extensive surgery to completely clear the disease burden and facilitate long term topical treatment. Immunotherapy and new monoclonal antibody therapeutic agents are increasingly being used for patients with recalcitrant disease. MT

References

A list of references is included in the online version of this article (www.medicinetoday.com.au).

COMPETING INTERESTS: None.

Managing patients with rhinosinusitis

YURESH NAIDOO BE (Hons), MB BS, FRACS, PhD

References

1. Australian Bureau of Statistics (ABS). 4364.0.55.001 - National Health Survey: first results, 2017-18. ABS, 2018. Available online at: https://www.abs.gov.au/ausstats/abs@.nsf/mf/4364.0.55.001 (accessed April 2020).
2. Fokkens W, Lund V, Mullol J; European Position Paper on Rhinosinusitis and Nasal Polyps group. European position paper on rhinosinusitis and nasal polyps 2007. Rhinol Suppl 2007; 20: 1-136.
3. Meltzer EO, Hamilos DL. Rhinosinusitis diagnosis and management for the clinician: a synopsis of recent consensus guidelines. Mayo Clin Proc 2011; 86: 427-443.
4. Young J, De Sutter A, Merenstein Det, al. Antibiotics for adults with clinically diagnosed acute rhinosinusitis: a meta-analysis of individual patient data. Lancet 2008; 371: 908-914.
5. Fokkens WJ, Lund VJ, Mullol J, et al. EPOS 2012: European position paper on rhinosinusitis and nasal polyps 2012. A summary for otorhinolaryngologists. Rhinology 2012; 50: 1-12.
6. Rosenfeld RM, Andes D, Bhattacharyya N, et al. Clinical practice guideline: adult sinusitis. Otolaryngol Head Neck Surg 2007; 137 (3 Suppl): S1-S31.
7. Adams PF, Hendershot GE, Marano MA; Centers for Disease Control and Prevention/National Center for Health Statistics. Current estimates from the National Health Interview Survey, 1996. Vital Health Stat 10 1999; (200): 1-203.
8. Anand VK. Epidemiology and economic impact of rhinosinusitis. Ann Otol Rhinol Laryngol Suppl 2004; 193: 3-5.
9. Pleis JR, Lucas JW, Ward BW. Summary health statistics for U.S. adults: National Health Interview Survey, 2008. Vital Health Stat 10 2009; 242: 1-157.
10. Liu T, Cooper T, Earnshaw J, Cervin A. Disease burden and productivity cost of chronic rhinosinusitis patients referred to a tertiary centre in Australia. Aust J Otolaryngol 2018; 1: 5. doi: 10.21037/ajo.2018.01.03.
11. Metson RB, Gliklich RE. Clinical outcomes in patients with chronic sinusitis. Laryngoscope 2000; 110(Suppl): S24-S28.
12. Namyslowski G, Misiolek M, Czecior E, et al. Comparison of the efficacy and tolerability of amoxycillin/clavulanic acid 875 mg b.i.d. with cefuroxime 500 mg b.i.d. in the treatment of chronic and acute exacerbation of chronic sinusitis in adults. J Chemother 2002; 14: 508-517.
13. Legent F, Bordure P, Beauvillain C, Berche P. A double-blind comparison of ciprofloxacin and amoxycillin/clavulanic acid in the treatment of chronic sinusitis. Chemotherapy 1994; 40(Suppl 1): S8-S15.
14. Van Zele T, Gevaert P, Holtappels G, et al. Oral steroids and doxycycline: two different approaches to treat nasal polyps. J Allergy Clin Immunol 2010; 125: 1069-1076.
15. Haruna S, Shimada C, Ozawa M, Fukami S, Moriyama H. A study of poor responders for long-term, low-dose macrolide administration for chronic sinusitis. Rhinology 2009; 47: 66-71.
16. Smith KA, Rudmik L. Impact of continued medical therapy in patients with refractory chronic rhinosinusitis. Int Forum Allergy Rhinol 2014; 4: 34-38.
17. Rudmik L, Soler ZM, Mace JC, Schlosser RJ, Smith TL. Economic evaluation of endoscopic sinus surgery versus continued medical therapy for refractory chronic rhinosinusitis. Laryngoscope 2015; 125: 25-32.
18. Bassiouni A, Naidoo Y, Wormald PJ. When FESS fails: the inflammatory load hypothesis in refractory chronic rhinosinusitis. Laryngoscope 2012; 122: 460-466.
19. Naidoo Y, Wen D, Bassiouni A, Keen M, Wormald PJ. Long-term results after primary frontal sinus surgery. Int Forum Allergy Rhinol 2012; 2: 185-190.
20. Naidoo Y, Bassiouni A, Keen M, Wormald PJ. Risk factors and outcomes for primary, revision, and modified Lothrop (Draf III) frontal sinus surgery. Int Forum Allergy Rhinol 2013; 3: 412-417.
21. Bachert C, Han JK, Desrosiers M, et al. Efficacy and safety of dupilumab in patients with severe chronic rhinosinusitis with nasal polyps (LIBERTY NP SINUS-24 and LIBERTY NP SINUS-52): results from two multicentre, randomised, double-blind, placebo-controlled, parallel-group phase 3 trials. Lancet 2019; 394: 1638-1650.