

Three tools for managing vertigo in the frontline

VINCENT A. VAN VUGT MD

ALLISON S. YOUNG MAud

ANDREW P. BRADSHAW PhD

BENJAMIN NHAM MB BS(Hons), FRACP

MARGOT WOODS BMed, FRACGP

MIRIAM S. WELGAMPOLA FRACP, PhD

Vertigo is a challenging symptom in general practice. With access to three tools – a focused history, eye examination and a management algorithm – a large proportion of vertiginous patients could be managed effectively by GPs. This practical guide seeks to increase the skills and confidence of frontline practitioners when managing vertigo.

KEY POINTS

- A structured history (Tool 1) enables identification of the vestibular syndrome underlying vertigo symptoms. Vertigo can be subdivided into acute, episodic and chronic vestibular syndromes.
- An eye examination (Tool 2) identifies the aetiology of the syndrome. For example, is the episodic vestibular syndrome due to benign positional vertigo?
- A management plan (Tool 3) guides the practitioner in offering a treatment specific to the diagnosis.
- Acute vestibular syndromes are best assessed by a specialist.
- The most common episodic vestibular syndrome, benign paroxysmal positional vertigo, can easily be diagnosed and treated in general practice.
- The preferred treatment for chronic vestibular syndrome is vestibular rehabilitation.



Vertigo is a common condition. It has a one-year prevalence of 5%, and prevalence is higher in older age groups.¹ Although rarely lethal, its disease burden is large owing to restrictions in daily activities and a lower quality of life, heavy utilisation of healthcare resources and occupational disability among people with vertigo.²⁻⁵

The GP may be the first and only doctor to assess vertigo in a patient. GPs manage over 80% of vertigo patients without referral to specialist care.^{6,7} Not all GPs feel confident to manage vertigo, and readily available vestibular treatments are underutilised.^{8,9} The fear of missing a life-threatening stroke or fear of performing an examination or intervention that might unleash projectile vomiting is daunting for many able practitioners. Also, nystagmus

MedicineToday 2020; 21(6): 34-45

Dr van Vugt is a General Practice Registrar and Researcher at Amsterdam UMC, Amsterdam, The Netherlands.

Ms Young is an Audiologist and a Doctoral Fellow at Royal Prince Alfred Hospital and The University of Sydney Central Clinical School, Sydney.

Dr Bradshaw is a Postdoctoral Researcher at Royal Prince Alfred Hospital and The University of Sydney, Sydney.

Dr Nham is a Neurologist at Royal Prince Alfred Hospital, Sydney; and a Doctoral Researcher at The University of Sydney, Sydney.

Dr Woods is a General Practitioner at Rozelle Total Health, Sydney; a Researcher at the University of Notre Dame, Sydney; and a Board Member of the Central Sydney GP Network.

Associate Professor Welgampola is a Staff Neurologist at Royal Prince Alfred Hospital, Sydney; and a researcher at the Institute of Clinical Neurosciences, The University of Sydney, Sydney, NSW.



(the repetitive eye movement that accompanies vertigo) is shrouded in mystery and considered difficult to interpret by many doctors. Consequently, management is sometimes restricted to offering a vestibular suppressant and organising a scan to exclude stroke.

We, the authors, believe vertigo should be viewed differently and that it is worthwhile for GPs to master its management. Vertigo can be considered an exciting challenge in general practice. Often, vertigo has a benign cause; and, with three simple tools (a history, an eye examination and a management plan), many types of vertigo could be both diagnosed and treated by a trained GP. A GP can 'fix' most patients with benign paroxysmal positional vertigo (BPV) within 15 minutes and consequently make a great difference to many patients.

Vertigo can be caused by various disorders of the inner ear and brain. A focused history helps to identify the vertigo syndrome by determining the timing and triggers of the patient's vertigo symptoms and whether they fit the criteria for an acute, episodic or chronic vestibular syndrome (Tool 1). The characteristics of each vestibular syndrome are described below. Once the vestibular syndrome has been identified, the examination is used

TABLE 1. THE DIZZY HISTORY

Questions to ask the patient	Rationale
What were you doing when the vertigo started?	Vertigo on waking, turning in bed or sudden movement, or vertigo after a visit to the hairdresser or dentist is highly likely to be BPV. Vertigo while sitting still is spontaneous vertigo. Situational vertigo (in the supermarket, crowded places, during public speaking) implies anxiety
Was this the first episode? If not, how many episodes have you had so far?	A first episode of spontaneous vertigo merits consideration of an ischaemic cause. Multiple episodes imply a harmless cause
How long did the vertigo last? (e.g. seconds, minutes, hours or days?)	BPV lasts seconds. Vertigo in MD lasts 20 mins to hours; in VN and stroke >24 hours; in VM minutes to days
When did the vertigo start? (e.g. days, months or years ago?)	Consider ischaemia in vertigo of recent onset, especially if rapidly increasing in severity or frequency (crescendo vertigo)
How would you describe the sensation of vertigo? (e.g. spinning, swaying, tilting, lightheadedness or brain fog?)	Swaying, tilting and lightheadedness are more common in VM and nonvestibular vertigo
Does the vertigo occur while you are sitting still or is it related to the position you are in or how you move?	VM, MD, PCS, VN cause spontaneous vertigo. Positional vertigo is mostly BPV but could also represent VM
Have you noticed symptoms related to your hearing or ears? (e.g. hearing loss, tinnitus, full ear?)	In AVS, aural symptoms could mean labyrinthine stroke. In recurrent spontaneous vertigo, aural symptoms indicate MD
Do you have migraine symptoms (headache, motion sensitivity, photo or phonophobia, visual aura) or a family history of headaches or visual vertigo?	Consider vestibular migraine
Have you had any face, arm or leg weakness or numbness, double vision, slurred speech, difficulty swallowing, visual blurring or hiccups?	If neurological symptoms are noted, consider stroke, demyelination or other central causes
Have you ever been diagnosed with hypertension, type 1 or type 2 diabetes, hyperlipidaemia or atrial fibrillation, or is there a family history of these? Have you ever been a smoker?	If multiple vascular risk factors, consider lowering the threshold for MRI

Abbreviations: AVS = acute vestibular syndrome; BPV = benign positional vertigo; MD = Menière disease; PCS = posterior circulation stroke; VM = vestibular migraine; VN = vestibular neuritis.

to diagnose the underlying vestibular disorder (Tool 2). When the best-fit diagnosis or diagnoses have been reached, the management algorithm can be used to investigate further and guide treatment (Tool 3).

Tool 1. The dizzy history

History taking is without doubt the most important step in assessing a patient with vertigo. Table 1 outlines the questions that are worth posing to every patient and why they are important, and it could be used

Type	Differential diagnosis
Acute vertigo	
Acute vestibular syndrome	<ul style="list-style-type: none"> • Vestibular neuritis • Stroke • Vestibular migraine
Episodic vestibular syndrome	<ul style="list-style-type: none"> • Vestibular migraine • Menière's disease • Benign positional vertigo
Chronic vertigo	
Chronic vestibular syndrome	<ul style="list-style-type: none"> • Uncompensated bi/unilateral vestibular loss • Contribution from iatrogenic, skeletal, systemic, psychological factors • Other vestibular disorder (vestibular migraine, Menière's disease, benign paroxysmal positional vertigo) leading to anxiety and immobility

Assessment components	Observation or result
General assessment	
Pulse rate and rhythm	
Postural blood pressure	Lying/Standing
Eye examination	
Primary position nystagmus	Left/Right/Up/Down/Torsion
Gaze-evoked nystagmus at 15° gaze	Unidirectional/Bidirectional
Dix-Hallpike test	Paroxysmal/Persistent
HINTS assessment (only in acute vestibular syndrome): Head impulse (Left/Right/Both) Nystagmus (Peripheral/Central) Test of Skew (Negative/Positive)	Peripheral/Central
Neurological assessment	
Head tilt	Yes/No
Horner's syndrome	Yes/No
Facial droop	Yes/No
Upper limb drift	None/Left/Right
Upper limb ataxia (finger to nose)	None/Left/Right/Both
Gait	Normal/Ataxic
Lower limb weakness	None/Left/Right
Gait ataxia (tandem gait)	Left/Right/Both
Reflexes	Normal/Hyperreflexia

as a template for history taking. The history shows whether the patient has an acute, episodic or chronic vestibular syndrome, each of which has a short list of differential diagnoses (Table 2). Sometimes the history will establish the diagnosis before the examination.

Acute vestibular syndrome history

In an acute vestibular syndrome (AVS) there is acute-onset, continuous vertigo, lasting days to one week. The vertigo is persistent for a day or more, which differentiates it from an episodic vestibular syndrome. The symptoms may be exacerbated by moving the head, but movements do not actually trigger the vertigo. This distinction will need to be carefully elicited in the history.

AVS could represent vestibular neuritis or stroke. Vestibular neuritis (VN) is thought to be a viral or postviral inflammatory disorder affecting the vestibular end organs or vestibular portion of the eighth cranial nerve. In strokes that cause AVS there is generally vertebrobasilar ischaemia of the brainstem or cerebellum. Both stroke and VN can present with isolated vertigo, and therefore the history may not help separate them. Sometimes, stroke may be accompanied by new neurological symptoms such as headache, dysarthria, dysphonia, diplopia, face or limb weakness, ataxia or sensory disturbance. Sometimes VN may have a viral prodrome. Sudden hearing loss and tinnitus are not encountered in VN and are red flags for a labyrinthine stroke. Patients with an acute vestibular syndrome should be referred to the emergency department (ED).

Episodic vestibular syndrome

An episodic vestibular syndrome is characterised by recurrent vertigo attacks, lasting seconds to hours or, rarely, days. In between attacks patients are asymptomatic. Recurrent vertigo could be caused by changes of the head position (recurrent positional vertigo) or it could be vertigo that occurs without an obvious positional trigger (recurrent spontaneous vertigo).

1. HINTS EXAMINATION FOR ACUTE VESTIBULAR SYNDROME

The HINTS examination consists of three components: head impulse, nystagmus, and test of skew. The test is helpful to differentiate between vestibular neuritis and stroke in acute vestibular syndrome when performed by a trained practitioner.

Head impulse

- Grasp the patient's head firmly with your hands. Ask the patient to fix their gaze on your nose. Deliver a rapid 10° horizontal rotation to each side while watching their eyes. Ensure the amplitude of neck rotation is small (only 10°) but quick
- When the vestibulo-ocular reflex (VOR) is intact, the eyes remain on target and the head impulse is negative or normal
- When the VOR is deficient, the eyes move with the head then rapidly flick back to the midline target. This quick refixation saccade or catch-up saccade is a positive and abnormal head impulse
- A video head impulse test can be performed by a specialist to measure and record saccades and gain (ratio between the eye and head movements)

Nystagmus

- Look for primary position spontaneous nystagmus: ask the patient to look straight ahead
- Look for gaze-evoked nystagmus: ask the patient to keep the head fixed and look 15° to the left and then 15° to the right for 15 seconds
- Typical peripheral nystagmus is horizontal, beats in the same direction with left and right gaze, enhances when looking in the direction of the fast phase and suppresses when looking in the opposite direction
- Typical central nystagmus could be vertical (upbeating or downbeating) or pure torsional. Note that positional upbeating nystagmus is seen in benign paroxysmal positional vertigo (a peripheral disorder) this must not be confused with primary position upbeating nystagmus, which is seen in central vertigo. Presence of direction-changing horizontal nystagmus implies a central abnormality (left beating on left gaze and right beating on right gaze)

Test of skew

- Look for skew deviation in the primary position (skew refers to vertical misalignment of the eyes)
- Alternately cover the eyes and look for skew deviation
- When skew deviation is present, the test of skew is positive, which makes a central cause of acute vestibular syndrome more likely

HINTS findings suggestive of vestibular neuritis are:

A positive head impulse test AND peripheral nystagmus AND a negative test of skew. All three findings must be present, to diagnose peripheral HINTS. If even one condition is not met, consider stroke.

Discover Today's **Medicine**



www.medicinetoday.com.au

MedicineToday

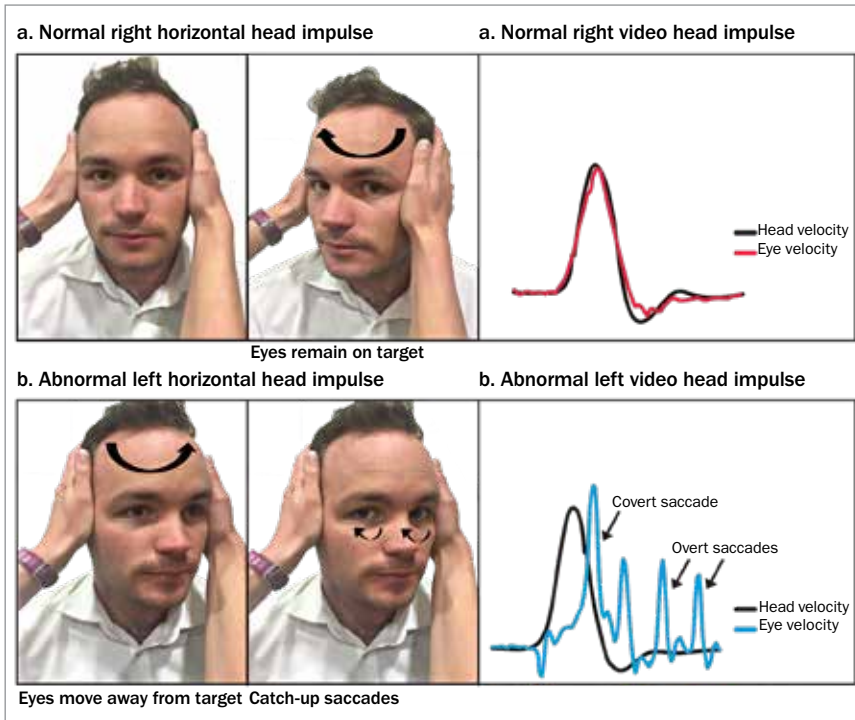


Figure 1. HINTS examination: the head impulse test in left vestibular neuritis.
 a. The right head impulse is normal: as the head is turned quickly to the right, the patient's eyes remain on the visual target. This indicates a normal vestibulo-ocular reflex (VOR), and normal function of the right lateral semicircular canal. **Note: the head movements must be of low amplitude not exceeding 10°, and of high velocity.**
 b. The left head impulse is abnormal: as the head is turned quickly to the left, the eyes initially move with the head, away from the intended visual target; they then quickly flick rightwards to refixate on the target. This hallmark refixation movement, detectable to the naked eye, is called a catch-up saccade. This indicates an abnormal VOR and reduced function of the left lateral semicircular canal, typical of vestibular neuritis.
 Abbreviations: HINTS = head impulse, nystagmus and test of skew.

Recurrent positional vertigo

Recurrent positional vertigo is almost always caused by BPV, the most frequent cause of vertigo encountered by GPs. BPV is believed to be caused by calcium carbonate particles or ‘crystals’ being dislodged from our gravity sensors, or otolith organs, into the semicircular canals where they activate vestibular afferent neurons, causing vertigo. Although all three semicircular canals can be affected, the posterior canal is the one involved in more than 90% of instances.¹⁰ Head movement (turning in bed, getting in and out of bed, reaching for a bookshelf, hanging out clothes, tying shoelaces, instilling eye drops) causes sudden spinning vertigo, lasting seconds to a minute. Vertigo after a visit to the

hairdresser or dentist is highly suspicious for BPV. As patients age, they may not provide this classic history but instead present with recurrent falls or a wobbly gait.

Recurrent positional vertigo is almost always caused by benign paroxysmal positional vertigo (BPV), the most frequent cause of vertigo encountered by GPs

Recurrent spontaneous vertigo

When vertigo is recurrent but occurs spontaneously (when sitting quietly) two diagnoses should be considered:

vestibular migraine (VM) and Menière’s disease (MD). Vestibular migraine, although relatively newly defined, is by far the more common cause of recurrent spontaneous vertigo.¹¹ It can be considered a migraine variant with vestibular symptoms, although the exact pathophysiology is still poorly understood.¹² Ideally, there would be a temporal association between vertigo and headache, photophobia or phonophobia, but this is not always clear.¹³ Sometimes the patient may have a lifelong history of motion sensitivity or a past history or family history of migraine. The vertigo attacks last minutes to hours and can be triggered by excessive stress and lack of sleep, food or fluids.

It can be difficult to distinguish vestibular migraine from MD. Thought to be caused by excessive build-up of endolymphatic fluid in the inner ears, MD is better known but far less common than VM. In MD, the spontaneous vertigo attacks also last minutes to hours, but they are more often associated with aural symptoms such as hearing loss, tinnitus or aural fullness. As MD progresses over the years, the vertigo attacks often diminish and hearing loss becomes permanent. However, the history and physical examination are not always enough to differentiate between VM and MD and referral to a specialised dizziness clinic is sometimes needed.

Chronic vestibular syndrome

Chronic vestibular syndrome is characterised by chronic persisting disequilibrium that lasts for months to years and can be caused by many conditions. Finding out when the vestibular symptoms first started is useful. Patients may have experienced an acute vestibular syndrome caused by vestibular neuritis, with incomplete recovery resulting in chronic vestibular symptoms. Episodic vestibular syndrome caused by MD or vestibular migraine may result in chronic symptoms of imbalance and ataxia in between vertigo attacks.

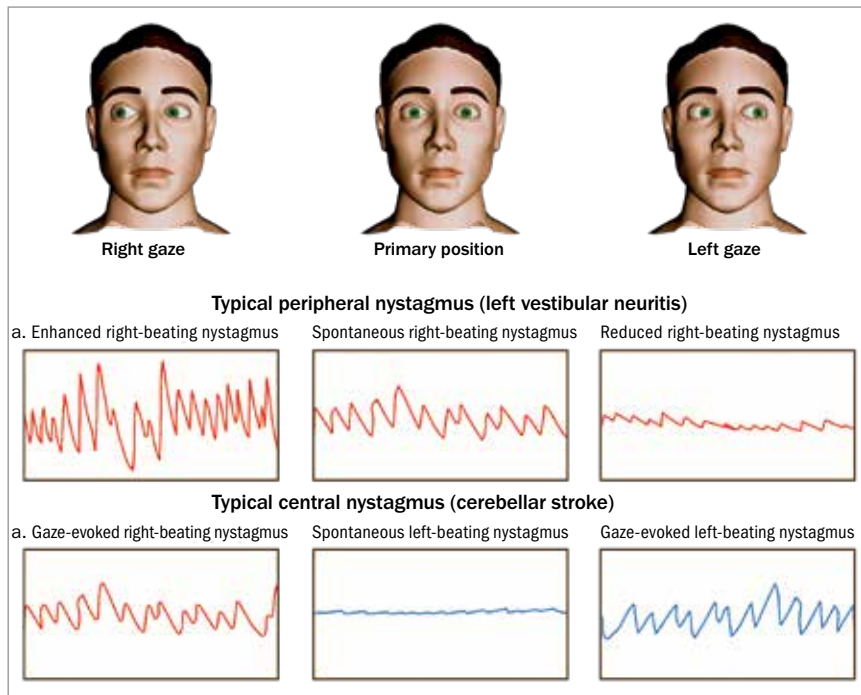


Figure 2. HINTS examination: inspection of nystagmus.
 a. In left vestibular neuritis the primary position spontaneous nystagmus is right beating, away from the affected ear (centre panel); this nystagmus will enhance when gazing towards its fast phase (left panel), and will reduce when gazing away from its fast phase (right panel). Peripheral nystagmus is unidirectional, beating in the same direction in all gaze positions.
 b. Typical cerebellar nystagmus may beat in either direction. In the primary position (centre panel), nystagmus is bidirectional. It is right beating with rightward gaze (left panel), and left beating with leftward gaze (right panel), described as gaze-evoked nystagmus.

Abbreviation: HINTS = head impulse, nystagmus and test of skew.

It may be impractical to find the cause of the chronic vestibular syndrome in general practice. Instead of solely focusing on the cause it is also important to find out what triggers unpleasant vestibular symptoms in daily life. When the vestibular system is injured, central mechanisms (vestibular compensation) are activated that eventually reduce symptoms of vertigo. If this repair mechanism fails, chronic vestibular symptoms occur. Insufficient stimulation of the vestibular system is always an important and modifiable factor in chronic vestibular syndromes. Fear of vertigo may prevent patients from moving their head or undertaking activities, but this will cause symptoms to persist in the long term. Comorbidities such as psychiatric disorders, musculoskeletal problems, sensory

impairment and long-term use of vestibular suppressants are also associated with the development of chronic vestibular syndrome. The history should be aimed at determining triggers of vertigo and reasons that prevent patients from challenging their vestibular system.

Fear of vertigo may prevent patients from moving their head or undertaking activities, but this will cause symptoms to persist in the long term

Tool 2. The dizzy examination

The physical examination consists of a general assessment, screening neurological assessments and a focused eye examination and is outlined in Table 3,

which could be used as a checklist template. Often, history and examination (Tools 1 and 2) together may suffice to diagnose your patient’s condition.

Acute vestibular syndrome

The physical examination can help to further differentiate between the two most common conditions that cause AVS: vestibular neuritis and stroke. Pulse rate and blood pressure may be increased in both vestibular neuritis and stroke, and a newly discovered irregular heart rhythm may indicate a potential embolic source for stroke. The HINTS (head impulse, nystagmus, test of skew) examination, a careful examination of eye movements, is a promising diagnostic tool for differentiating vestibular neuritis from stroke when conducted by a trained practitioner (Box 1; Figures 1, 2 and 3; Videos 1, 2a to 2d and 3 [videos are available with the online version of this article at <https://medicinetoday.com.au/vertigovideos>]).

Studies have shown that the HINTS examination can be even more sensitive than neuroimaging when conducted properly by a trained physician. It is important that GPs develop experience using the HINTS assessment. Since experience using HINTS is variable, however, we advise referral of all patients with an acute vestibular syndrome to the ED to exclude stroke.

Episodic vestibular syndrome

In patients with episodic (recurrent) vestibular syndrome, the general and screening neurological assessment may show no abnormalities. In patients with recurrent spontaneous vertigo, primary position spontaneous nystagmus may be observed if they happen to be assessed during an attack. In MD, primary position nystagmus is almost always horizontal. In VM it could be horizontal, vertical or torsional. If the attack has abated, there may be no primary position nystagmus. Many nystagmus types are suppressed by bright light and are therefore undetectable.

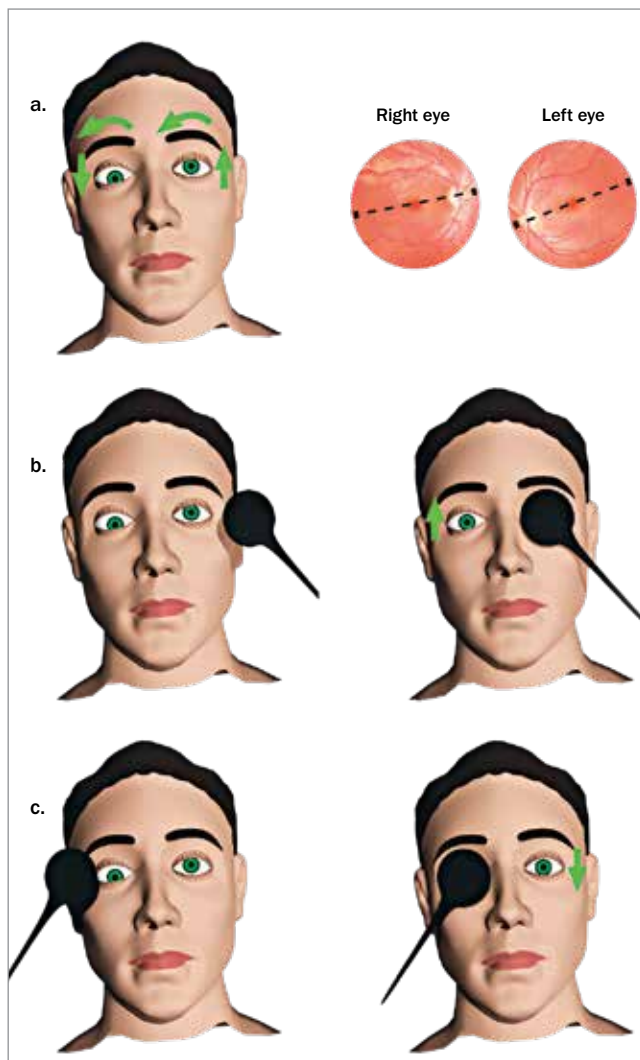


Figure 3. HINTS examination: the cover-uncover test for skew.

a. A patient with a left head tilt and left-on-right skew. The left eye is elevated and intorted. The right eye is depressed and extorted.

b. Alternate cover test: covering the left eye results in elevation of the depressed right eye ('down' eye goes up).

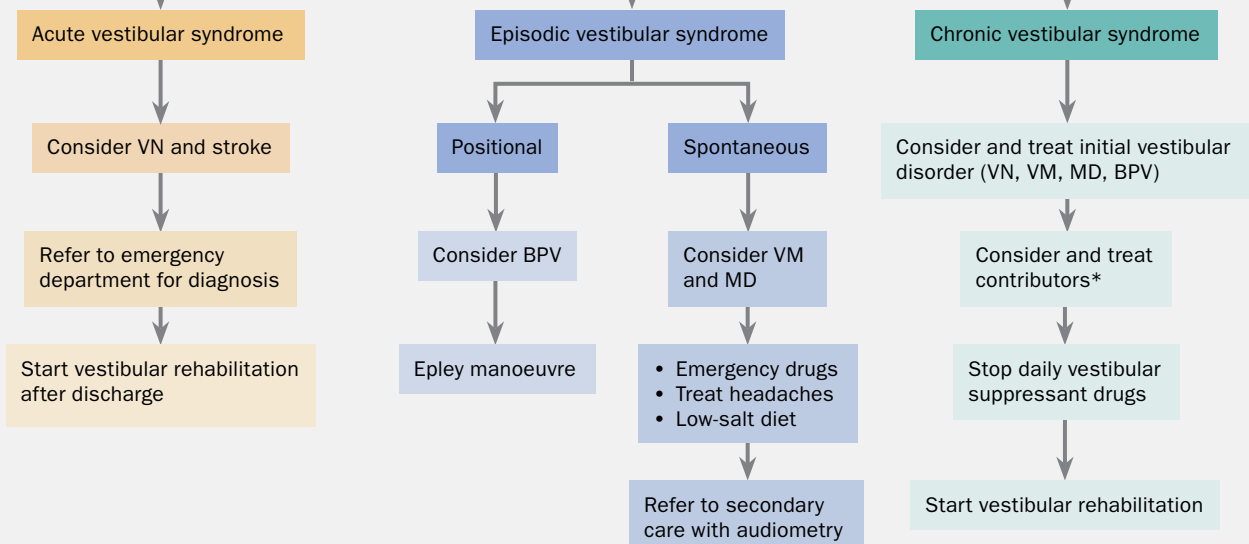
c. Alternate cover test: covering the right eye results in depression of the elevated left eye ('up' eye goes down).

Abbreviation: HINTS = head impulse, nystagmus and test of skew.

If the patient's history indicates recurrent positional vertigo, a definitive diagnosis of BPV can be made by performing the Dix-Hallpike test (Box 2; Figure 4; Videos 4a and 4b [<https://medicinetoday.com.au/vertigovideos>]). The diagnosis of posterior canal BPV is confirmed when the Dix-Hallpike test causes vertigo and, after a short latency period, torsional upbeat nystagmus is seen. We advocate performing a Dix-Hallpike test on all patients presenting with vertigo, since it offers an opportunity to detect and alleviate an easily

A SUGGESTED APPROACH TO MANAGING VERTIGO IN GENERAL PRACTICE

A patient presents with vertigo and thorough history taking identifies the vertigo syndrome



Abbreviations: BPV = benign positional vertigo; MD = Menière's disease; VM = vestibular migraine; VN = vestibular neuritis.

*i.e. anaemia, nutritional deficiencies, endocrinopathies, postural hypotension, musculoskeletal disorders, polypharmacy, anxiety, depression.

2. COMBINED DIX-HALLPIKE TEST AND EPLEY MANOEUVRE

The Dix-Hallpike test (Figure 4) is an easy test to diagnose the most common form of benign positional vertigo (BPV). If the patient primarily experiences vertigo when turning to the right or left side, we advise to start with testing that side. When the Dix-Hallpike test is positive, you can directly continue with the Epley manoeuvre (Figure 5)

Left Dix-Hallpike test

- Ask the patient to sit upright in bed with a firm pillow behind them. Inspect for primary position spontaneous nystagmus. (If the patient has nystagmus that is visible when they are sitting up and looking straight ahead, they do not have BPV)
- Turn the head 45° to the left
- Lie them down quickly with the lower back arching over the pillow and head hanging over the pillow to rest on the bed. (It is not necessary to hang the patient's head over the edge of the bed; this can be too arduous for both practitioner and patient)
- Observe for vertigo and nystagmus for at least 30 seconds
- In BPV, the nystagmus is paroxysmal, lasts less than one minute and follows the direction of the affected semicircular canal
- Posterior canal BPV will produce upbeating torsional geotropic nystagmus. If the test is positive, proceed to treatment with the left Epley manoeuvre (see instructions with Figure 5)

treatable cause of vertigo.

In patients with spontaneous vertigo of any cause (VM, MD, VN, stroke) who have spontaneous nystagmus, enhancement of this nystagmus will occur in the Hallpike position. Typical BPV is paroxysmal; the nystagmus begins and stops within the span of one minute. If the nystagmus continues for as long as the head remains in the Hallpike position, it is unlikely to be posterior canal BPV.

Chronic vestibular syndrome

In chronic vestibular syndrome the physical examination may not always identify the cause of the symptoms, but it helps determine factors that contribute to the vestibular problem. Orthostatic hypotension, a drop in systolic blood pressure of more than 20 mmHg on standing up, should be screened for in every patient. The head impulse test may reveal uni- or bilateral vestibular loss. Primary position nystagmus may be absent if the vestibular

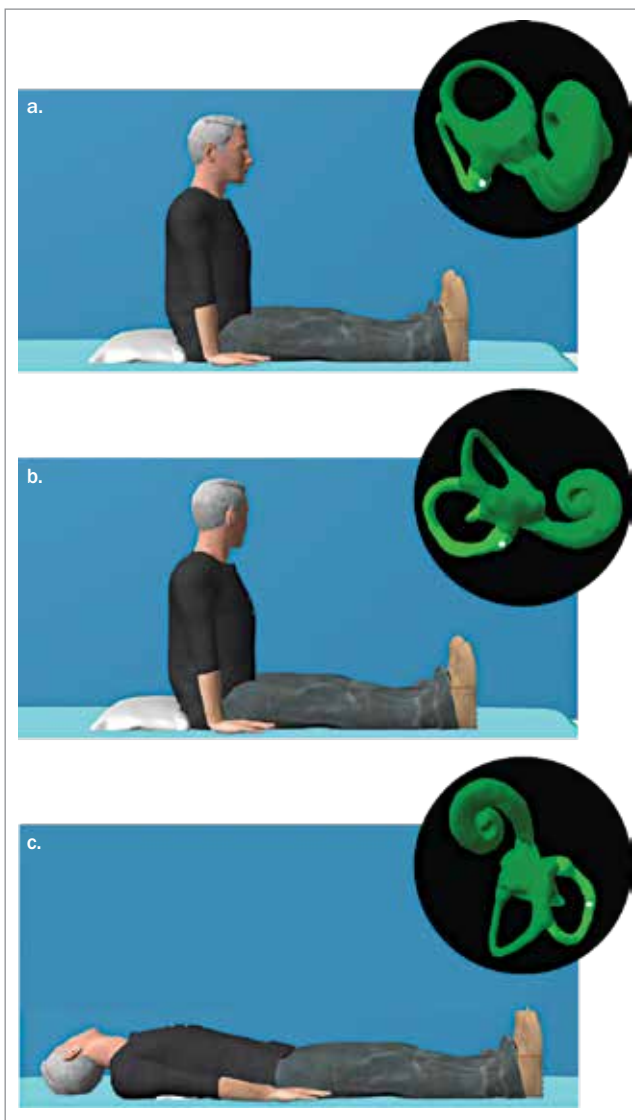


Figure 4. Left Dix-Hallpike test

- Begin by sitting the patient upright with a pillow behind the lower back.
- Turn the head 45° to the left.
- Lie the patient down quickly over the pillow with the head tilted back 30° onto the bed. Watch their eyes for nystagmus. (It is not necessary to hang the patient's head over the end of the bed.)

event occurred a long time ago. Patients with bilateral vestibular loss also have difficulty performing a matted Romberg test (standing on foam with eyes shut) or a tandem Romberg test (tandem stance with eyes shut). Gait can be wide-based, and tandem gait may be ataxic in patients with peripheral and central vestibular system dysfunction (as well as in cerebellar ataxia and severe peripheral neuropathy). We recommend assessing all patients with chronic vestibular syndrome for BPV, as older patients with untreated BPV often present with chronic imbalance.

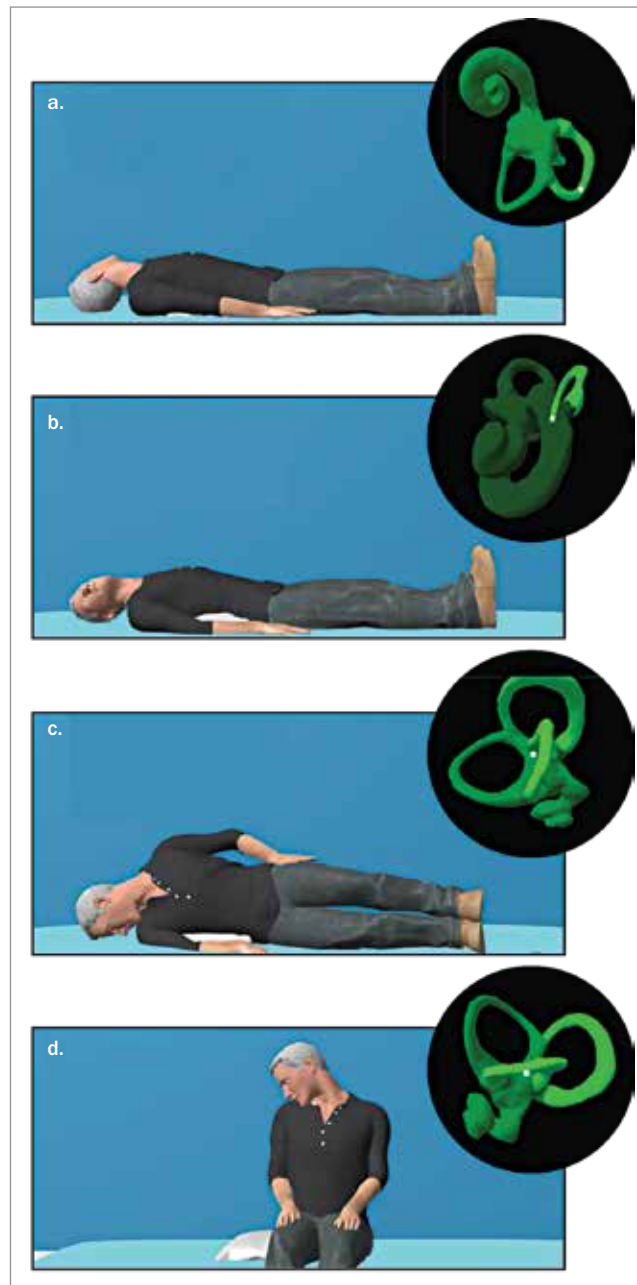


Figure 5. Left Epley manoeuvre

- If the left Dix-Hallpike test is positive, keep the patient in the left Dix-Hallpike position for two minutes.
- Without lifting the head off the bed, turn the head 90° towards the right side. The patient may feel dizzy again. Wait in this position for two minutes.
- Roll the patient onto their right side and continue to turn the head until their nose is pointing towards the floor. Wait in this position for two minutes.
- Keeping their head turned and their chin tucked down, sit the patient up slowly. Once they are sitting up, they can look straight ahead. Hold onto them, as they may be unsteady.

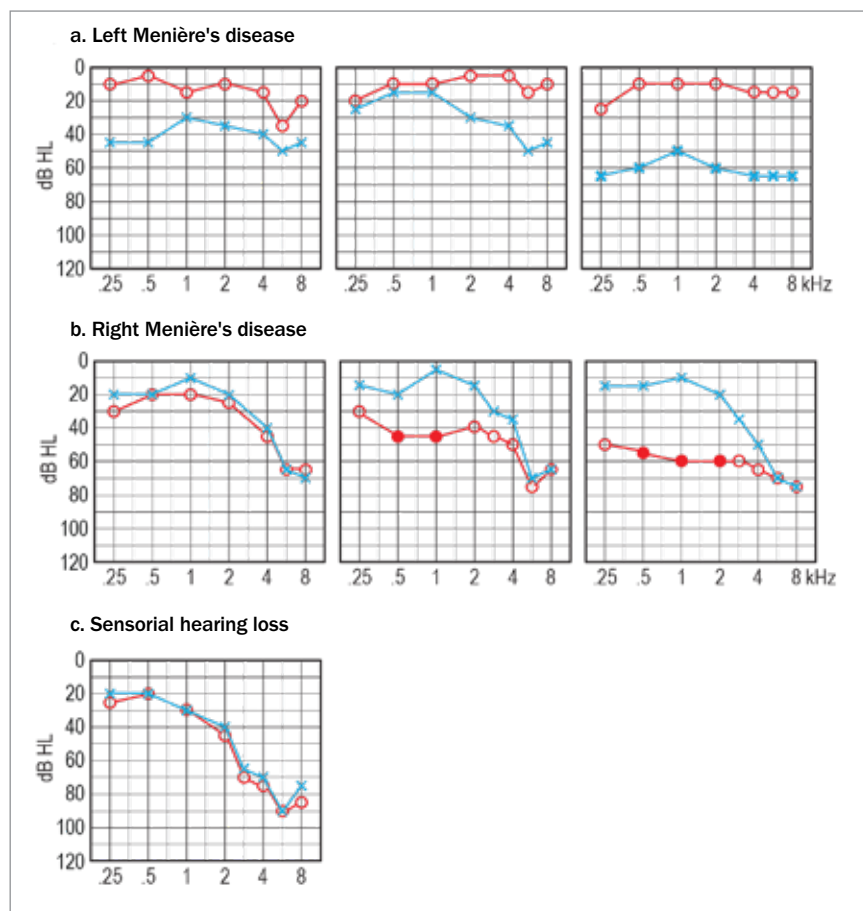


Figure 6. Audiometry in Menière's disease (MD)

a. The hearing loss of a patient with left-sided MD shows initially asymmetric hearing thresholds (left ear affected) at both high and low frequencies (left panel). The second audiogram (middle panel) shows an improvement at the low frequencies and the third (right panel), a lowering of hearing thresholds at both high and low frequencies. It is common to see the hearing thresholds improve in MD.

b. The hearing loss of a patient with right-sided MD shows initially symmetrical hearing thresholds (left panel) with a typical high-frequency hearing loss consistent with presbycusis (age-related hearing loss). Then at the onset of the disease (middle panel) the low-frequency thresholds are affected, showing fluctuating sensorineural hearing loss. As the disease progresses, the affected ear typically shows a flat sensorineural hearing loss around 60 dB (right panel).

c. The typical audiogram of an individual with symmetrical high-frequency hearing loss consistent with presbycusis (age-related hearing loss).

Tool 3. The dizzy management plan

Our management plan for patients with vertigo in primary care is presented in the Flowchart. All patients with an acute vestibular syndrome require assessment in the ED. After discharge, patients with persisting vertigo should be offered vestibular rehabilitation. In patients with episodic vestibular syndromes, positional vertigo

requires a search for and treatment of BPV.

The Epley manoeuvre is a relatively simple and proven treatment for posterior canal BPV (Box 2; Figure 5; Video 5 [<https://medicinetoday.com.au/vertigo-videos>]). It is safe, effective and within the capability of any medical practitioner, although it is currently underutilised, owing to false perceptions of complexity.^{9,14,15} We encourage widespread use of

the Epley manoeuvre as a most rewarding treatment in general practice, since many patients with BPV can be 'cured' with a single treatment performed in less than 15 minutes.¹⁴

If the patient is nauseated, they could be premedicated with prochlorperazine and ondansetron 15 minutes before carrying out the manoeuvre. If the patient is obese, consider requesting the assistance of a colleague. A patient who is unable to arch backwards due to scoliosis or a stiff neck could benefit from being treated while on a trolley that can be tilted backwards.

For patients with episodic spontaneous vertigo, diagnostic work-up can be started in general practice while awaiting review in a dizzy clinic. The audiogram is an essential test that may reveal fluctuating hearing loss diagnostic of MD (Figure 6). For patients with vestibular migraine, it is important to reassure them that, as for other forms of migraine, the condition is bothersome but not dangerous. Common migraine triggers such as excessive stress or lack of sleep, food or fluids should be avoided, and regular exercise can reduce symptoms of vertigo.¹⁶ When the vertigo attacks are frequent and disabling, prophylactic medication should be considered. Riboflavin (400 mg daily) and magnesium (300 mg equivalent Mg) could be started. In suspected MD, patients should be advised to initiate a low-salt diet. All patients with recurrent spontaneous vertigo should be provided with emergency drugs (e.g. prochlorperazine 5 mg or cinnarizine 25 mg for vestibular suppression, and ondansetron 4 to 8 mg for nausea). Patients should be instructed to carry the drugs with them and use them sparingly to alleviate vertigo, but never to use them when they are symptom-free.

Chronic vestibular syndromes require a meticulous work-up for the underlying causes (Flowchart) and initiation of self-directed or supervised balance rehabilitation. Vestibular rehabilitation is a safe and effective treatment for chronic

imbalance.¹⁷ GPs can refer patients to a specialised physiotherapist for treatment, or direct patients to a freely available online vestibular rehabilitation intervention developed by the University of Southampton (<https://balance.lifeguide-health.org>).¹⁸ If there is a significant contribution from anxiety, consider referral to a psychologist with experience in treating dizzy patients.

Referring the dizzy patient

Vertigo affects one to two million Australians each year. To optimise their management, the combined efforts of GPs, otolaryngologists, nurse-practitioners, neurologists, physiotherapists and emergency physicians are needed. We believe that vertigo should not fall exclusively in the domain of the 'neuro-otologist' and can be managed effectively by many healthcare professionals with access to the correct tools. We expect that, in the future, GPs with subspecialty expertise in vertigo will exist in Australia.

Patients with acute vestibular syndromes are best referred to the ED; yet there may be instances (e.g. regional general practice settings) where the practitioner is more skilled in vertigo assessment than the ED service. In these instances, it is best that the GP undertakes the HINTS assessment, organises urgent MRI scanning for those patients with a central cause of vertigo (since CT scanning to exclude posterior circulation stroke is not conclusive) and initiates antiplatelet therapy pending review by a neurologist. BPV can often be managed successfully by the GP without specialist referral unless it is refractory to bedside treatment. Many GPs will correctly choose to refer 'difficult' patients to an expert physiotherapist, ear, nose and throat specialist, or neurologist who is experienced in treating BPV. Patients with episodic spontaneous vertigo could start their diagnostic work-up (audiometry) and management (lifestyle changes, salt restriction, trial of magnesium or riboflavin for migraine) while

awaiting review by an otolaryngologist, neurologist or dizzy clinic. Patients with chronic vestibular syndromes may be referred to a neurologist or ear, nose and throat specialist or dizzy clinic for initial diagnostic work-up and managed by a team led by the GP with the participation of the specialist, a physiotherapist and a psychologist as required.

Conclusion

The first step when assessing patients with vertigo in general practice is to determine whether the symptom is acute, episodic or chronic. Once the syndrome is identified, the history and examination will help identify possible vestibular disorders. Using the three tools described, assessment and management of vertigo may prove easier and more rewarding for the GP. **MT**

References

1. Neuhauser HK. The epidemiology of dizziness and vertigo. *Handb Clin Neurol* 2016; 137: 67-82.
2. Neuhauser HK, Lempert T. Vertigo: epidemiologic aspects. *Semin Neurol* 2009; 29: 473-481.
3. Kovacs E, Wang X, Grill E. Economic burden of vertigo: a systematic review. *Health Econ Re*. 2019; 9: 37.
4. Saber Tehrani AS, Coughlan D, Hsieh YH, et al. Rising annual costs of dizziness presentations to U.S. emergency departments. *Acad Emerg Med* 2013; 20: 689-696.
5. Benecke H, Agus S, Kuessner D, Goodall G, Strupp M. The burden and impact of vertigo: findings from the REVERT patient registry. *Front Neurol* 2013; 4: 136.
6. Stam H, Harting T, Sluijs M, et al. Usual care and management of fall risk increasing drugs in older dizzy patients in Dutch general practice. *Scand J Prim Health Care* 2016; 34: 165-171.
7. Jayarajan V, Rajenderkumar D. A survey of dizziness management in general practice. *J Laryngol Otol* 2003; 117: 599-604.
8. Stephan AJ, Kovacs E, Phillips A, Schelling J, Ulrich SM, Grill E. Barriers and facilitators for the management of vertigo: a qualitative study with primary care providers. *Implement Sci* 2018; 13: 25.
9. van Vugt VA, Diaz Nerio PM, van der Wouden JC, van der Horst HE, Maarsingh OR. Use of canalith repositioning manoeuvres and vestibular rehabilitation: a GP survey. *Scand J Prim Health Care* 2017; 35: 19-26.
10. von Brevem M, Bertholon P, Brandt T, et al. Benign

- paroxysmal positional vertigo: diagnostic criteria consensus document of the Committee for the Classification of Vestibular Disorders of the Barany Society. *Acta Otorinolaringol Esp* 2017; 68: 349-360.
11. Formeister EJ, Rizk HG, Kohn MA, Sharon JD. The epidemiology of vestibular migraine: a population-based survey study. *Otol Neurotol* 2018; 39: 1037-1044.
 12. Huang TC, Wang SJ, Kheradmand A. Vestibular migraine: an update on current understanding and future directions. *Cephalalgia* 2020; 40: 107-121.
 13. Lempert T, Olesen J, Furman J, et al. Vestibular migraine: diagnostic criteria. *J Vestib Res* 2012; 22: 167-172.
 14. Hilton MP, Pinder DK. The Epley (canalith repositioning) manoeuvre for benign paroxysmal positional vertigo. *Cochrane Database Syst Rev* 2014; (12): CD003162.
 15. Glasziou P, Heneghan C. Epley and the slow boat from research to practice. *Evid Based Med* 2008; 13: 34-35.
 16. von Brevem M, Lempert T. Vestibular migraine: treatment and prognosis. *Semin Neurol* 2020; 40: 83-86.
 17. McDonnell MN, Hillier SL. Vestibular rehabilitation for unilateral peripheral vestibular dysfunction. *Cochrane Database Syst Rev* 2015; (1): CD005397.
 18. Geraghty AWA, Essery R, Kirby S, et al. Internet-based vestibular rehabilitation for older adults with chronic dizziness: a randomized controlled trial in primary care. *Ann Fam Med* 2017; 15: 209-216.

COMPETING INTERESTS: None.

ACKNOWLEDGEMENTS AND FUNDING: The authors thank Ms Nicole Reid, RN, and Ms Belinda Kwok for assistance with the clinical video; and Mr Paul Burston for providing the images for Figure 6. Dr van Vugt was funded by an Amsterdam Public Health Aging and Later Life travel grant (2019-092). Associate Professor Welgampola is funded by the National Health and Medical Research Council and The Garnett Passe and Rodney Williams Memorial Foundation Australia.



Studying medicine?

Or know someone who is? For our special subscription rates for medical students, contact:

Katrina on (02) 9908 8577 or email: reception@medicinetoday.com.au