

Discoid eczema

More than just dermatitis

JOSHUA FARRELL MB BS; STEPHEN SHUMACK OAM, MB BS(Hons), FACD

Discoid, or nummular, eczema is a chronic form of dermatitis characterised by well-defined circular plaques. Associations include allergic contact dermatitis, low environmental humidity and excessive alcohol intake. It is managed by avoidance of triggers and use of emollients and topical corticosteroids.

The word eczema (also called dermatitis) derives from the Greek word 'ekzema', meaning 'to boil'. It is a clinical and histological pattern of inflammation of the skin characterised by pruritus and discomfort. It can be classified in several ways, one of which is morphologically.¹ Discoid eczema, or nummular eczema, is one form of dermatitis that can be classified this way. Discoid eczema is defined by circular or oval plaques of eczema with a clearly demarcated edge.^{2,3} Many patients with eczema have at least one or two circular lesions, and few patients with discoid eczema have solely discoid lesions.⁴

Discoid eczema has an incidence of 2 per 1000 people and is particularly common in men aged 35 to 70 years.^{2,5} The exact aetiology is unknown, although a significant percentage of patients may have an underlying allergic or irritant contact dermatitis.³⁻⁷ Other associations include low environmental humidity, excessive chronic alcohol intake, staphylococcal colonisation, lifestyle factors (such as irritating soaps and fabrics and frequent exposure to hot water), trauma (the Koebner phenomenon) and certain medications including antivirals, interferon, isotretinoin, ribavirin and gold.^{2,3,5,8-10} Chronic venous stasis has also been implicated, especially when the discoid eczema involves the lower legs.³

MedicineToday 2021; 22(5): 19-22

Dr Farrell is a Research Fellow in Dermatology at Southern Suburbs Dermatology, Sydney. Associate Professor Shumack is a Clinical Associate Professor at Sydney Medical School (Northern) at The University of Sydney; Medical Director of The Skin Hospital, Sydney; Senior Staff Specialist at Royal North Shore Hospital, Sydney; and has a private practice at St George Dermatology, Sydney, NSW.



KEY POINTS

- Discoid eczema is a sub-type of nonatopic eczema defined by circular or oval plaques of eczema with a well-demarcated edge.
- It tends to follow a chronic course.
- The four clinical variants of discoid eczema are exudative nummular eczema, dry type nummular eczema, discoid eczema of the hands and exudative discoid with lichenoid chronic eczema.
- Differential diagnoses for eczema include tinea corporis, psoriasis and pityriasis rosea and are important to rule out for optimal management.
- It is managed through conservative skin care measures, as well as use of emollients and topical corticosteroids.
- Secondary infection with *Staphylococcus* species is common and requires treatment with systemic or topical antibiotics.

Presentation

The diagnostic lesion is a coin-shaped plaque of closely-set thin-walled scaling and vesicles on a scaly erythematous base, classically on the extensor surfaces of lower limbs.^{2,3,11} The lesions are sharply defined and range in size from 1 to 10cm in diameter.³ They arise rapidly from a confluence of tiny papules and papulovesicles.^{2,3} In the acute phase, these lesions are dull red, very exudative or crusted and highly pruritic.² They progress towards a less vesicular and more scaly stage, with central clearing and peripheral extension. There is sometimes a drier scale and lichenification.³ The lesions

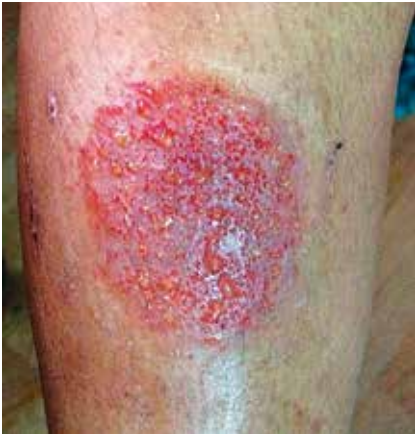

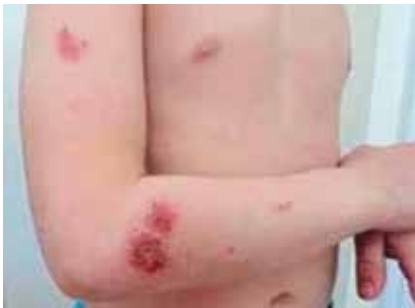Figure 1. Exudative nummular eczema with fluid and crust formation from the lesion.

Reproduced under a Creative Commons Attribution-NonCommercial 4.0 International License from Poudel RR, et al. *J Community Hosp Intern Med Perspect* 2015; 5: 10.3402/jchimp.v5.27909. © 2015 Resham Raj Poudel et al.

subsequently fade as dry, scaly patches.² The eruption can be precipitated by localised injury (such as from scratching, insect bites or burns), infections, contact dermatitis, dry skin or varicose eczema.^{4,7} Secondary lesions occur between 10 days and several months after the primary eruption in a mirror-image configuration on the opposite side of the body. It is characteristic that dormant patches become active again especially if treatment is discontinued.¹

There are four clinical variants of discoid eczema.

- Exudative nummular eczema involves leakage of serous fluid and crust formation from lesions (Figure 1).¹



Figures 4a and b. Exudative discoid and lichenoid chronic dermatosis. Unusual occurrence in a 6-year-old boy.

Reproduced under a Creative Commons Attribution-NonCommercial 4.0 International License from Tabara K, et al. *Postepy Dermatol Alergol* 2013; 30; 403-408. © 2013 Termedia Sp.

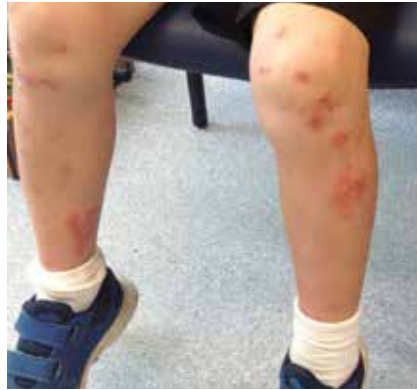

Figure 2. Dry type nummular eczema.

Image reproduced with permission of Professor Gayle Fischer, Sydney, NSW.

- Dry type nummular eczema is less common and consists of multiple dry scaly, round or oval discs on the arms or legs, with scattered microvesicles on an erythematous base on the palms and soles (Figure 2). Itching is minimal in this subtype. It is notably resistant to treatment and persists for years.¹
- Discoid eczema of the hands affects the dorsa of the hands or backs and sides of the fingers (Figure 3). It often develops as a single plaque at the site of the original irritant. Secondary lesions may occur locally, but generalised spread is uncommon.
- Exudative discoid with lichenoid chronic eczema is a widespread, extremely pruritic eruption characterised by discoid lesions with lichenoid and exudative phases that coexist or may alternate rapidly over

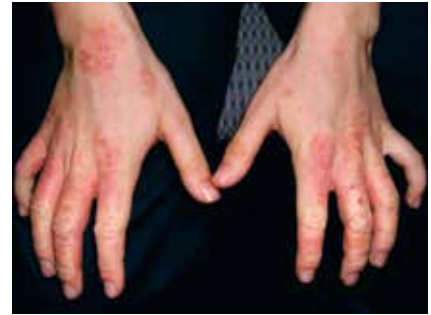
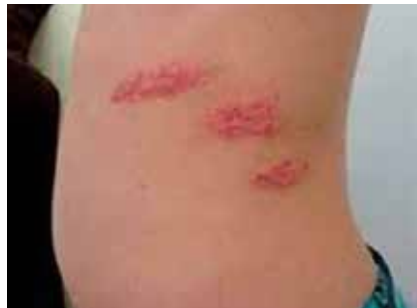
Figure 3. Discoid eczema of the hands.

Image reproduced with permission of Professor Gayle Fischer, Sydney, NSW.

several days (Figures 4a and b). After a chronic course of months or years, it may end in spontaneous cure. It occurs predominantly in Jewish adult men aged 40 to 60 years.¹² There is some conjecture as to whether this is a distinct clinical entity.¹³

Differential diagnoses

Differentiating discoid eczema from other forms of dermatitis is important for optimal management, particularly in avoiding triggers. Differential diagnoses for discoid eczema are summarised in the Table and include the following.

- Discoid eczema may appear to be similar to tinea corporis with central clearing. Tinea corporis is an infection often found after close contact with an infected animal, and presents as annular, scaly erythematous lesions that spread centrifugally (Figure 5).^{11,14}
- Psoriatic lesions differ in their dryness and more prominent silvery scaling with milder irritation (Figure 6).¹¹
- Pityriasis rosea presents with a herald patch and salmon-coloured oval patches with long axes parallel to the ribs, although it may transiently resemble discoid eczema (Figure 7).¹¹
- Pityriasis alba more commonly affects the face and proximal limbs in depigmented lesions.
- Chronic superficial dermatitis tends to affect the limbs more, is oval or round with no infiltration, and is chronic with few fluctuations.

TABLE. DIFFERENTIAL DIAGNOSES FOR DISCOID LESIONS

Differential diagnosis	Differentiating features	Treatment
Tinea corporis	<ul style="list-style-type: none"> • Pruritic oval lesions distributed over the limbs or trunk • Scrapings for microscopy and culture and periodic acid–Schiff stains often demonstrate fungus • Continues until treated 	<ul style="list-style-type: none"> • Topical or oral antifungal medications
Psoriasis	<ul style="list-style-type: none"> • Lesions are dry with more prominent scaling and milder irritation • More commonly involves the scalp, elbows and knees 	<ul style="list-style-type: none"> • Treatment is dependent on disease impact and severity, but includes avoidance of triggers and treatment with topical corticosteroids, phototherapy and systemic agents including biologics
Pityriasis rosea	<ul style="list-style-type: none"> • Presents with a history of a herald patch and oval patches with long axes parallel to the ribs • Self-limiting 	<ul style="list-style-type: none"> • Is self-limiting and resolves after six to 12 weeks • Topical corticosteroids can help relieve itch
Pityriasis alba	<ul style="list-style-type: none"> • Involves depigmentation that affects the face and proximal limbs with spontaneous remission after >1 year 	<ul style="list-style-type: none"> • Moisturisers • Short courses of topical corticosteroids
Chronic superficial dermatitis	<ul style="list-style-type: none"> • Oval or round lesions that tend to affect the limbs more than trunk, with a chronic benign course with no fluctuations 	<ul style="list-style-type: none"> • Emollients • Topical corticosteroids • Phototherapy
Prelymphomatous eruption	<ul style="list-style-type: none"> • Angular pruritic lesions affecting the proximal limbs, flank or trunk that are persistent and may change to lymphoma • Biopsy shows a perivascular infiltrate in the dermis, predominantly of lymphocytes 	<ul style="list-style-type: none"> • Systemic corticosteroids • Phototherapy

- Prelymphomatous eruption more commonly affects the flank, trunk and proximal limbs with angular lesions.
- Allergic contact eczema may present with nummular lesions, although can be differentiated on history and through patch testing.³

Discoid eczema is also more likely to occur in a generalised distribution and is less likely to occur on the face, neck, lips, ears and anogenital areas.⁵ 30% of patients may have both discoid eczema as well as an irritant (or allergic) contact dermatitis.⁵

Pathophysiology

Triggers including bacterial colonisation, contact allergens, certain medications and chronic venous stasis may compromise the cutaneous lipid barrier. This results in the subsequent release of cytokines, including interferon gamma and interleukin 17, and recruitment of T cells, dendritic cells and Langerhans cells. This causes epidermal hyperplasia and the

formation of the lesions characteristic of discoid eczema.³

Association of discoid eczema with surgical sites has been reported, with occurrence of the isomorphic Koebner phenomenon between three months and 10 years after surgery.¹⁰ Alcohol misuse has also been associated with discoid eczema. This relationship might be due to alcohol impairing the immune response, thus predisposing the skin to a bacterial infection, which in turn triggers the eczema.^{8,9} However, there is no reported association between alcohol misuse and other forms of eczema.^{8,9}

Investigations

Discoid eczema is a clinical diagnosis.³ However, exogenous contact dermatitis should be suspected if the condition is unusually severe and persistent, or if the lesions are few, asymmetrical or of unusual configuration. In these cases, patch testing can be performed.^{6,7} Often, scrapings are taken for mycology to exclude tinea corporis.

Some studies have highlighted the role

of infection in triggering and prolonging discoid eczema, and heavy colonisation of lesions by *Staphylococcus* species may increase its severity.¹⁵ Allergic sensitivity to *Staphylococcus* may be partly responsible for secondary dissemination.¹⁶ Thus, bacterial swabs may be taken, especially if the rash is not responsive to therapy.

Although discoid eczema does not generally require a biopsy, histological examination demonstrates a subacute dermatitis, with spongiotic vesicles and lymphohistiocytic infiltrate.^{2,3} Electron microscopy has demonstrated that intercellular oedema leads to a reduction in the number of desmosomes between the cells of the basal layer, whereas those in the stratum spinosum are preserved.

Management

The management of discoid eczema is aimed at restoring the natural skin barrier and minimising exposure to triggering factors. This can be achieved through short, cool showers using gentle soaps or soap substitutes. Tight clothing and

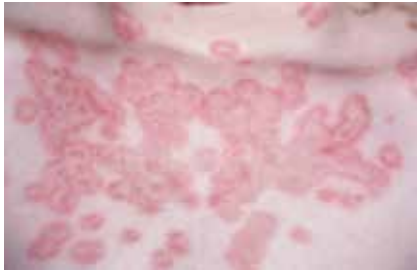


Figure 5. Tinea corporis.
Image reproduced with permission of Professor Gayle Fischer, Sydney, NSW.

irritating fabrics such as wool and nylon should be avoided.^{2,3}

Patients should frequently moisturise, including immediately after showering. Intermittent topical corticosteroids are used to dampen eczema flares.^{2,3} Corticosteroid-sparing agents including topical calcineurin inhibitors (such as tacrolimus and pimecrolimus) may also be used in combination or alternately with topical corticosteroids.

Classically, coal tar pastes or ointments are used in the less acute stages of discoid eczema.¹ As with other types of eczema, there has traditionally been a role for rest and minimisation of stress. Sedating antihistamines also have a role in helping patients with severe pruritus to sleep at night.³

For widespread disease, alternative treatment therapies include narrowband UVB light therapy two to three times weekly, with duration titrated to treatment response.³ Systemic immunosuppressants and immunomodulators have been used as more last-line options for extensive disease.³ Dupilumab is an emerging treatment option for recalcitrant discoid eczema.¹⁷ Other last-line therapies include immunosuppressants such as ciclosporin, methotrexate, mycophenolate and azathioprine.¹⁸ Systemic corticosteroids should be avoided as they are associated with high rates of rebound disease.

Patients with the exudative subtype of discoid eczema may benefit from an oral antibiotic such as cefalexin, clarithromycin or a tetracycline. Secondary bacterial infections should be treated with topical or oral antistaphylococcal antibiotics depending

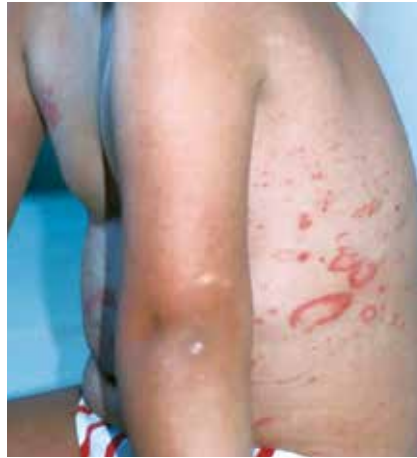

Figure 6. Psoriasis.
Image reproduced with permission of Professor Gayle Fischer, Sydney, NSW.

on the size and distribution of the lesions, with further treatment based on bacterial swab results and local antibiotic resistance.³ Discoid eczema associated with alcohol misuse may be particularly predisposed to becoming secondarily infected, and such patients should be examined carefully to ensure infection has been properly treated.⁹

Referral to a dermatologist is appropriate if the disease does not respond to conservative skin care measures, bland emollients, topical corticosteroids and antibiotics. Referral can also be considered should the diagnosis be in question.

Prognosis

Discoid eczema is chronic, with partial remission during which plaques tend to clear in their centres. Relapse occurs at variable intervals, and is often worse in winter. With appropriate therapy and avoidance of skin irritants, discoid eczema may either clear within a year, or if not, will often persist for many years.² As with other forms of eczema, some patients will experience postinflammatory dyspigmentation of the skin (hypo- or hyperpigmentation).³

Conclusion

Discoid eczema is a skin rash consisting of annular disc-shaped plaques typically affecting the trunk and lower limbs of adult male patients. It is sometimes

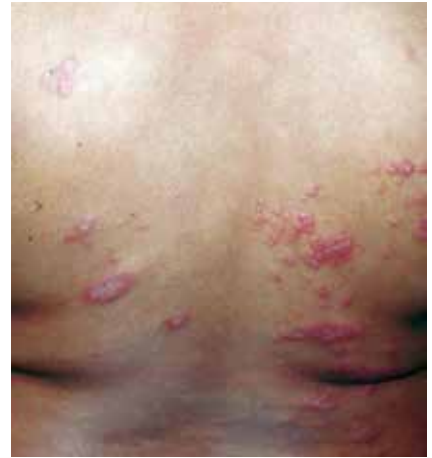

Figure 7. Pityriasis rosea.
Image reproduced with permission of Professor Gayle Fischer, Sydney, NSW.

associated with irritant (or allergic) contact eczema, chronic alcohol misuse, bacterial colonisation and certain medications. In most patients, discoid eczema can be controlled through general skin care measures of avoiding irritants and using regular emollients, intermittent topical corticosteroids and antibiotics as needed. **MT**

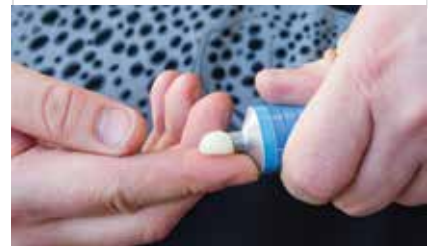References

A list of references is included in the online version of this article (www.medicinetoday.com.au).

COMPETING INTERESTS: None.

ONLINE CPD JOURNAL PROGRAM

What is the role of corticosteroids in the treatment of discoid eczema?



Review your knowledge of this topic and earn CPD points by taking part in **MedicineToday's** Online CPD Journal Program. **Log in to** www.medicinetoday.com.au/cpd

Discoid eczema

More than just dermatitis

JOSHUA FARRELL MB BS; **STEPHEN SHUMACK** OAM, MB BS(Hons), FACD

References

1. Ingram JR. Eczematous disorders. In: Griffiths C, Barker J, Bleiker T, Chalmers R, Creamer D (eds). Rook's textbook of dermatology, 9th ed, volume 2 part 4. Wiley Blackwell 2016. p. 7-9.
2. Bertagnolli R, Licata A. Nummular eczema: identifying-and-treating-a winter problem. *Consultant* 1999; 39: 136-140.
3. Hardin CA, Love LW, Farci F. Nummular dermatitis. Florida: StatPearls Publishing; 2020.
4. Bendl BJ. Nummular eczema of stasis origin: the backbone of a morphologic pattern of diverse etiology. *Int J Dermatol* 1979; 18: 129-135.
5. Silverberg JI, Hou A, Warshaw EM, et al. Prevalence and trend of allergen sensitization in patients with nummular (discoid) eczema referred for patch testing, North American Contact Dermatitis Group Data, 2001–2016. *Contact Dermatitis* 2021; 1-12. Available online at: <https://doi.org/10.1111/cod.13824> (accessed April 2021).
6. Khurana S, Jain VK, Aggarwal K, Gupta S. Patch testing in discoid eczema. *J Dermatol* 2002; 29: 763-767.
7. Fleming C, Parry E, Forsyth A, Kemmett D. Patch testing in discoid eczema. *Contact Dermatitis* 1997; 36: 261-264.
8. Higgins EM, Vivier AD. Cutaneous disease and alcohol misuse. *Br Med Bull* 1994; 50: 85-98.
9. Bruno MC, Vilela MA, Oliveira CA. Study on dermatoses and their prevalence in groups of confirmed alcoholic individuals in comparison to a non-alcoholic group of individuals. *An Bras Dermatol* 2013; 88: 368-375.
10. Yamamoto T. Nummular eczema and isomorphic Koebner response. *Clin Exp Dermatol* 2020; 45: 616-618.
11. Traves KP, Savage K, Studdiford J. Annular lesions: diagnosis and treatment. *Am Fam Physician* 2018; 98: 283-291.
12. Freeman K, Hewitt M, Warin AP. Two cases of distinctive exudative discoid and lichenoid chronic dermatosis of Sulzberger and Garbe responding to azathioprine. *Br J Dermatol* 1984; 111: 215-220.
13. Rongioletti F, Corbella L, Rebora A. Exudative discoid and lichenoid chronic dermatosis (sulzberger garbe) a fictional disease? *Int J Dermatol* 1989; 28: 40-43.
14. Tracy A, Eichenfeld L. Nummular dermatitis. *Pediatr News* 2019; 53: 22.
15. Gong JQ, Lin L, Lin T, et al. Skin colonization by *Staphylococcus aureus* in patients with eczema and atopic dermatitis and relevant combined topical therapy: a double-blind multicentre randomized controlled trial. *Br J Dermatol* 2006; 155: 680-677.
16. Ong PY, Leung DY. Bacterial and viral infections in atopic dermatitis: a comprehensive review. *Clin Rev Allergy Immunol* 2016; 51: 329-337.
17. Choi S, Zhu GA, Lewis MA, et al. Dupilumab treatment of nummular dermatitis: a retrospective cohort study. *J Am Acad Dermatol* 2020; 82: 1252-1255.
18. Roberts H, Orchard D. Methotrexate is a safe and effective treatment for paediatric discoid (nummular) eczema: a case series of 25 children. *Australas J Dermatol* 2010; 51: 128-130.