

# The Achilles tendon

## focus on disorders in the athlete

Disorders of the Achilles tendon are common among runners and in athletes involved in running sports with repetitive jumping, such as soccer and basketball, and in ballet. The middle-aged weekend athlete is also at risk. Here, the clinical presentation and management of the spectrum of Achilles tendon pathology are reviewed. Nonoperative management can relieve pain in most patients.

### PETER LAM

MB BS(Hons), FRACS

Dr Lam is Adult Orthopaedic Foot and Ankle Surgeon at North Shore Private Hospital and St George Hospital, Sydney, NSW.

The Achilles tendon is the largest tendon in the body, connecting the calf muscles to the calcaneus. It transmits forces ranging from two to three times body weight in walking to four to six times body weight in running and jumping. The Achilles tendon, by virtue of its structure and functional demands, is subject to a spectrum of overuse injuries.

Disorders of the Achilles tendon are very common in the running athlete, with a reported incidence ranging from 6.5 to 18.7%. This spectrum of disorders can be subdivided into noninsertional and insertional Achilles tendinitis. Noninsertional tendinitis tends to occur in younger patients, primarily runners, whereas

insertional tendinitis tends to occur in middle-aged, 'weekend' athletes.

The Achilles tendon is formed by the confluence of the tendons from the gastrocnemius and the soleus (Figure 1). The insertion of the tendon is about 1.5 cm distal to the tip of the superior tuberosity of the calcaneus. Interposed between the superior tuberosity anteriorly and the tendon posteriorly is the retrocalcaneal bursa. Posterior to the tendon is a superficial bursa, which lies directly under the skin.

The Achilles tendon is enclosed by a paratenon. The paratenon is not lined with synovial tissue; it contains blood vessels that assist in tendon nourishment.

### IN SUMMARY

- Pain in the Achilles tendon is very common in people who participate in running sports such as soccer, basketball and long distance running, and in ballet dancers. It is also common in middle-aged weekend athletes.
- The spectrum of Achilles tendon disorders can be divided into noninsertional and insertional Achilles tendinitis.
- For the vast majority of patients, good relief can be achieved using nonoperative measures. These include activity modification with stretching, the use of heel lifts (generally 0.5 to 1.5 cm), oral nonsteroidal anti-inflammatory medication and orthotics (if hindfoot malalignment is present).
- Avoid corticosteroid injections into the Achilles tendon as the steroid will predispose the tendon to rupture.
- If symptoms persist despite at least six months of nonoperative treatment then surgery may be required.

continued

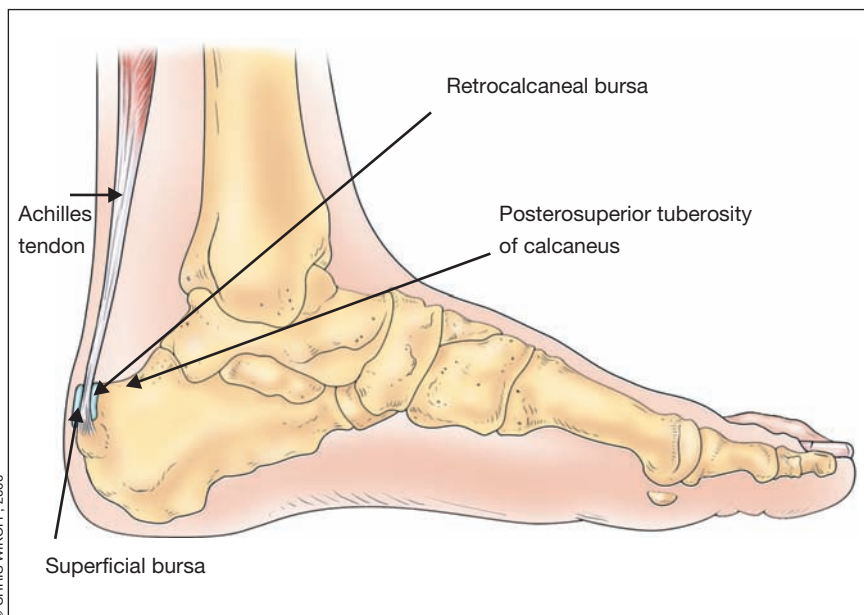


Figure 1. Anatomy of the Achilles tendon.

The tendon is narrowest 4 cm above the level of insertion into the calcaneus. This narrowing is located in a hypovascular zone that extends from 2 to 6 cm proximal to the tendon's insertion. This zone is the most common site of tendon pathology, including paratendinitis, tendinosis and tendon rupture.

### Noninsertional Achilles tendinitis: clinical presentations Achilles paratendinitis

Achilles paratendinitis is inflammation of the paratenon surrounding the Achilles tendon.

#### Symptoms

Patients complain of pain anywhere along the Achilles tendon from the point of attachment to the calcaneus. Early on, the pain increases with activity and is relieved with rest. Later, chronic pain occurs with walking.

#### Signs

Examination reveals direct tenderness on palpation of the Achilles tendon with thickening of the peritendinous tissues.

Inflamed tissue within the paratenon will not move with excursion of the underlying tendon, as assessed by passive dorsiflexion and plantarflexion of the foot. There may be crepitus.

### Achilles tendinosis

Achilles tendinosis describes intratendinous degeneration without an associated inflammatory response. Histologically, these lesions show no evidence of a reactive inflammatory response. Occasionally there are areas of necrosis or calcification in the tendon.

#### Symptoms

By definition, tendinosis is asymptomatic tendon degeneration. A patient may have a history of a painless mass 4 to 6 cm proximal to the tendon insertion.

#### Signs

There is a palpable non tender nodule at the area of Achilles tendon degeneration (Figure 2).

In contrast with Achilles paratendinitis, this nodule will move with excursion of the tendon.

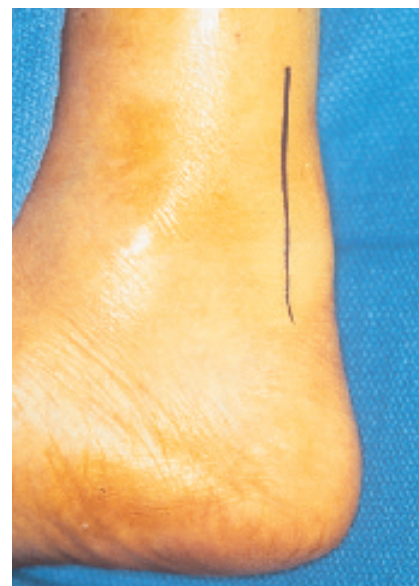

Figure 2. Achilles tendinosis with a nodule in the Achilles tendon.

### Achilles tendinitis

Achilles tendinitis refers to tendinosis with secondary paratendinitis and occurs as overuse continues.

#### Symptoms

The symptoms are the same as for paratendinitis – pain anywhere along the tendon that eventually becomes chronic on walking.

#### Signs

Examination reveals direct tenderness on palpation with thickening of the tendon. The inflamed tissue moves with excursion of the underlying tendon. There may be crepitus from the associated paratendinitis.

### Rupture of the Achilles tendon

Histological findings have implicated tendinosis as the primary underlying pathological condition that predisposes to tendon rupture. However, the cause of tendon failure is multifactorial. Tendon rupture has been associated with gout and with the use of either oral or injected corticosteroids.

Partial ruptures are often seen in well trained athletes whereas complete ruptures are seen more often in untrained, middle-aged individuals. Partial ruptures are usually located on the lateral aspect of the tendon.

Reports indicate that 75% of Achilles tendon ruptures occur in weekend athletes between the ages of 30 and 40 years and with a male to female incidence ratio ranging from 2:1 to as high as 12:1.

### Symptoms

Most frequently, the tendon rupture occurs without pre-existing symptoms – in one study, only 15% of patients reported posterior calf pain or heel pain prior to rupture.

Rupture ultimately occurs when there is an acute mechanical overload of the tendon. These injuries typically occur with rapid eccentric loading of the tendon – that is, when the foot and ankle are rapidly dorsiflexed with the knee in

extension and with the soleus muscle contracted.

Patients often feel as if they are struck from behind when the Achilles tendon ruptures. Some sense or hear a ‘pop’ at the time of rupture. Immediately, there is weakness with push-off, and patients are unable to continue with their activities. Initially, the pain may not be dramatic, but discomfort increases with the onset of swelling and bruising.

### Signs

Examination is performed with the patient in the prone position. The loss of the resting tone in the Achilles tendon is suggestive of a rupture (Figure 3a). However, a palpable defect in the tendon proximal to the insertion of the Achilles tendon into the calcaneus is pathognomonic of a rupture (Figure 3b). There is a positive Thompson test – a lack of passive ankle plantarflexion with squeezing of the calf muscles (Figure 3c). Usually the patient can still plantarflex the ankle

when non-weight-bearing because of intact tibialis posterior, long toe flexors and peroneal tendons.

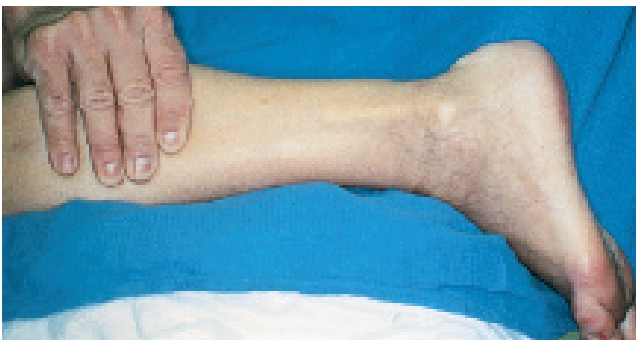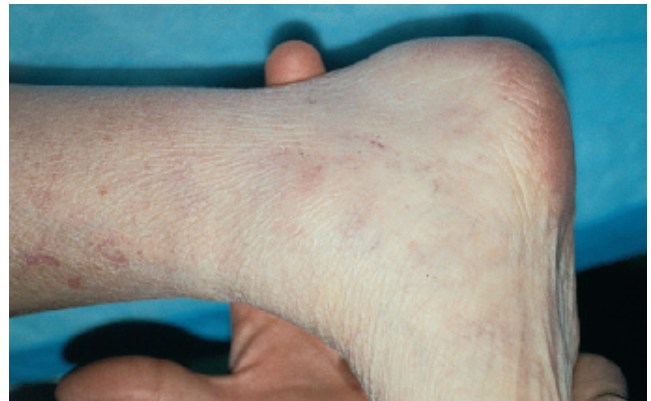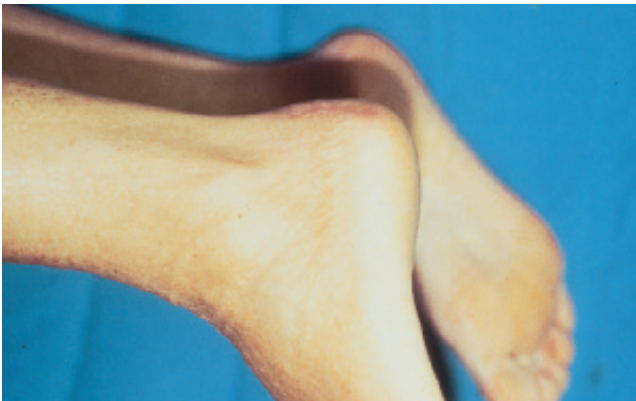## Noninsertional Achilles tendinitis: management

### General comments

Most cases of Achilles paratendinitis, tendinitis, tendinosis and partial rupture of the Achilles tendon can be successfully managed nonoperatively. Total rest is usually not required but activity modification is.

Basic nonoperative modalities include activity modification with stretching (Figure 4a), the use of a 0.5 to 1 cm heel lift, heat and oral nonsteroidal anti-inflammatory drugs. Topical nonsteroidal anti-inflammatory drugs have not been shown to be effective. Topical nitrobid is being trialled; results are promising, but headache is a common side effect.

Hindfoot malalignment such as hind-foot varus will result in tightness of the Achilles tendon and predispose to



Figures 3a, b and c. Achilles tendon rupture. a (above left). Loss of resting tone in the left foot following acute Achilles tendon rupture. The patient is in the prone position with knees flexed at 90 degrees. b (above right). Permanent defect in Achilles tendon following its earlier complete rupture. In contrast, in the acute situation, one usually feels, rather than sees, the defect in the tendon. c (left). Normally the foot plantarflexes when the calf is squeezed – a negative Thompson test. Here, as the Achilles tendon has ruptured, the foot cannot plantarflex when the calf is squeezed – a positive Thompson test. The tendon defect is obvious in this acute case as ankle swelling has been reduced (pre-operatively) using a cryo-cuff.

continued



Figures 4a and b. Management of noninsertional Achilles tendinitis a (left). Tendo Achilles stretching. b (right). A short leg walking boot.

Achilles tendinosis. Thus, orthotics may be required if there is flexible hindfoot malalignment.

A period of immobilisation of seven to 10 days (sometimes longer) may be indicated for patients with severe symptoms. Immobilisation can be accomplished with either a short leg walking cast or a brace (Figure 4b).

Avoid corticosteroid injections into the Achilles tendon as the steroid will predispose the tendon to rupture.

With these modalities, symptoms will resolve in most patients (90 to 95%). In general, if athletes begin treatment within the first two weeks of symptoms, most can resume training within two weeks. If they have had symptoms for longer and have kept on training, sustained symptom relief will usually require six weeks of rest from training.

If clinical examination is suggestive of partial tendon rupture rather than paratendinitis, tendinitis or tendinosis, then conservative treatment may be required for up to four to six months.

Operative intervention should only

be considered after a comprehensive programme of nonoperative treatment has failed. In most cases, if symptoms have persisted for six months despite nonoperative management, then surgical treatment is warranted.

### Specific comments

#### Achilles paratendinitis

As stated above, Achilles paratendinitis often responds to rest, but in chronic cases the Achilles paratenon may become fibrotic and stenosed. In cases where conservative modalities have failed, some authors have advocated brisement, which is the mechanical lysis of adhesions by an infusion of 15 mL of local anaesthetic into the subparatenon space. Others have described open lysis with removal of most of the paratenon but for the anterior portion and the adjacent fatty tissue, which provide a crucial blood supply to the Achilles tendon.

#### Achilles tendinosis or tendinitis

Nonoperative management, including activity modification, may often resolve

the disorder. However, a one to two week period of non-weightbearing with immobilisation may be necessary in severe cases.

Oral nonsteroidal anti-inflammatory medications, ice and stretching are also effective.

Orthotics may be indicated if evaluation of the foot reveals a correctable hindfoot malalignment. As mentioned above, topical nonsteroidal anti-inflammatory medications have not been shown to be effective.

Nonoperative treatment should be continued for four to six months for symptomatic tendinosis, but may be individualised depending on patient circumstances and needs.

Recent reports on the use of heavy load eccentric calf muscle training have reported very good results for the treatment of chronic Achilles tendinosis (Figures 5a, b and c).

#### Partial tendon rupture

As mentioned above, treatment consists of heel lifts, ice and rest. If a large partial rupture is encountered, surgical repair should be undertaken. Ultrasonography and/or MRI may help in confirming a clinical diagnosis of a partial tear.

#### Complete tendon rupture

Treatment options are dependent upon patient expectations, performance levels and the presence of systemic illness. When deciding on operative versus nonoperative management, the risks and benefits of the various treatment methods need to be carefully discussed with the patient.

Closed treatment with prolonged short leg cast immobilisation with the foot plantarflexed and non-weightbearing for six to eight weeks risks loss of strength, decreased motion and increased re-rupture rate. When treated closed, the re-rupture rate is about 20%; with operative intervention, the re-rupture rate is only 2%. The strength of the



tendon after nonoperative treatment is only 75% of normal strength, but with surgical repair the tendon strength is near-normal.

The greatest advantage of open repair is restoration of the tendon's anatomical length and near-normal tendon strength, and surgical repair is recommended for all competitive athletes who plan to return to their previous activity levels. However, surgery, despite its superior results, does have its own inherent risks – including infection and wound breakdown. The risk of surgical complications can be as high as 5%.

Surgical repair is followed by an aggressive physiotherapy regimen. There is no cast immobilisation once the sutures are removed on the twelfth post-operative day.

Controlled early mobilisation results in significant reduction in adhesion formation and a stronger tendon repair. Following this active rehabilitation programme, full range of motion can be

expected in 90% of patients at six weeks, and over 90% will return to sports participation within six months.

### **Insertional Achilles tendinitis: clinical presentations**

#### **Retrocalcaneal bursitis**

This is inflammation of the retrocalcaneal bursa. It occurs not only in athletes but also in rheumatoid arthritis – the overall incidence of retrocalcaneal bursitis with rheumatoid arthritis is reported to be between 2 and 10%.

#### **Symptoms**

There is posterior heel pain. Pain is worse with walking, especially on inclines.

#### **Signs**

Signs include swelling and erythema over the posterosuperior calcaneal tuberosity. There is tenderness and swelling (a bulge) medial and lateral to the Achilles tendon in this region. The pain is aggravated by dorsiflexion of the ankle beyond

the neutral position and is relieved by plantarflexion.

X-rays of the foot and ankle will often show a prominent posterosuperior tuberosity of the calcaneus.

When difficulty in diagnosis arises, an MRI and bone scan may be helpful.

An MRI will show an enlarged, inflamed bursa (Figures 6a and b). A bone scan will show increased uptake along the superior wall of the posterior calcaneus.

### **Insertional Achilles tendinitis**

This is a condition of chronic overuse. It tends to occur in the older patient and in overweight, sedentary individuals.

#### **Symptoms**

There is posterior heel pain in insertional Achilles tendinitis. It is exacerbated by running up hills or on hard surfaces.

#### **Signs**

At the insertion site of the Achilles tendon



Figures 5a (left), b (middle) and c (right). Eccentric calf muscle training.

continued

there is a prominence and point tenderness (Figures 7a and b).

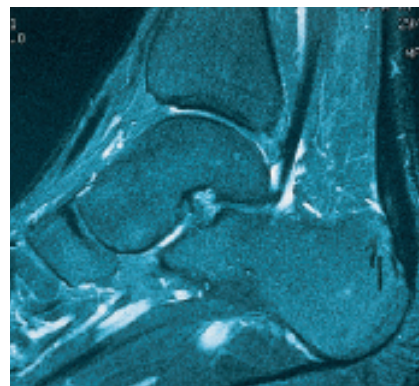
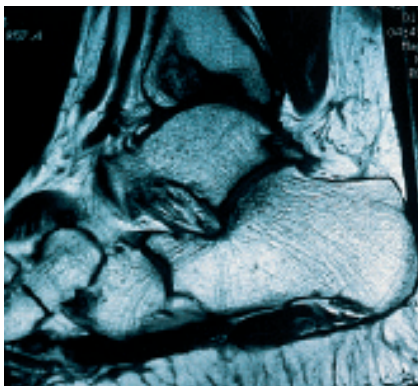
X-rays often reveal a spur at the site of insertion of the Achilles tendon (see Figure 8).

### Superficial Achilles bursitis

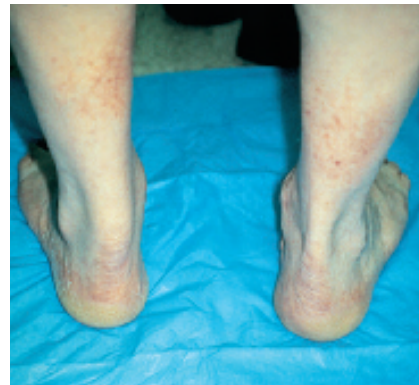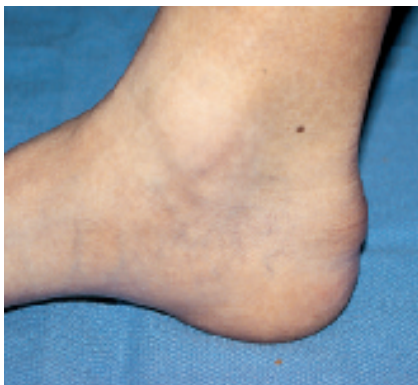Superficial Achilles bursitis is due to irritation of the superficial Achilles bursa by the heel counter of shoes.

### Symptoms

The patient complains of localised posterior heel pain, and difficulty wearing fashionable shoes.



Figures 6a and b. Retrocalcaneal bursitis secondary to prominent poster superior tuberosity of the calcaneus. a (left). MRI showing normal tendon (thin and black). b (right). MRI showing abnormal tendon (thick and grey) with adjacent oedematous bone marrow. Surgeons excise the bone rubbing on the tendon.



Figures 7a and b. a (left). Visible and palpable prominence at the insertion of the Achilles tendon consistent with insertional Achilles tendinitis. b (right). Chronic Achilles tendinosis with a nodule and thickening of the left Achilles tendon due to mucoid degeneration of the tendon.

### Signs

There is localised tenderness of the heel with thickening of the skin and callus formation ('pump bump'). The signs are located over the bony posterolateral prominence of the heel. The Achilles tendon itself and retrocalcaneal bursa are not tender.

### Insertional Achilles tendinitis: management

#### General comments

The nonoperative treatment protocol is essentially the same for both insertional Achilles tendinitis and retrocalcaneal

bursitis, except that corticosteroid injection should be avoided in insertional Achilles tendinitis.

### Specific comments

#### Retrocalcaneal bursitis

If the shoe heel counter is causing external compression then the footwear must be modified – for example, to an open back shoe such as a clog. In the acute situation, ice, nonsteroidal anti-inflammatory medication and a 1 to 2.5 cm heel lift may help to relieve the symptoms. Activity modification involves rest, decreased mileage, and avoidance of hills and hard surfaces. In resistant cases, the ankle may be immobilised in a short leg walking cast or boot for 4 weeks.

Injection of steroid into the retrocalcaneal bursa has been advocated. However, even though the injection is into the bursa, not the Achilles tendon, there is always the concern that the steroid solution may come into contact with the Achilles tendon.

If debilitating symptoms persist despite at least six months of nonoperative treatment then surgery is indicated. This involves resection of the superior process of the calcaneus and the retrocalcaneal bursa (Figure 9). This may be done either endoscopically or by open surgery. The advantages of the endoscopic technique are less postop pain, more rapid rehabilitation and an earlier return to sports.

When treating a running athlete with recalcitrant retrocalcaneal bursitis, always exclude the possibility of a systemic inflammatory disease. This is especially important if the process is bilateral.

#### Insertional Achilles tendinitis

The treatment programme is similar to that for retrocalcaneal bursitis. Most patients with insertional Achilles tendinitis will respond to this nonoperative regimen. It involves the use of nonsteroidal anti-inflammatory drugs, 0.5 to 1 cm heel lifts to unload the Achilles

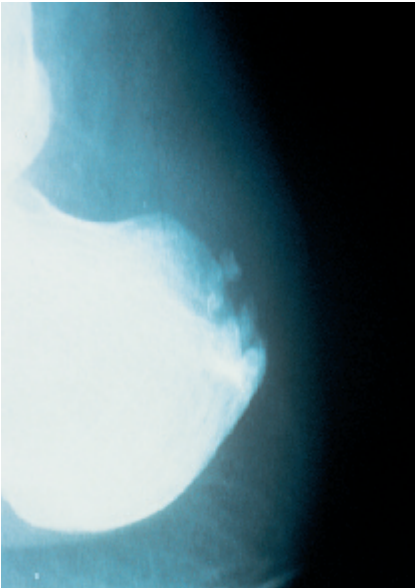


Figure 8. Insertional Achilles tendinitis. Note the bony spur and the ossification within the Achilles tendon just above its insertion.

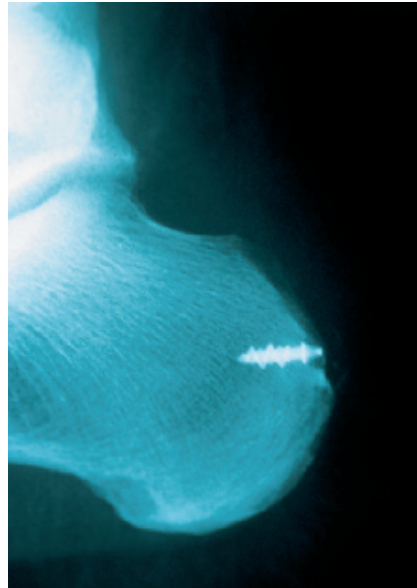


Figure 9. X-ray following excision of the prominent posterosuperior tuberosity of the calcaneus.

tendon, and Achilles tendon stretches. Activity modification involves rest and cross training in non-impact sports. Temporary immobilisation for up to six weeks may be required in severe cases.

Orthotics may be helpful in correcting a pronated or supinated foot. If symptoms persist despite at least six months of nonoperative treatment then surgery may be indicated. This involves resection of the posterior process of the calcaneus and debridement of the tendon. This is associated with good to excellent results in 85% of cases.

#### Superficial Achilles bursitis

Nonoperative management is almost always effective. This involves relieving the external pressure with a soft, well fitting shoe heel counter.

#### Conclusion

Achilles tendon disorders are a spectrum of disorders that can be divided into two groups – noninsertional (paratendinitis, tendinosis, tendinitis and ten-

don rupture) and insertional (retrocalcaneal bursitis, insertional Achilles tendinitis and superficial Achilles bursitis). The clinical features and initial management programme in the conditions within each group are similar. It is important to note that in most patients good pain relief can be achieved using simple nonoperative measures. **MT**

#### Bibliography

1. Alfredson H, Pietila T, Jonsson P, Lorentzon R. Heavy-load eccentric calf muscle training for the treatment of chronic Achilles tendinosis. *Am J Sports Med* 1998; 26: 360-366.
2. Helal B, Rowley DI, Cracchiolo A, Myerson MS. *Surgery of disorders of the foot and ankle*. London: Martin Dunitz, 1996.
3. Jones DC. Achilles tendon problems in runners. *AAOS Instructional Course lectures* 1998; 47: 419-427.
4. Coughlin MJ, Mann RA, editors. *Surgery of the foot and ankle*. 7th ed. St Louis: CV Mosby, 1996.