

## An irregular, dappled, pigmented patch

STEVEN KOSSARD FACD

The diagnosis of pigmented lesions is a daily challenge in general practice. Dermatoscopy can provide extra clues, but requires significant expertise. This series will help you hone your skills.

### Case presentation

Over a five-year period, a 54-year-old man developed an irregular pigmented patch (1.9 cm x 1 cm) anterior to his right sideburn (Figure 1). Dermatoscopy revealed a light tan lesion with a prominent broad pigment network formed by numerous oval to round flesh-coloured spaces (Figure 2). A central dark hair could be seen in some of the spaces. Skin biopsy showed that the epidermis had broad, pigmented, club-shaped epidermal ridges adjacent to hair follicles (Figure 3). There was no junctional or nested melanocytic proliferation.

### Diagnosis

This man's lesion was diagnosed as a benign solar lentigo.

### Discussion

The broad diameter pigment network in this lesion is due to an absence of pigment within the follicular orifices plus broad club-shaped ridges, which are seen in solar lentigines. The broad network differs from the fine filamentous network produced by an elongated and thin ridge system (seen in freckles and some moles). In early lesions, it may be difficult to distinguish between a solar lentigo and lentigo maligna with dermatoscopy; in this case, skin biopsy established a definite diagnosis.

### Keypoint

The follicular orifices on the face create a pigment pseudo-network that differs from the network seen at other sites, where a well developed epidermal rete ridge system is associated with a fine diameter mesh.

MT

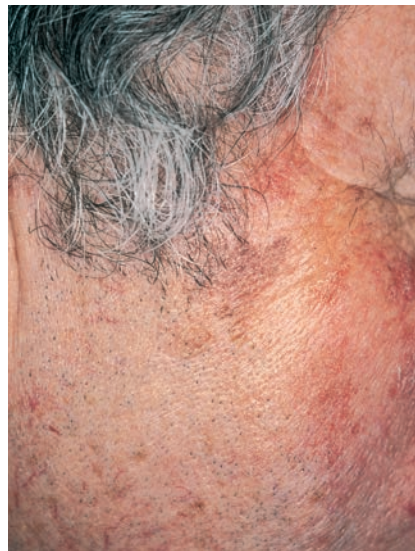

Figure 1. Irregular tan-coloured pigmented macule anterior to the patient's right sideburn.

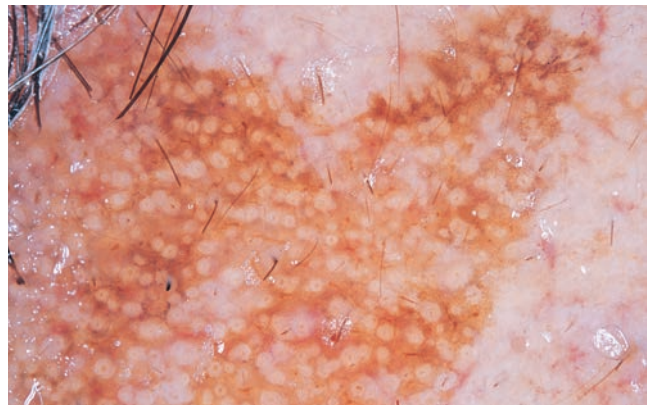


Figure 2. Dermatoscopy showing a coarse diameter network with round flesh-coloured spaces, some of which contain a pigmented hair shaft.

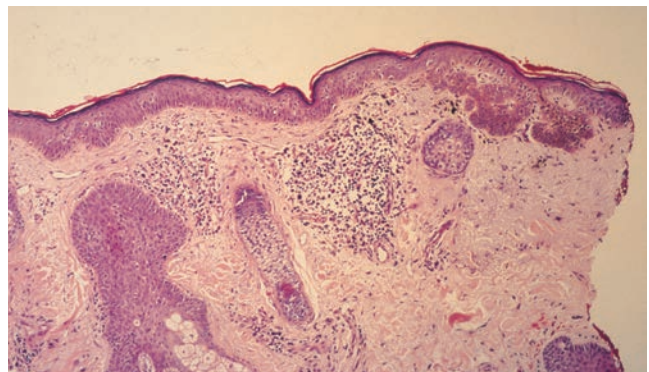


Figure 3. Skin biopsy showing coarse club-shaped, pigmented ridges forming a broad band within an adjacent pale epidermis. Two hair follicles are seen in the left half of the field.

Professor Kossard is Associate Professor, Skin and Cancer Foundation and St Vincent's Hospital, Darlinghurst, NSW.