

Investigating a patient with a positive test for antigliadin antibodies

BARBARA DEMEDIUK MB BS, FRACP

Serological testing for coeliac disease has made screening much more accessible for people with suspicious symptoms or a family history of the condition. However, positive serology does not equal a diagnosis.

Dr Demediuk explores traps for the unwary.

Remember

- Coeliac disease (gluten sensitive enteropathy) is underdiagnosed. Classic signs and symptoms of malabsorption are uncommon, and patients often present with either mild symptoms or clinically silent disease. Coeliac disease is not just a disease of childhood, and the diagnosis is now commonly made in adults.
- Think of coeliac disease in patients with unexplained iron or folate deficiency, nonspecific gastrointestinal symptoms (often diagnosed as irritable bowel syndrome) or osteopenia, as well as the relatives of patients who have coeliac disease. About 10% of first degree relatives may be affected.
- A positive test for antigliadin antibodies may indicate that an individual has coeliac disease. However, histology of the small bowel mucosa is essential to confirm the diagnosis, and will classically show villous atrophy in patients with coeliac disease (Figure 1). Duodenal biopsies are usually obtained at gastroscopy.

Dr Demediuk is Visiting Gastroenterologist and Hepatologist, Department of Gastroenterology, St Vincent's Hospital, Melbourne, Vic.

The views published in this series are those of the authors and are not necessarily indicative of those held by all members of the Digestive Health Foundation or GESA.

Assessment

- Serum antibody tests for coeliac disease include IgA and IgG antigliadin antibodies, IgA endomysial antibody (Figure 2) and IgA tissue transglutaminase antibody.
- Endomysial and tissue transglutaminase antibodies are more specific than antigliadin antibodies and have a higher positive predictive value. In the future, tissue transglutaminase antibody may become the test of choice.
- Histology is still required if serology tests are negative in a patient when the likelihood of coeliac disease is high – for example, a symptomatic patient who has either an unexplained nutritional deficiency or a relative with coeliac disease.
- In individuals with a low likelihood of

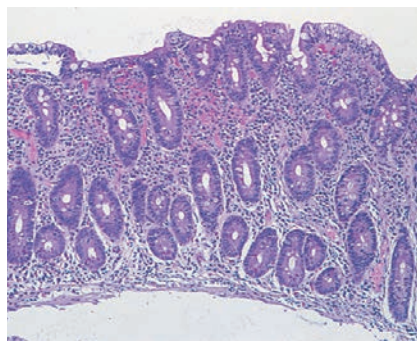


Figure 1. Typical flat small bowel mucosa in a patient with coeliac disease. Milder histological changes may also be seen.

coeliac disease, a negative result is useful in excluding the diagnosis. In such patients, a positive test for antigliadin antibodies may represent a false positive – this is more likely if the result is weakly positive. Consider referral to a gastroenterologist if it is not clear whether a biopsy is necessary.

- There is no role for a gluten-free diet prior to small bowel biopsy. The diet may result in some recovery of the mucosa and make histological diagnosis difficult.

Management

- A lifelong gluten-free diet is essential, and will involve exclusion of the following cereals: wheat, rye, barley and (possibly) oats. A gluten-free diet eliminates the risk of malignancy and reverses nutritional deficiencies.
- Screening for nutritional deficiencies is recommended with full blood examination, iron studies, vitamin B₁₂, folate, calcium, albumin, 25-hydroxy vitamin D. A bone mineral density measurement should be considered.
- Referral to a dietitian and coeliac society is advised.
- Repeat small bowel biopsy and gluten rechallenge are often not required.
- Antibody tests may be used to monitor the response and adherence to a gluten free diet. Annual follow up is recommended.
- Antibody tests are useful to screen relatives.

MT

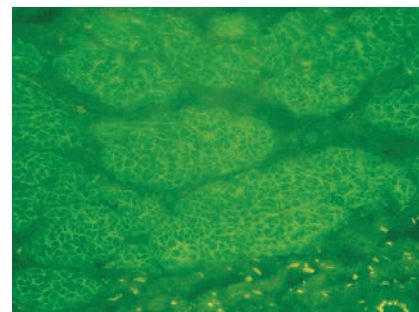


Figure 2. IgA endomysial antibody. Positive immunofluorescence (yellow-green) of reticulum surrounding muscle fibres in monkey oesophagus.