

A reticulate and stippled pigmented patch

STEVEN KOSSARD FACD

The diagnosis of pigmented lesions is a daily challenge in general practice. Dermatoscopy can provide extra clues, but requires significant expertise. This series will help you hone your skills.

Case presentation

A 28-year-old man presented with a large (9 x 16 cm) dark brown patch localised to his left inner upper arm and shoulder (Figure 1). The pigmentation had appeared at the time of puberty, and had remained static for a number of years. The patch had a reticulate and stippled pattern with an irregular border. Dermatoscopy revealed a prominent and extensive pigment network that was uniformly coloured (Figure 2). Skin biopsy showed an epidermis that had a well developed rete ridge system which was deeply pigmented at its base, but the number of melanocytes appeared normal and there were no melanocytic nests (Figure 3).

Diagnosis

The pigmented patch was diagnosed as a pigmented epidermal naevus (Becker's naevus).

Discussion

The well formed pigmented rete ridge system that was shown on biopsy accounts for the prominent network seen on dermatoscopy. In contrast to large melanocytic naevi, which are usually congenital and contain nests of melanocytes, Becker's naevus has a late onset and lacks nests. It is a hyperpigmented epidermal naevus. Hypertrichosis and increased smooth muscle elements in the dermis may occur in association with some Becker's naevi.

Keypoint

A prominent pigment network may be due to increased melanin in the epidermal ridges of the skin, such as found in Becker's or pigmented epidermal naevi. This occurs in the absence of significant melanocytic proliferation or nesting. **MT**

Professor Kossard is Associate Professor, Skin and Cancer Foundation and St Vincent's Hospital, Darlinghurst, NSW.

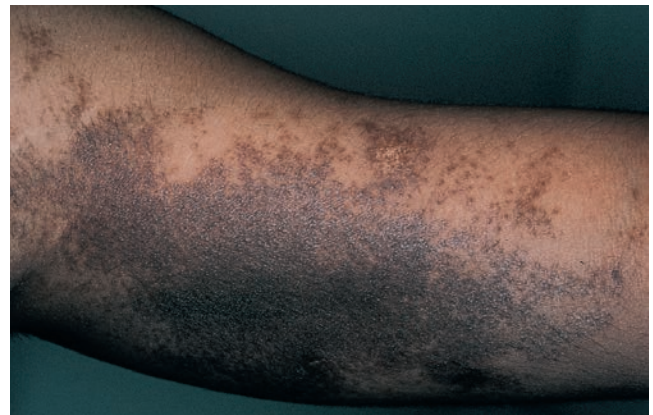

Figure 1. Reticulate and stippled pigmented patch on the patient's left upper arm and shoulder.




Figure 2. Dermatoscopy demonstrating an extensive pigment network with uniform colour.

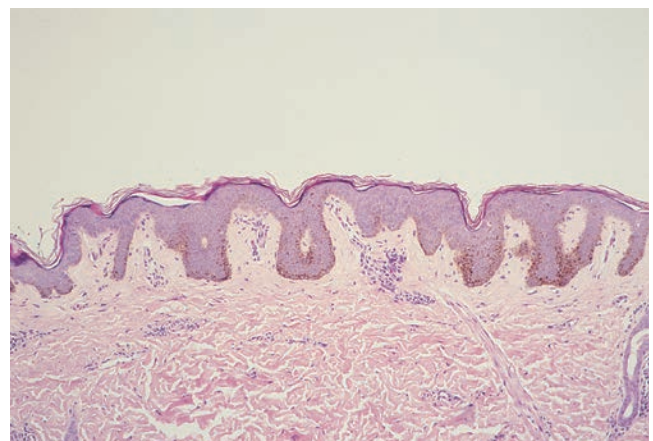


Figure 3. Skin biopsy showing an epidermis with well formed rete ridges with melanin pigment at their tips but no melanocytic nests.