

Scrotal swellings an approach for GPs

A careful history and physical examination are keys to accurately diagnosing the cause of a scrotal swelling and implementing an appropriate course of action.

DAVID GOLOVSKY
MB BS, FRCS, FRACS

Dr Golovsky is a Urologist,
Department of Urology,
St Vincent's Clinic, Darlinghurst,
NSW.

When I was in medical school, the most famous picture in my surgical textbook was that of a gentleman transporting his hydrocele before him in a wheelbarrow. Most scrotal swellings that present are somewhat smaller in size, but there is still the occasional patient with an enormous swelling who was too embarrassed to present earlier and has expressed ultimate denial of its existence.

Accurate diagnosis of a scrotal swelling begins with an adequate history, and a careful physical examination should be performed with the patient in the standing position whenever possible. Key questions to consider are:

- Is it possible to 'get above' the swelling (i.e. can the spermatic cord structure above it be defined)?
- Is the swelling solid or cystic?
- Can the swelling be transilluminated?
- Is the swelling acute or chronic?

The most acute and urgent cause in older children and young adults is testicular torsion. The most dangerous cause of a chronic swelling is a tumour, which must be diagnosed and treated accordingly.

Scrotal swellings in children

Causes of scrotal swellings in childhood are listed in Table 1.

Testicular torsion

An acutely swollen painful testis held high with an overlying redness of the scrotum in an older child or adolescent is testicular torsion until proven otherwise (Table 2). It can be associated with trauma, but it may also occur suddenly without warning and even during sleep.

Features of testicular torsion include acute onset of scrotal pain and swelling, with nausea and/or vomiting. Occasionally it is associated with an undescended testis, but more often there is a so-called bell clapper testicular deformity or testis with a transverse lie – the other testis should be checked because the anatomical variation is usually bilateral (Figures 1a to c). There is no pain relief on elevation of the scrotum (i.e. negative Prehn's sign). Colour Doppler ultrasonography shows no blood flow in the testicular artery.

If testicular torsion is suspected, the patient must be transferred to hospital for urgent surgical

IN SUMMARY

- The keys to diagnosis of a scrotal swelling are an adequate history and a careful physical examination.
- Swellings in the scrotum are either acute or chronic.
- An acutely swollen painful testis held high with an overlying redness of the scrotum in an older child or adolescent is testicular torsion until proven otherwise.
- Epididymo-orchitis is quite uncommon in children and torsion is less common in adults. If the diagnosis of epididymo-orchitis is uncertain, surgery is indicated to exclude testicular torsion.
- A patient with any mass inside the actual testis requires urgent referral to a urologist because it is a tumour until proven otherwise.

Table 1. Features of scrotal swellings in childhood

	Painful	Can get above	Transilluminable	Reducible	Surgery
Testicular torsion	Yes	Yes	No	No	Urgent
Torsion appendage	Yes	Yes	No	No	Urgent if diagnosis is uncertain
Infantile hernia	No (unless strangulated)	No	Yes or no	Yes or no	Only urgent when strangulated
Infantile hydrocele	No	No	Yes	Yes	Elective

Table 2. Typical features of testicular torsion

- Occurrence in older children, adolescents or young adults
- Acute onset of scrotal pain and swelling
- Nausea and/or vomiting
- Testis with transverse lie or bell clapper deformity (occasionally, a retracted testis)
- No pain relief with respect to scrotal elevation (negative Prehn's sign)
- No blood flow in testicular artery on colour Doppler imaging

exploration because delay can cause irreversible testicular ischaemia. Blood flow must be restored within about six hours, so speed is the essence. The testis is rotated to restore the normal anatomical configuration and circulation, and both testes are then fixed by sutures at both poles to prevent future rotation. Unfortunately, a dead testis sometimes needs to be removed.

Other acute swellings

A twisted appendage of the testis (hydatid of Morgagni) can cause a painful swollen scrotum and must be differentiated from true torsion of the testis. The diagnosis is essentially clinical, relying on a

high degree of suspicion and examination findings. Ultrasound is not helpful in making a diagnosis, but Doppler assessment can be of assistance by indicating excellent flow in the testicular artery.

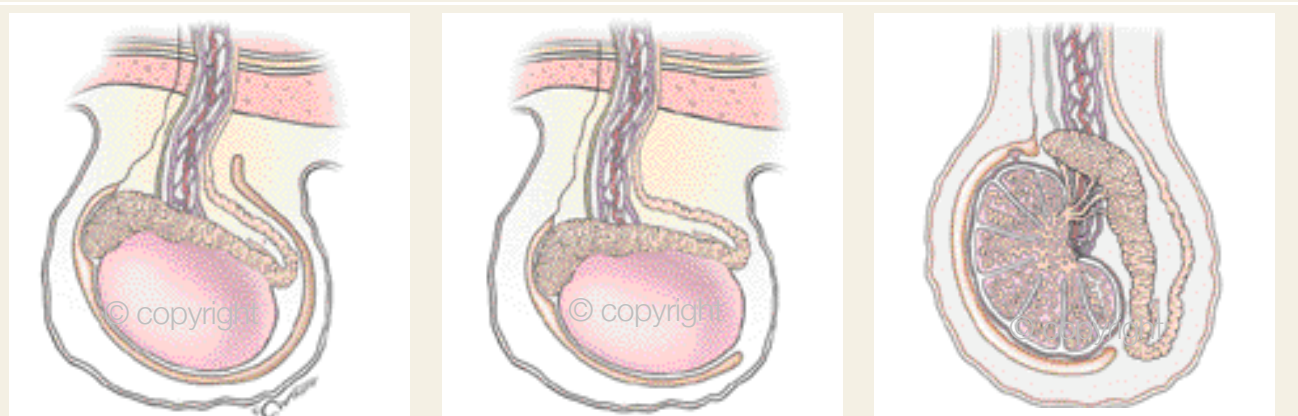
Chronic swellings

The most common scrotal swelling in children is probably an infantile hydrocele due to a patent processus vaginalis. The swelling may vary – even from day to day – but discomfort is not a feature. Its differential diagnosis is infantile hernia, which is due to a patent processus vaginalis containing abdominal contents.

Infantile hydrocele and infantile hernia



Common anatomical findings associated with testicular torsion



Figures 1a to c. Testicular torsion is often associated with the bell clapper testicular deformity (left) or with a transverse lie of the testis (centre). The normal orientation is shown for comparison (right).

© CHRIS WIKOFF, 2005

are treated the same way, with inguinal exploration and dissection of the hernial sac or a patent processus vaginalis. Pains-taking dissection is essential to ensure that the blood vessels and vas deferens in the spermatic cord are protected. Surgery is usually elective, but is urgent if strangulation of hernial contents is suspected.

Scrotal swellings in adolescents and adults

There are several causes of scrotal swellings in adolescence and adulthood (Table 3). If pain is present, a diagnosis must be made so appropriate treatment can be commenced. The most common dilemma is a painful lump that could be either testicular torsion or epididymo-orchitis. A strangulated hernia is usually easily differentiated from these, and is nearly as urgent as torsion.

Testicular torsion

Testicular torsion can occur in adolescents and young adults as well as in children (see the section beginning on page 45). Typical features are summarised in Table 2.

Epididymo-orchitis and orchitis

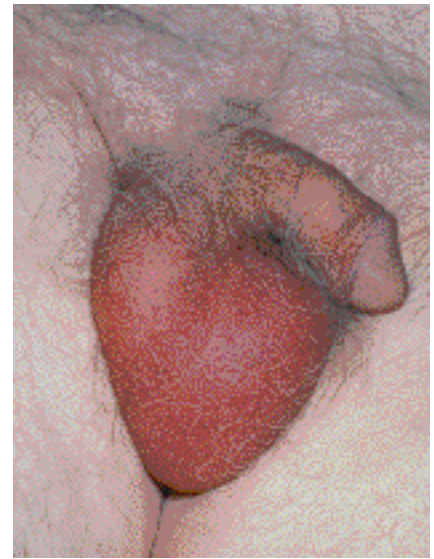The patient with epididymo-orchitis presents with a red, hot scrotum and fever (Figure 2). The onset of scrotal pain and swelling is sudden, and urinary symptoms or reactive hydrocele may or may not be present. The epididymis (and

sometimes the testis) will be firm and enlarged. Prehn's sign is positive.

True epididymo-orchitis is most commonly associated with genitourinary infection, and sometimes it may complicate a urethral infection from a sexual contact. Diagnostic aids include urinalysis for leucocytes and nitrites, midstream urine culture, and urethral swab for STIs, including chlamydia and gonococcus. Colour flow Doppler imaging is normal.

Cephalexin is an excellent antibiotic for mild infection; norfloxacin is a good choice if there is possible associated prostatitis or suspected organism resistance. If the infection is severe, consider intravenous drug therapy with gentamicin and possible admission to hospital. Epididymo-orchitis secondary to a STI would warrant a two-week course of doxycycline, but the urethral swab and microurine should always be checked before starting treatment. If the diagnosis is uncertain, surgery is indicated to exclude testicular torsion.

Orchitis can occur with mumps, which causes swelling of the testes and often accompanying parotitis. Often the swelling of the testes and parotid gland is bilateral. Mumps can cause quite severe pain and swelling; affected patients will require adequate analgesia, antipyretics and sometimes corticosteroids. The maxim 'rest is the best cure for pain' applies.



DR P. MARAZZISCIENCE PHOTO LIBRARY

Figure 2. Epididymo-orchitis.

Chronic infections

Tuberculosis and syphilis are uncommon diagnoses in today's world. Nevertheless, these causes of chronic infection of the testis should not be forgotten.

Tumour

Most scrotal swellings are simple and benign in nature, but a solid mass raises the possibility of a tumour (Figure 3a). A patient with any sort of mass inside the testis needs urgent referral to a urologist for appropriate assessment. Ultrasound is helpful in making the diagnosis, and exploration is mandatory through an inguinal approach so that the spermatic

Table 3. Features of scrotal swellings in adolescence and adulthood

	Painful	Can get above	Transilluminable	Reducible	Surgery
Testicular torsion	Yes	Yes	No	No	Urgent
Tumour	No	Yes	No	No	Semi-urgent
Hydrocele	No	Yes	Yes	No	Elective
Epididymal cyst	No	Yes	Yes	No	Elective
Varicocele	No	Yes or no	No	Yes (supine)	Elective
Hernia	Yes or no	No (cough impulse)	No	Yes or no	Urgent if strangulated

Some scrotal swellings in adults

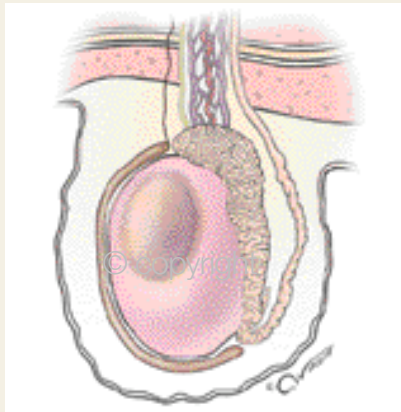


Figure 3a. Tumour.

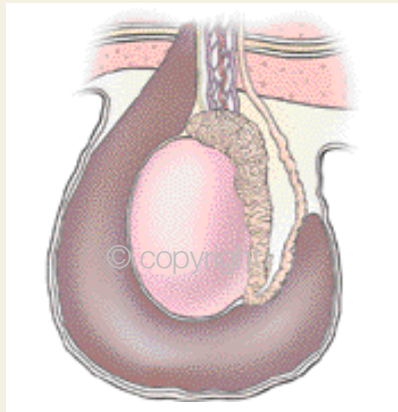


Figure 3b. Hydrocele.

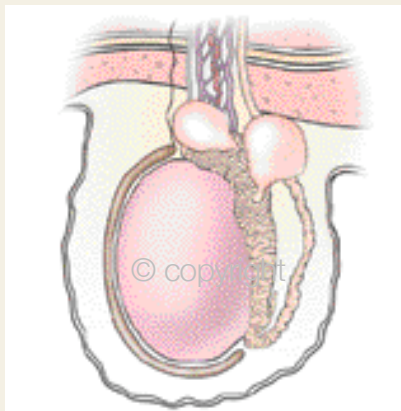


Figure 3c. Epididymal cysts.

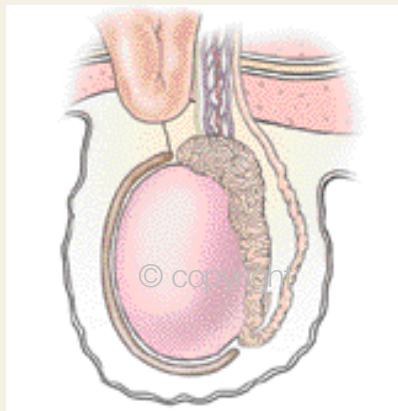


Figure 3d. Hernia.

© CHRIS WILKOFF, 2005

cord can be occluded to prevent possible tumour embolisation.

Hydrocele

A patient with a scrotal swelling that is cystic and testes that cannot be felt has a hydrocele (Figure 3b). Surgical correction is required for a hydrocele only if it is intrusive. Needle aspiration gives only temporary relief, at best, and can cause adhesions and infection, making subsequent surgical correction much more difficult.

Epididymal cysts

Epididymal cysts (or spermatoceles) typ-

ically sit above the testis and are often multiple in number (Figure 3c). They can always be felt distinctly separate to the testis.

Epididymal cysts need exploration and removal only when becoming obstructive or occasionally if causing pain. Surgery causes interruption of the sperm pathway, so fertility can be impaired. If both sides are explored then infertility can be absolute.

Hernia

A hernial mass is usually quite obvious in the inguinal region but can descend into the neck of the scrotum (Figure 3d). A

patient with a hernia should be referred for surgical repair because it is more likely to strangulate when the contents have entered the scrotum. Surgery is urgent if there is associated acute pain, and even more so if associated bowel obstruction is present.

Varicocele

Dilatation of the veins in the pampiniform plexus of the testis is due to deficient valves in the spermatic vein, almost always on the left side. On this side, the spermatic vein runs into the renal vein and there is a much greater chance of absent valves allowing reflux; on the right side, the spermatic vein runs into the inferior vena cava, which always has valves. About 15% of males have reflux causing a varicocele, but it rarely causes symptoms. Occasionally, however, a large varicocele can cause pain or discomfort, especially in overzealous sporty adolescents.

Varicoceles will often present during investigations for infertility – 30% of men being investigated in an infertile partnership are found to have a varicocele. It is still somewhat controversial as to whether cure of the varicocele improves sperm quality, but most infertility clinics advocate surgical correction. This prevents reflux of blood down the spermatic veins into the scrotum, and it is thought that the reduction in scrotal temperature improves sperm production.

When a varicocele is unsightly, large or painful, surgical treatment affords relief. Recurrence sometimes occurs after surgery because unknown perforators have been missed at the initial operation.

Final comments

As always, being alert to the possible diagnoses will enable a physician to implement the correct plan of management. On the whole, if a patient presents with scrotal pain then the problem is urgent and requires immediate resolution. **MT**

DECLARATION OF INTEREST: None.