

A guide to joint and soft tissue corticosteroid injection.

Part 2: sites other than the knee

ARVIN KUMAR DAMODARAN BSc, MB BS(Hons), FRACP

LES BARNSELY BMed(Hons), GradDipEpi, PhD, FRACP, FAFRM (RACP)

The performing of joint and soft tissue injections can be very rewarding for patients and interested doctors.

This article, the second in a two-part step by step guide for GPs interested in performing joint and soft tissue aspiration and corticosteroid injections, covers commonly performed injections at sites other than the knee. The first article, published in the June 2005 issue of *Medicine Today*, discussed important general considerations, with the knee used as an example because it is the site most commonly aspirated and the most studied for injection.¹

General considerations – a review

As mentioned in the first article, the main contraindication to corticosteroid injection is the presence of systemic or overlying infection. Aseptic technique, including adequate skin preparation and single use sterile equipment and drugs, is mandatory, and any one site should not be injected more than three or four times in a year.

As a general rule, injections should

never be given under pressure; if pressure is felt, the needle tip may be within a structure such as a tendon. Specific areas to avoid injecting include the Achilles tendon and flexor tendons of the hands, which are particularly prone to rupture, and any spinal region without imaging guidance.

Most importantly, although rare by any estimate (probably less than one in 10,000 injections), potentially catastrophic joint infection may occur following corticosteroid injection. Every patient needs to be informed of this possibility as part of the informed consent process, and to avoid delays in recognition and treatment.

Carpal tunnel injection

Indications

Carpal tunnel syndrome is very common, and symptoms range from mild and intermittent to severe with constant pain or weakness of the thumb and median nerve distribution sensory loss. The many causes include obesity, pregnancy, hypothyroidism, inflammatory arthritis and diabetes. Most cases are likely to respond to injections, fracture, but infection and carpal tunnel syndrome of pregnancy should be considered contraindications. Other treatment options that should be considered are oral anti-inflammatory agents, splinting and, ultimately, surgery. Extension splinting (in particular a nocturnal 'resting' wrist splint for night-time

symptoms) is often very useful either alone or with injection.

Evidence

A Cochrane review of randomised controlled trials concluded that local corticosteroid injection is effective in treating carpal tunnel syndrome, although symptom relief beyond one month has not been demonstrated.²

Anatomy

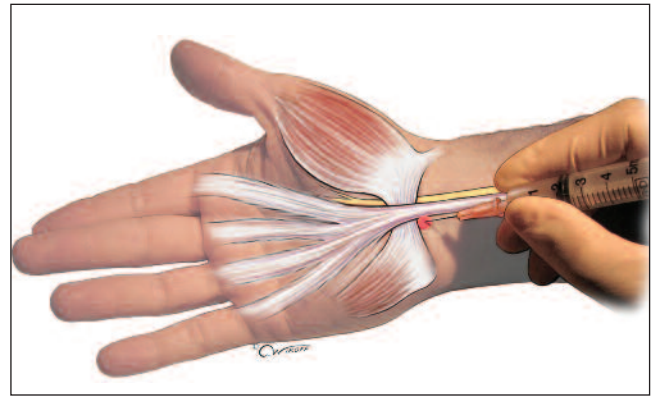
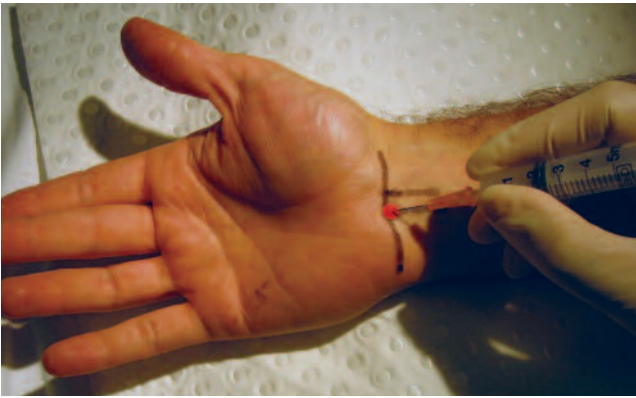The two useful surface landmarks are the distal palmar flexion crease and the palmaris longus tendon, which runs over the median nerve. The injection entry site is medial (ulnar) to palmaris longus through the crease, thus avoiding the branch of the median nerve on the radial side (Figures 1a and b). For the one in four people who lack a palmaris longus, use a point ulnar to the midline of the wrist through the distal flexion crease.

Technique

A small volume injection of 1 mL of corticosteroid preparation (either betamethasone [Celestone Chronodose] or methylprednisolone acetate [Depo-Medrol, Depo-Nisolone]) is used. Some authors recommend not mixing this with local anaesthetic because the proximity to the median nerve may result in transient numbness. If local anaesthetic is used, remember to warn the patient about this likely effect, and use 1 mL of 1% lignocaine (Lignocaine Hydrochloride Injection, Lignocaine Injection, Xylocaine Ampoules [Plain] Injection) to mix rather than a longer acting agent. As always, never use preparations that contain adrenaline in the extremities.

A 25 gauge needle is inserted at the site, aiming distally at a shallow angle (30 to 45°) with the bevel down. The depth of injection will vary according to the size of the patient but the flexor retinaculum is quite superficial and care should be taken not to penetrate deep structures. With the needle advanced

Dr Damodaran is a Staff Specialist in Rheumatology and Medical Registrar Education, Liverpool Hospital, Sydney, and Associate Professor Barnsley is Head, Department of Rheumatology, Concord Repatriation General Hospital, Sydney, and Associate Professor, Department of Medicine, University of Sydney, Sydney, NSW.



© CHRIS WIKOFF, 2005

Figures 1a and b. Carpal tunnel injection. a (left). Surface anatomy drawn on the skin. b (right). The injection site is ulnar to the palmaris longus tendon, under the carpal ligaments.

slowly, passage through the flexor retinaculum is marked by a loss of resistance. In any event, the needle should not be advanced for more than 1 cm of its length, at which time it should underlie the flexor retinaculum. Aspirate to ensure that the tip is not within a vessel, and then inject the corticosteroid preparation. There should be almost no resistance to injecting the fluid; if there is resistance, the needle should be repositioned before injecting, as the tip may lie within a tendon or nerve.

Lateral epicondylitis Indications

Lateral epicondylitis or tennis elbow is a common soft tissue overuse injury often associated with repetitive strain or sports. Patients experience lateral elbow pain with point tenderness over the lateral epicondyle that can be accentuated by resisted wrist extension and overhand lifting (lifting with the palm down).

The condition responds very well to injection in the short term, although there is some concern about increased recurrence in the medium to long term. In light of this, injection should probably be reserved for patients who have symptoms that are severe enough to prevent day-to-day functioning, who require rapid relief or who fail conservative treatment such as physiotherapy and strapping. Patients

should be informed that the condition is generally self-limiting in the long term and that injection, especially if overuse continues when the symptoms abate, may lead to recurrence.

Superficial soft tissue injections carry a higher risk of depigmentation and subcutaneous tissue atrophy, and patients should be specifically warned of this complication.

Evidence

A recent randomised controlled trial of 185 patients compared corticosteroid injection with physiotherapy or a wait and see policy.³ The study was conducted in a primary care setting with follow up over one year. The injection provided the most symptomatic relief at six weeks, with a success rate of over 90%. However, at 12 weeks and one year, the other groups were more successful, with injection associated with a higher rate of recurrence. Nevertheless, most patients in all groups had symptomatic resolution at the conclusion of the study.

Anatomy

The affected area is the insertion of the extensor carpi radialis brevis or common extensor origin at the lateral epicondyle. The procedure is most easily performed with the patient seated and the arm forwards and resting palm down on a table

with the elbow flexed at 90°. Palpate the prominence of the lateral epicondyle, and mark the point of maximal tenderness for insertion of the needle (Figure 2).

Technique

Draw up 0.5 to 1 mL of corticosteroid preparation (either betamethasone or methylprednisolone acetate) mixed with 1 to 2 mL of 1% lignocaine (which may be mixed with or replaced by 0.5% bupivacaine for longer acting anaesthesia). A 25 gauge needle is used to inject using a technique that has been called 'peppering'. Insert the needle at the marked point and inject a

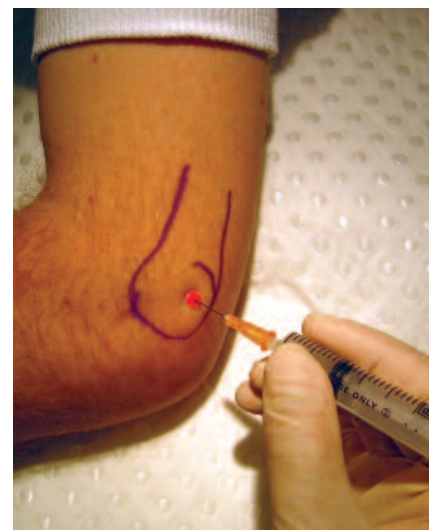

Figure 2. Lateral epicondylitis injection.

continued

small volume down onto the periosteum, withdraw the needle slightly, keeping the tip under the skin, and then fan out to 'pepper' the area three or four times. The injection is very superficial and care should be taken not to insert the needle too far. Typically, a small raised bleb of injected material will be visible.

Shoulder - subacromial space injection

Indications

Subacromial impingement syndrome is characterised by a painful arc on active abduction of the shoulder, with less or no pain on passive abduction, and relatively painless shoulder flexion until the last 10° of movement. The impingement may be due to or may cause rotator cuff tendonitis, subacromial bursitis or subdeltoid bursitis, or may be related to the shape of the bony structures, particularly the acromion.

Subacromial corticosteroid injection is often used for symptom relief but the benefit varies depending on the underlying rotator cuff or bony disease. The usual practice is to recommend concurrent

physiotherapy, especially exercises for increasing range of motion (to prevent the development of adhesive capsulitis) and for dynamic strengthening (to restore rotator cuff function).

X-ray of the shoulder should be performed when indicated on history, such as significant trauma, or symptoms are severe, refractory or atypical. This is to look for causes of possibly recurrent problems (for example, a subacromial bony spur) and to exclude uncommon but serious local pathology such as fracture or malignancy. Calcific tendonitis may also show on x-ray, and may be responsive to injection (imaging guidance can be helpful here).

Evidence

Corticosteroid injections for shoulder pain are also the subject of a Cochrane review.⁴ The limited studies available show that subacromial corticosteroid injection for rotator cuff disease is useful, although the effect may be modest and brief. A recent randomised controlled trial suggests considering an ultrasound guided injection to ensure accurate placement if

there is little effect from a 'blind' subacromial injection.⁵ As a general principle, using ultrasound guidance after a failed blind attempt can be a useful strategy for other joint and soft tissue injection or aspiration.

Anatomy

Have the patient sitting with the arm relaxed and hanging loosely. The spine of the scapula is a useful starting point for palpation, as it becomes the dish-like projection of the acromion laterally. The space between the humeral head and the acromion is wider 1 to 2 cm posterior to the lateral tip of the acromion. Mark this palpated gap as the entry point for injection (Figures 3a and b).

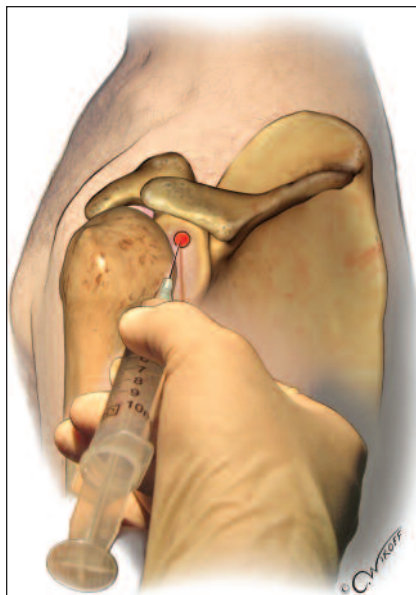
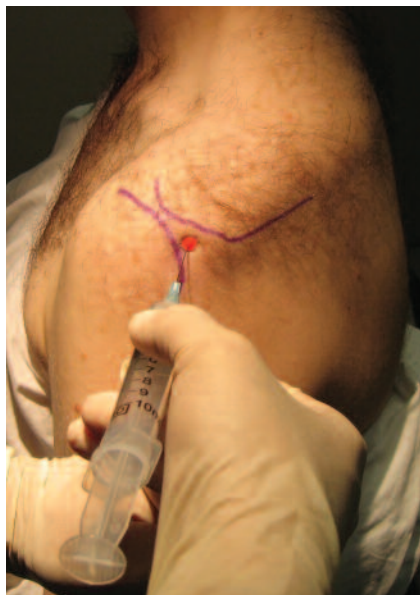Technique

Draw up 1 to 2 mL of corticosteroid mixed with 2 mL of local anaesthetic. The standard drugs are used (that is, betamethasone, methylprednisolone or triamcinolone (Kenocort-A 40), and lignocaine and/or bupivacaine, as discussed in Part 1).¹ A 1.5 inch (38 mm) 23 gauge needle is sufficient, although use of a 1.5 inch 25 or 27 gauge needle can result in less patient discomfort. From the marked entry point, aim the needle parallel to the undersurface of the acromion (slightly upwards) to its envisaged midpoint. An injection depth of 2 cm is usually enough, and injection without resistance helps confirm accurate placement.

Shoulder - glenohumeral joint injection

Indications

In acute arthritis with effusion, the glenohumeral joint is injected with both diagnostic and therapeutic intent. In nonseptic inflammatory arthritis, early adhesive capsulitis/frozen shoulder and symptomatic osteoarthritis, pain relief is the intent. The anterior approach is the most likely to yield synovial fluid if an effusion is detected, so it is the preferred approach for a diagnostic aspirate. If only



© CHRIS WIKOFF, 2005

Figures 3a and b. Subacromial injection. a (left). Surface anatomy drawn on the skin. b (right). The needle is advanced under the posterior lateral acromial edge.

corticosteroid injection is required then the posterior approach is generally used as it tends to be more straightforward.

Evidence

Systematic review of the literature for corticosteroid injection for adhesive capsulitis indicates limited and short term benefit, although the heterogeneity of the studies with respect to routes and dosages make interpretation difficult.⁴ The most convincing randomised controlled trial used 40 mg of triamcinolone injected with a posterior glenohumeral approach up to three times over six weeks, compared with physiotherapy in 109 patients with unilateral painful stiff shoulders ('capsular syndrome').⁶ Care was taken to exclude shoulder pain due to other causes, and trained GPs performed the injections. In this study, there was clear advantage of injection therapy at seven weeks, although there was little difference between groups at 26 and 52 weeks, suggesting that corticosteroid injection may provide faster improvement in the painful stiff shoulder but does not alter the long term outlook.

Anterior approach

Anatomy

The anterior glenohumeral approach is easiest with the patient reclined at 45° or sitting upright, with the arm hanging, the elbow flexed to 90° and the shoulder neutrally rotated so that the forearm faces forward. The important surface landmark is the coracoid process, which will be palpable medial to the superior humeral head and below the distal clavicle. Mark a point 1 cm below and 1 cm lateral (this is important as moving medial rather than lateral would risk pneumothorax), to the coracoid process for the insertion point (Figure 4).

Technique

A preceding infiltration of local anaesthetic (1% lignocaine) can be helpful when a larger needle is used or the operator is

not confident of being able to readily access the joint. For corticosteroid injection, use 1 to 2 mL of corticosteroid preparation mixed with 2 to 3 mL of 1% lignocaine. The drugs are the same as used for subacromial injection. Although a 23 gauge needle will usually be adequate for aspiration, a 21 gauge or larger needle may be required when large volumes of aspirate or thick fluid such as blood are anticipated.

The needle is aimed directly posteriorly and will advance through the joint capsule, which may be quite superficial if the effusion is large. Aspiration as the needle advances may yield synovial fluid early, in which case there is no need to advance further. Otherwise, continue to advance the needle until it is at full depth or the humeral head is touched. Gentle internal rotation as the needle is advanced can carry the tip into the glenohumeral joint space.

Posterior approach

Anatomy

The patient sits upright facing away for the posterior approach. The main landmark is the lateral tip of the spine of scapula where it forms a prominence on the inferior margin and meets the posterior

corner of the acromion. The needle entry point is 1 cm down and 1 cm medial to this landmark (Figure 5).

Technique

Usually a 23 gauge needle is sufficient for injection, and the same drugs are used as for the anterior approach. As with many deeper injections, it is helpful to use a syringe with 1 or 2 mL of local anaesthetic to anaesthetise in front of the advancing needle, before changing to a syringe barrel containing the corticosteroid and local anaesthetic mixture. The needle is aimed anteriorly towards the coracoid process and is advanced until either the full depth of the needle or bone is reached (see Figure 5). Aspiration and injection without resistance help confirm accurate placement.

Trochanteric bursitis

Indications

Greater trochanter pain syndrome, more commonly called trochanteric bursitis although the pathology is often due to degenerative tendon pathology of the gluteus medius and minimus muscles (or 'gluteal enthesitis'), is an exceedingly common problem in both primary care and specialist rooms. Characteristically there is pain around the lateral aspect of the hip although it may radiate to the upper buttock or down the lateral thigh to the knee. Typically, pain prevents the patient from sleeping on the affected side, and hip movements may be painful although walking may be relatively painless. The diagnosis is confirmed clinically by precipitating marked tenderness localised over the greater trochanter.

Corticosteroid injection is very effective at providing symptom relief. The problem, however, is likely to be recurrent if the underlying cause, such as a tight ilio-tibial band, abnormal gait, back pain or leg length inequality, is not addressed.

Evidence

There are good observational data that

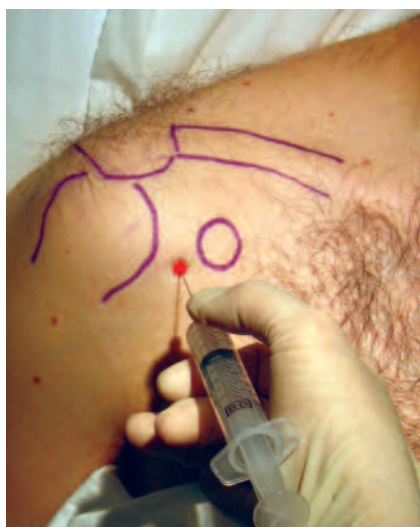

Figure 4. Glenohumeral joint injection, anterior approach.

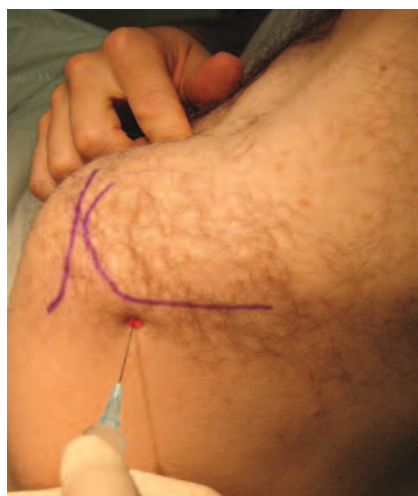

Figure 5. Glenohumeral joint injection, posterior approach. The patient's index finger indicates the coracoid process.

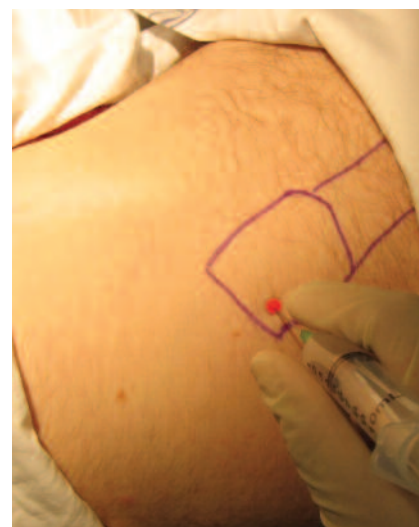


Figure 6. Trochanteric bursitis injection.

indicate injection can provide both acute and long term (26 weeks) relief, although there is a substantial recurrence rate.⁷ In this particular series, patients receiving higher doses of betamethasone did significantly better.

Anatomy

Bursitis and tendonosis may give rise to identical pain, and the conservative treatment options are the same. MRI often demonstrates degenerative changes affecting the gluteus minimus or medius tendons that insert onto the greater trochanter. The two most important of the several bursae in the greater trochanter region are the subgluteus medius bursa, which lies over the superior-posterior margin of the greater trochanter, and the subgluteus maximus bursa, which separates the greater trochanter and gluteus medius insertion from the structures of the iliotibial tract.

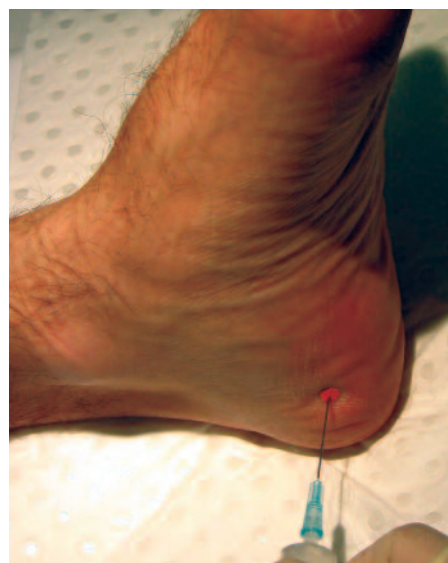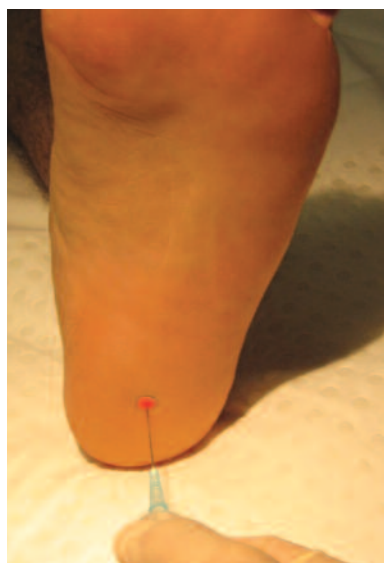
With the patient lying on the unaffected side and the hips flexed to around 45°, the greater trochanter is palpated for the point of maximal tenderness, often the superior-posterior quadrant. This is marked as the needle entry point (Figure 6). Poorly localised tenderness may indi-

cate an alternative diagnosis, although greater trochanter pain syndrome often accompanies other mechanical problems of the lower back and leg.

Technique

One of the common pitfalls in trochanteric bursitis injection is using too short a needle. This injection is most effective if given just over the periosteum, so a

standard 23 or 21 gauge needle may not be long enough. In the larger patient, a longer 21 gauge needle or spinal needle can be used. Draw up 1 mL of corticosteroid preparation (betamethasone or methylprednisolone acetate) mixed with 5 to 8 mL of local anaesthetic. The needle is directed straight down onto the point of maximal tenderness until bone is reached. Injection may meet with some resistance,



Figures 7a and b. Plantar fasciitis injection. a (left). Direct approach. b (right). Medial approach.

which can be overcome by withdrawing the needle 1 or 2 mm. About half the volume is deposited here and the remainder widely fanned out with a technique similar to injecting for lateral epicondylitis. Pressure over the area after injecting may help to distribute the mixture in the deeper tissues and prevent it from tracking superficially.

Plantar fasciitis

Indications

Plantar fasciitis is the most common cause of pain in the inferior heel, and can be chronic and disabling. However, the overall prognosis is good, with over 80% of cases resolving within a year.⁸ Injection can be considered in particularly severe or refractory cases that have failed conventional therapy, including weight loss, soft heel cups and stretching exercises for the plantar fascia and calf muscles.

Evidence

There is some evidence that corticosteroid injection using the medial approach is useful in the short term, although randomised controlled trial data are very limited on any of the approaches to this troubling problem.⁸

Anatomy

The usual role of the plantar fascia is to constitute the arch while the foot rolls forwards in walking. Pain is thought to arise from the narrow attachment of the fascia to the medial calcaneal tuberosity, a structure prone to repetitive microtrauma. Pain may also arise due to inflammation in patients with an underlying spondyloarthropathy. Deep palpation over the heel pad will reveal a point of maximal tenderness that can be marked for direct injection or as a guide when using the medial approach.

Technique

A 21 or 23 gauge needle is used to inject 0.5 to 1 mL of corticosteroid (betamethasone or methylprednisolone acetate) mixed with 2 to 3 mL of local anaesthetic for both the direct and the medial approaches. Preceding infiltration with local anaesthetic is of benefit.

In the direct approach, aim directly down from the plantar surface at the point of maximal tenderness and inject onto the periosteum, then 'pepper' as with the lateral epicondylitis injection (Figure 7a). In the medial approach, the needle is inserted from the medial side approximately 2 cm deep to and parallel to the undersurface of the heel (Figure 7b). The needle tip is directed deep to the point of maximal tenderness, which should correspond to the insertion region of medial calcaneal tuberosity. This is the only injection in which significant

pressure may be required to inject the mixture. The direct approach may have the advantage in accuracy, while the medial approach is usually less painful.

Of all joint and soft tissue injections, plantar fasciitis injection has the reputation of being the most painful. The patient should be made aware of this and the favourable natural history as part of the consenting process.

Conclusion

In this short series we have endeavoured to provide a concise guide to common joint and soft tissue injections specifically tailored to interested GPs. We have incorporated evidence where it is available. These simple procedures can be rewarding for patient and doctor, and have a low risk of complications provided contraindications are avoided, the practitioner has a sound knowledge of the

relevant anatomy and routine aseptic precautions are taken. **MT**

References

1. Damodaran AK, Barnsley L. A guide to joint and soft tissue corticosteroid injection. Part 1: general principles and the knee. *Medicine Today* 2005; 6(6): 59-64.
2. Marshall S, Tardif G, Ashworth N. Local corticosteroid injection for carpal tunnel syndrome (Cochrane review). *The Cochrane Database of Systematic Reviews* 2002, Issue 4. Art. No.: CD001554. DOI: 10.1002/14651858.CD001554.
3. Smidt N, van der Windt DA, Assensdelft WJ, Deville WLW, Korthals-de Bos IB, Bouter LM. Corticosteroid injections, physiotherapy, or a wait-and-see policy for lateral epicondylitis: a randomised controlled trial. *Lancet* 2002; 359: 657-662.
4. Buchbinder R, Green S, Youd JM. Corticosteroid injections for shoulder pain (Cochrane review). *The Cochrane Database of Systematic Reviews* 2003, Issue 1. Art. No.: CD004016. DOI: 10.1002/14651858.CD004016.
5. Naredo E, Cabero F, Beneyto P, et al. A randomized comparative study of short term response to blind injection versus sonographic-guided injection of local corticosteroids in patients with painful shoulder. *J Rheumatol* 2004; 31: 308-314.
6. van der Windt DA, Koes BW, Deville W, Boeke AJ, de Jong BA, Bouter LM. Effectiveness of corticosteroid injections versus physiotherapy for treatment of painful stiff shoulder in primary care: randomised trial. *BMJ* 1998; 317: 1292-1296.
7. Shbeeb M I, O'Duffy JD, Michet CJ Jr, O'Fallon WM, Matteson EL. Evaluation of glucocorticosteroid injection for the treatment of trochanteric bursitis. *J Rheumatol* 1996; 23: 2104-2106.
8. Buchbinder R. Clinical practice. Plantar fasciitis. *N Engl J Med* 2004; 350: 2159-2166.

DECLARATION OF INTEREST: None.