Malaria – a case of vivax

JONATHAN COHEN MB BS, FRACGP, MFM, FACTM

The following case highlights several points that should be remembered when advising patients travelling to, or returning from, malarious areas.

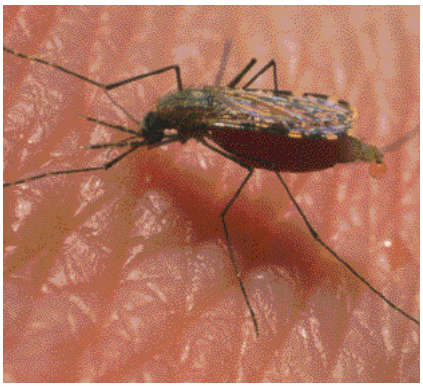

SINCLAIR STAMMERS, SCIENCE PHOTO LIBRARY

Figure. Mosquito bite avoidance and chemoprophylaxis reduce the risk of contracting malaria.

Case study

First visit, three months before travel

A 13-year-old boy presented for the first time for pretravel health advice three months before a school excursion to Papua New Guinea (PNG). For two weeks he would be living in a hut in a rural village about two hours from the north coast and at an altitude of roughly 1200 m. He had a past medical history of benign focal childhood epilepsy and varicella. Otherwise he was in good health and general examination was unremarkable. His standard polio, measles–mumps–rubella and meningococcal C vaccinations were reported to be up to date according to NHMRC recommendations and he had had a tetanus–diphtheria–pertussis vaccination three years previously.

Following a discussion with the boy and his mother of the risks and benefits, he was vaccinated against hepatitis A and B and typhoid, and given appropriate tablets for malaria prophylaxis. He was given to take on the excursion oral rehydration solution, first aid items, 19% *N,N*-diethyl-3-methylbenzamide (DEET)-containing repellent, a permethrin impregnation kit for clothing and a permethrin impregnated mosquito net.

Second visit, four days after return

The boy presented four days after his return from PNG complaining of a one-week history of acute diarrhoeal illness with abdominal pains and malaise but no fever, sweating or other symptoms. He noted that most of the other 16 members of his group had also suffered from gastrointestinal symptoms at varying stages during the trip.

Examination was unremarkable, including the absence of fever. Nonetheless, in view of the need to exclude malaria, a full blood examination and erythrocyte sedimentation rate were requested, along with a thick and thin blood film and immunochromatographic serology for malaria antigens.

All the test results were normal, and the patient's symptoms resolved quickly. He stated that he had lost his antimalarial tablets, so these were replaced at this time.

Third visit, three months after return

The boy presented again 12 weeks later with an acute diarrhoeal illness, but again no fever. Thick and thin blood films for malaria and serology were again normal; however, faecal stool culture demonstrated *Blastocystis hominis* and *Endolimax nana*. Some medical microbiologists regard these organisms as commensal faecal protozoans, and so may not report their presence. However, if significant symptoms are present, most clinicians prescribe a course of metronidazole (Flagyl, Metrogyl, Metronide), which was done in this instance.

Fourth visit, hospital admission

One week later, the boy's mother phoned to say her son was extremely unwell with severe abdominal cramps, diarrhoea and vomiting, in addition to being febrile and unable to tolerate anything orally.

On presentation the boy was found to be extremely unwell, lethargic, dehydrated, febrile and mildly hypotensive, but he had no localising signs. Blood was taken for a (third) malaria film. He was immediately admitted to a local hospital under the care of a specialist gastrointestinal physician, who rehydrated him and requested a (fourth) thick and thin blood film. This time the film confirmed *Plasmodium vivax* malaria, and the boy was subsequently treated with chloroquine (Chlorquin).

To eradicate liver forms of malaria, primaquine (Primacin) treatment was proposed; however, before initiating this medication, glucose-6-phosphate dehydrogenase (G6PD) deficiency testing was undertaken. Unfortunately, the boy was G6PD deficient, raising concerns about contraindications to treatment and the resultant possibility that he might experience long standing relapses of vivax malaria and not achieve a complete cure.

The pathologist who performed the blood smear raised concerns about the number of cases of malaria presenting in school children travelling to malarious areas and suggested that the school consider both legal aspects of informed consent and taking excursions to another country. The parents and their friends raised concerns about whether to take part in future school excursions to PNG, or anywhere for that matter. The school became worried about the impact of this on its future planned excursions. The initial treating physician wondered why the diagnosis had been missed for so long.

Dr Cohen is Senior Lecturer, Department of General Practice, Monash University, and Medical Director, Travel Clinics Australia, Melbourne, Vic.

Downloaded for personal use only. No other uses permitted without permission. © MedicineToday 2005.

Table 1. Four main principles of malaria protection[1]

- **A**wareness of risk, incubation of disease, symptoms
- **B**ite avoidance measures against mosquitoes, especially from dusk to dawn
- **C**hemoprophylaxis when appropriate
- **D**iagnosis and treatment should be sought if fever develops from one week after entering a malarious area to three months (or longer) after departure

The patient expressed his intent to return to PNG for the next planned school excursion.

Discussion

Malaria is a relatively common travel risk

Malaria is one of the world's most common infectious diseases; over 300 million cases and one million deaths are reported annually and it is endemic in roughly 100 countries.[1] Despite the presumed widespread knowledge about malaria prevention, each year many hundreds of travellers returning to Australia are treated for this disease, with notifications of cases in 2005 being significantly higher than average.[2]

Of the worldwide total of 10,000 cases of malaria in returned travellers each year, 10% are in those returning to Australia, with PNG being the source of about half of these.[2] The risk of malaria is known to be higher in rural areas, and cases are regularly reported from altitudes at which mosquitoes theoretically are not supposed to live. In this particular trip, the high risk is emphasised by the finding that three out of the 16 students (19%) developed vivax malaria.

No preventive strategy is 100% effective

It is simply not possible to prevent every mosquito bite regardless of the type or amount of repellent, insecticide or mosquito net used. Although bite avoidance measures may be discussed in the consultation room, it is another thing entirely to be able to put these into practice. In addition, adherence to medication schedules, especially on a daily basis, is not always feasible. Misplacement of antimalarial tablets by the patient in the above case is another example of a real life complication.

In providing travel health advice, it is important to consider carefully the preference of each traveller and likelihood of him or her adhering correctly to the proposed course of chemoprophylaxis. Relative terms such as 'avoidance' and 'risk reduction' should be used rather than terms implying absolute protection. It is also important to remember that currently available chemoprophylaxis for malaria targets *Plasmodium falciparum* malaria, the form most likely to be life-threatening, rather than the less fatal but more symptomatic *P. vivax, Plasmodium ovale* and *Plasmodium malariae* forms. No prophylaxis offers 100% protection against malaria, but the risk of infection will be markedly reduced if some is used. Table 1 lists the WHO's four recommended principles of malaria protection.

Suspect malaria in any returned traveller with fever

The classical clinical presentation of malaria includes high fever, rigours, pain, nausea and intense sweating. However, symptoms can vary widely, present atypically with diarrhoea and mimic other conditions such as travellers' diarrhoea, as occurred in this case. Falciparum malaria can progress quickly and is the main cause of mortality from malaria; however, vivax (the next most common form worldwide), ovale and malariae may still cause debilitating disease and death. It is wise to retain the maxim, 'suspect malaria in any traveller with fever from seven days to at least three months after leaving an endemic area', even if the traveller has used the correct antimalarial prophylaxis.

According to a study that was presented recently at the Conference of the International Society of Travel Medicine, 64% of returned travellers with malaria had falciparum malaria and 28% vivax (most of these travellers had returned from West Africa).[3] Most of these travellers (92%) developed symptoms after travel, with the onset of illness occurring less than four weeks after returning in 80% of those with falciparum malaria and 40% in those with vivax.

More than one form of malaria may be present at the same time (e.g. falciparum

Table 2. Treatment of vivax, malariae and ovale malaria[7]

- Before treatment, test patients for G6PD deficiency, and seek expert advice if this deficiency is present.
- Treat patients with chloroquine (children: 10 mg base/kg up to) 620 mg base (4 tablets) orally, initially, then (children: 5 mg base/kg up to) 310 mg (2 tablets) 6 hours later and on days 2 and 3.
- To eliminate liver forms of *Plasmodium vivax* infections acquired in South East Asia or the Pacific Islands, add or follow within a few days with primaquine (children: 0.5 mg/kg up to) 30 mg orally, daily with food, or if nausea occurs (children: 0.25 mg/kg up to) 15 mg orally, 12 hourly for 14 days.
- For *P. vivax* infections acquired outside South-East Asia and the Pacific Islands and for *Plasmodium ovale* infection, a lower primaquine dose can be used: primaquine (children: 0.3 mg/kg up to) 15 mg orally, daily for 14 days.

Downloaded for personal use only. No other uses permitted without permission. © MedicineToday 2005.

and vivax), and malaria may be present with concomitant disease such as gastrointestinal infection, which may delay diagnosis (as occurred in this case).

Vivax is not benign

Vivax is not often discussed, yet it is more common in Australia than other forms of malaria, as exemplified by a recent West Australian study that showed that 58% of cases seen over a decade were due to *P. vivax* compared with 28% due to *P. falciparum*.[4] Vivax may be associated with severe rigours, anaemia, respiratory distress, renal failure, complications in pregnancy, cerebral malaria, and splenomegaly with rupture, and has a low but real mortality rate. Its incubation period is at least eight days, and liver forms may be difficult to eradicate and can result in patients having relapses of the disease for decades. It has been reported that chloroquine treatment failure is emerging in cases of vivax malaria in Asia and notably in PNG.[5]

Repeated thick and thin blood films are needed

This case emphasises the many difficulties in the diagnosis of malaria. Despite many advances in technology, such as PCR techniques, commercial laboratory diagnosis today still rests on repeated thick and thin blood films being examined by experienced haematologists. If one film is clear yet malaria suspected, the test must be repeated at least twice more. The immunochromatographic card test used in many Australian laboratories is relatively sensitive to falciparum malaria, but markedly less so to vivax and ovale. One indicator of vivax on the full blood examination is a lowered platelet count, often an early signal of more severe and extreme disease.

Practitioners requesting thick and thin blood films must ensure they provide the pathologist with details of the suspected country of origin and, if possible, the form of suspected malaria. Depending on the expertise of the haematologist, the films may be sent to a reference laboratory for confirmation.

Exclude G6PD deficiency before prescribing primaquine

Primaquine treatment is necessary to clear exoerythrocytic vivax malaria, including that in the liver, and higher doses are becoming necessary for treatment of malaria in travellers from PNG and other areas (Table 2). G6PD deficiency, one of the most common known inherited metabolic errors, should be excluded before initiating treatment. Primaquine can induce the formation of a toxic level of methaemoglobin and haemolytic anaemia. There is limited evidence that lower doses of primaquine may be used on a weekly basis for the less severe forms of G6PD deficiency, with close monitoring of the blood for haemolysis.[6]

Tafenoquine is a newer, long acting, alternative, but it is not yet available in Australia and has similar limitations.

Consider issues of informed consent

In a case such as this, the issue of informed consent needs to be raised. To what extent does any group organising trips to high risk destinations have an obligation to fully inform its members about not only short term risks but also long term risks? It may prove impossible to fully eradicate vivax in this boy because he has G6PD deficiency complicating adequate treatment with primaquine. Can students of this age fully comprehend this sort of long term risk? Is a rate of infection of 19% an 'acceptable' risk, given that all prophylactic measures were instituted under supervision?

Being aware of this risk begs the question of whether a traveller needs to go to the highest risk areas if alternative destinations are available. Of course, conversely, it could be argued that exposing western school children to alternative cultures for broad educational purposes is so important that it justifies the risk of exposure to potentially preventable disease. As one parent put it, 'there is risk everywhere – you could go to London and get blown up' or '…be in a car accident here'.

Summary

Advice on malaria, including prevention and treatment, is readily available from numerous sources.[1,7,8] Provision of malaria prophylaxis and treatment advice that is relevant for specific areas visited by travellers is becoming increasingly complex. For this reason, most authorities now recommend that for more complex situations, or if unsure, GPs should refer travellers to a travel clinic or medical practitioner well versed in this field. MT

References

1. WHO. Malaria. In: International travel and health. Geneva: WHO; 2005, ch 7, p. 132-151. Available from http://www.who.int/ith/en/
2. Communicable Diseases Australia. National notifiable diseases surveillance system [online]. Available from http://www1.health.gov.au/cda/Source/CDA-index.cfm
3. Cañas García-Otero E, Haro González JL, Ruiz Pipaón M, et al. Imported malaria: report of 25 cases from a single institution [abstract PO01.06]. 9th Conference of the International Society of Travel Medicine, Lisbon Portugal, May 2005. Available from http://193.97.204.182/cistm9/index.html
4. Charles DM, Hart J, Davis WA, et al. Notifications of imported malaria in Western Australia, 1990-2001: incidence, associated factors and chemoprophylaxis. Med J Aust 2005; 182: 164-167.
5. Communicable Diseases Australia. Malaria – Papua New Guinea (Southern Highlands). Overseas briefs. Commun Dis Intell 2004; 28: 560.
6. Davis TME. Malaria treatment [online]. Available from http://www.rph.wa.gov.au/labs/ haem/malaria/treatment.html
7. Cohen J. The travellers pocket medical guide and international certificate of vaccination, 5th ed. Melbourne: Travel Clinics Australia; 2005.
8. Therapeutic guidelines: antibiotic, 12th ed. Melbourne: Therapeutic Guidelines Limited; 2003.

DECLARATION OF INTEREST. Dr Cohen is Medical Director, Travel Clinics Australia.

Downloaded for personal use only. No other uses permitted without permission. © MedicineToday 2005.