

Hoarseness

a guide to voice disorders

Hoarseness is usually associated with an upper respiratory tract infection or voice overuse and will resolve spontaneously. In other situations, treatment often requires collaboration between GP, ENT surgeon and speech pathologist.

RON BOVA

MB BS, MS, FRACS

JOHN MCGUINNESS

FRCS, FDS RCS

Dr Bova is an ENT, Head and Neck Surgeon and Dr McGuinness is ENT Fellow, St Vincent's Hospital, Sydney, NSW.

Voice disorders are common and attributable to a wide range of structural, medical and behavioural conditions. Dysphonia (hoarseness) refers to altered voice due to a laryngeal disorder and may be described as raspy, gravelly or breathy. Intermittent dysphonia is normally always secondary to a benign disorder, but constant or progressive dysphonia should always alert the GP to the possibility of malignancy. As a general rule, a patient with persistent dysphonia lasting more than three to four weeks warrants referral for complete otolaryngology assessment. This is particularly pertinent for patients with persisting hoarseness who are at high risk for laryngeal cancer through smoking or excessive alcohol intake, and for patients with a family history or personal history of head and neck cancer.

The mechanism of voice production is described in the box on page 39.

Inflammatory causes of voice dysfunction**Acute laryngitis**

Acute laryngitis causes hoarseness that can result in complete voice loss. The most common cause is viral upper respiratory tract infection; other causes include exposure to tobacco smoke and a short period of vocal overuse such as shouting or singing. The vocal cords become oedematous with engorgement of submucosal blood vessels (Figure 3).

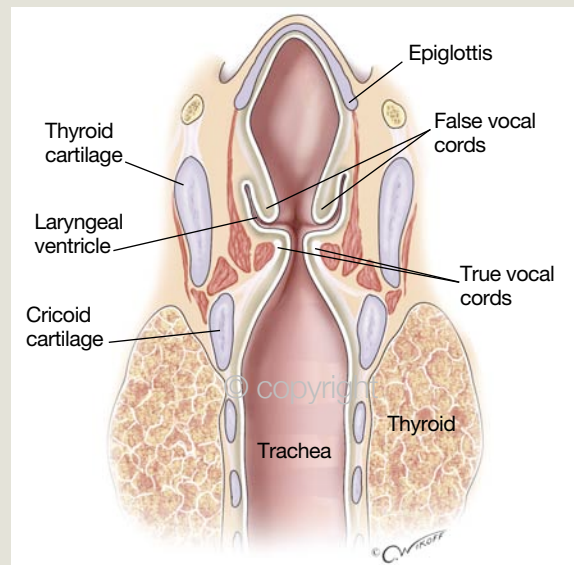
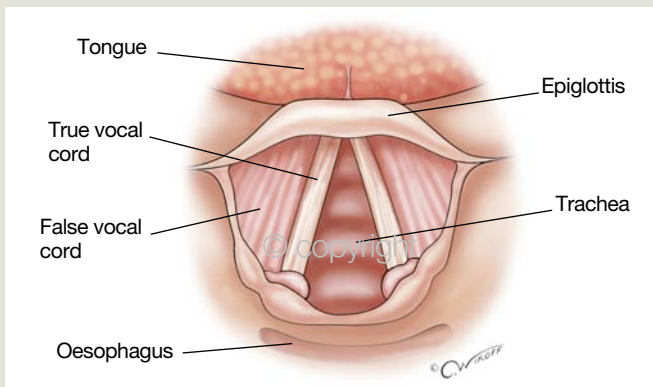
Treatment is supportive and aims to maximise vocal hygiene (Table), which includes adequate hydration, a period of voice rest and minimised exposure to irritants. Antibiotics are not indicated if a viral infection is suspected, and corticosteroids are rarely indicated for this common condition. Effortful speaking or singing during an acute attack of laryngitis may lead to vocal cord haemorrhage

IN SUMMARY

- Intermittent dysphonia is usually always secondary to a benign disorder. Constant or progressive dysphonia should always alert the GP to the possibility of malignancy.
- Radiological investigations such as CT scans miss the majority of vocal cord lesions. Flexible endoscopic nasolaryngeal examination is the most sensitive investigatory tool.
- Treatment for chronic laryngitis due to laryngopharyngeal reflux is an eight- to 12-week empirical course of a proton pump inhibitor as well as dietary and lifestyle modification.
- Muscle tension dysphonia is a common cause of hoarseness and results from excessive and unnecessary tension of laryngeal muscles during phonation. Speech therapy is the cornerstone of management.
- A patient presenting with persisting hoarseness who is at high risk of laryngeal malignancy through smoking, excessive alcohol intake or a history of head and neck cancer should be referred for early specialist assessment.

How is voice produced?

Voice production is a complex process requiring co-ordination between the lungs, larynx, pharynx and oral cavity. The lungs act like a power source, blowing expired air up through the vocal cords in the larynx (Figures 1a and b). The vocal cords vibrate hundreds of times per second, producing sound, the resonance of which is modified by muscular activity in the pharynx and oral cavity. Normal voice requires functioning vocal cords that are lined by smooth, well hydrated epithelium (Figure 2). Even the slightest alteration in vocal cord structure can result in hoarseness.



FIGURES 1A AND 1B © CHRIS WIKOFF, 2007

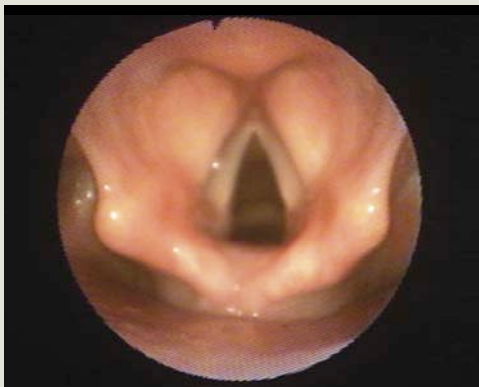

Figure 1a (top left). Laryngeal structures as seen from above during examination.

Figure 1b (top right). Coronal section through the larynx. Note the true vocal cords are separated by a space (laryngeal ventricle) from folds of supraglottic tissue (false vocal cords).

Figure 2 (left). Typical view obtained of a normal larynx using a flexible nasendoscope. The vocal cords are pale, smooth and easily visualised.

or formation of a haemorrhagic polyp. This is particularly relevant for a singer or other professional voice user who attempts to resume pre-laryngitis vocal demands too early.

Chronic laryngitis

Chronic laryngitis (chronic inflammation of the laryngeal mucosa) often impairs mucociliary transport, such that mucus that would normally be transported efficiently into the pharynx and swallowed may collect in the back of the larynx and pharynx. Symptoms are varied and include:

- hoarseness, which often comes and goes
- vocal fatigue, especially towards the end of the day

- a feeling of throat irritation or dryness
- mild throat discomfort with speaking and swallowing
- chronic cough, often with severe bouts of laryngospasm where there is a choking sensation; patients may describe it as an inability to get their breath
- sensation of postnasal drip with chronic throat clearing and a feeling of retained mucus in the back of the throat
- sensation of a lump in the throat.

Chronic laryngitis can be caused by multiple irritants, including:

- tobacco smoke
- environmental or occupational pollutants

continued

Table. Measures to improve vocal hygiene

- A period of voice rest, especially for acute laryngitis
- Hydration with noncaffeinated drinks, especially during periods of heavy voice use
- Limiting of vocal loudness (e.g. use of a microphone for teaching or public speaking)
- Avoidance of habitual and frequent throat clearing
- Avoidance of irritants, including passive smoking
- Humidified environment (e.g. use of menthol or eucalyptus inhalations)
- Avoidance of medications that have an anticholinergic drying effect
- Not smoking
- Speech therapy or vocal training, especially for professional voice users

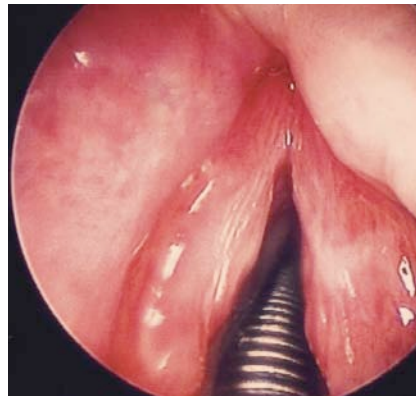


Figure 3. Acute laryngitis.

- laryngopharyngeal reflux (this is described in the box below).
- fungal laryngeal infection, which mainly occurs in immunosuppressed patients but may also be seen in patients taking inhaled corticosteroids
- systemic autoimmune causes such as Wegener’s granulomatosis, amyloidosis, systemic lupus erythematosus and relapsing polychondritis, which are extremely rare.

Benign lesions of the vocal cords

Vocal cord nodules

Vocal cord nodules are small, fibrous, bilateral swellings that develop on the anterior vocal cords as a result of excessive voice use (Figure 5). They are analogous to calluses and frequently found in singers and children who shout excessively. Patients complain of fluctuating hoarseness, often associated with intermittent sudden changes in vocal pitch. Voice therapy usually causes the nodules to regress. Persistent symptomatic nodules may be treated with microsurgical excision.

Vocal cord polyps

Vocal cord polyps are unilateral pedunculated lesions that commonly occur in men with a history of voice abuse and heavy smoking (Figure 6). The aetiology is unknown but the polyps are often very vascular, which makes repeated trauma a probable causative factor. Microsurgical excision is nearly always required for both diagnostic and therapeutic purposes.

Laryngopharyngeal reflux and chronic laryngitis

Laryngopharyngeal reflux, which occurs when acid refluxes through an incompetent upper oesophageal sphincter and irritates the larynx, is a common cause of chronic laryngitis. Even small amounts of acid reflux can cause minor laryngeal oedema resulting in hoarseness in addition to the other symptoms of chronic laryngitis, especially chronic throat mucus clearing and dry cough. Despite having concurrent gastro-oesophageal reflux disease (GORD) due to lower oesophageal sphincter dysfunction, patients may not complain of heartburn or chest pain

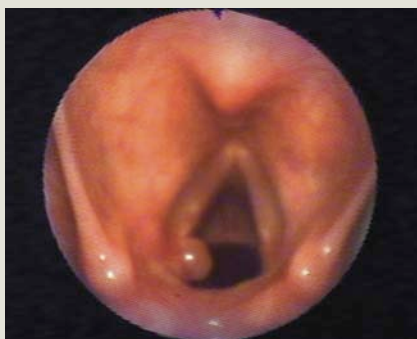

Figure 4. Reflux induced granuloma of the left posterior vocal cord. This lesion and the patient’s symptoms resolved with antireflux therapy.

because the oesophageal mucosa is much more resistant to small quantities of acid reflux. A classic feature of severe laryngopharyngeal reflux is granulation tissue overlying the posterior vocal cord but this is relatively uncommon; a reflux granuloma is shown in Figure 4.

Treatment for chronic laryngitis due to laryngopharyngeal reflux is an eight- to 12-week empirical course of a proton pump inhibitor as well as dietary and lifestyle modification, including elevation of the head of the bed. Speech therapy is useful, especially for patients with reflux granulomas, and aims to modify vocal cord closure patterns to minimise contact trauma between the posterior cords. Microsurgical removal is sometimes required for granulomas that are large or refractory to conservative measures. A relatively new treatment for stubborn granulomas involves paralysing the affected vocal cord by injecting botulinum toxin type A (Botox, Dysport). This minimises phonatory trauma and allows the granuloma to resolve, but severe breathy dysphonia lasting months is unavoidable.

Patients with severe or persistent reflux symptoms refractory to medical management may require comprehensive evaluation by a gastroenterologist.

continued

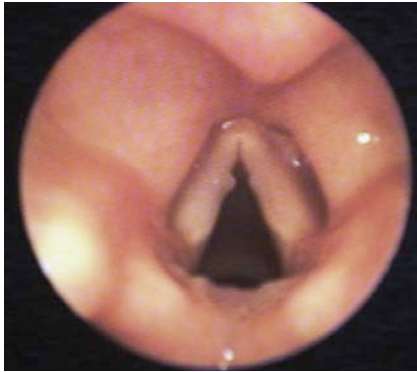

Figure 5. Vocal cord nodules in an amateur singer.

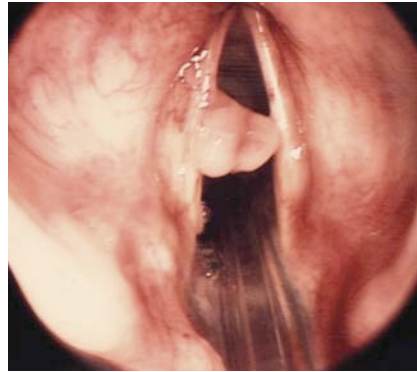


Figure 6. A vocal cord polyp in a young healthy man just prior to microsurgical excision.

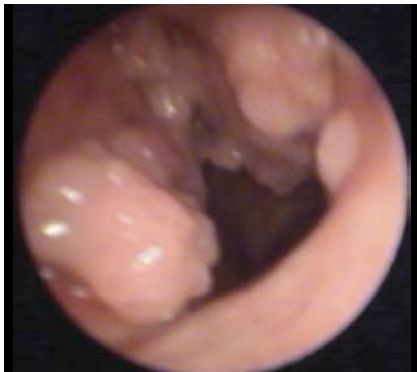


Figure 7. Severe diffuse laryngeal papillomatosis obscuring and affecting the entire supraglottic larynx. This patient presented with severe hoarseness.

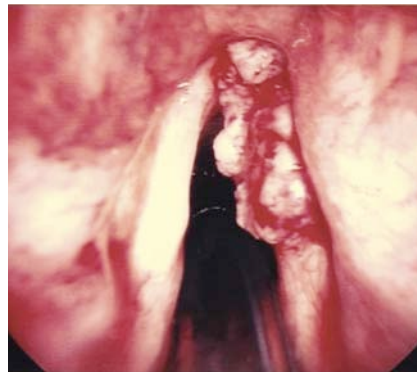

Figure 8. Exophytic tumour affecting the right vocal cord. This lesion was successfully treated with endoscopic laser microsurgical excision.

Laryngeal cysts

Laryngeal cysts can occur throughout the larynx and are usually due to mucus retention in the tiny mucus secreting glands in the submucosa of the entire upper aerodigestive tract. Surgical excision is usually required when they are located on the vocal cords and result in hoarseness.

Reinke's oedema

Reinke's oedema (oedema in the superficial layers of the vocal cord) is a common condition caused by long term exposure to irritants such as cigarette smoke. This interesting condition is more common in women than men and presents with chronic raspy dysphonia – pitch is reduced to the point that affected women

are often assumed to be men when using the telephone. Examination reveals diffuse boggy swelling of both vocal cords.

Smoking cessation and speech therapy are usually successful, but intractable cases require microsurgical excision of the redundant mucosa with aspiration of the oedematous fluid.

Respiratory papillomatosis

Respiratory papillomatosis is caused by human papilloma virus (HPV) and results in multiple warty lesions throughout the larynx (Figure 7). Infection most commonly occurs at the time of birth, and affected individuals usually present with hoarseness, stridor or 'noisy breathing' between 2 and 4 years of age. The risk

of transmission during vaginal delivery in the presence of a history of genital warts in pregnancy has been estimated to be approximately 0.5%.¹ Laryngeal papillomas may present in adulthood but are rare after the age of 30 years. The most common presenting symptom in older children and adults is hoarseness, but stridor and respiratory compromise may be seen in severe widespread disease.

The mainstay of treatment has been laser microsurgical removal, but disease recurrence is the norm and many patients require multiple operations. Intralesional injection of antiviral agents such as cidofovir (Vistide) is a relatively new treatment for severe cases. Rarely, recurrent papillomatosis is complicated by malignant transformation (approximately 0.5%) or extension in the tracheobronchial tree – a serious and often incurable condition.

Malignant lesions of the vocal cords

Squamous cell carcinoma

Squamous cell carcinoma (SCC) of the larynx is the most common malignancy of the upper aerodigestive system. It most commonly affects men aged in their 50s or 60s, but the incidence in women is increasing. The major risk factors are smoking and alcohol use, but 5% of cancers occur in patients who do not smoke or drink excessively.

Vocal cord cancer presents with progressive hoarseness; stridor and dysphagia occur in advanced disease. Early stage tumours appear as exophytic or ulcerative lesions affecting the free edge of the vocal cord; they rarely metastasise and hence have an excellent prognosis (Figure 8). Treatment options include radiotherapy and surgical resection. Endoscopic microsurgical laser resection is gaining acceptance as the surgical treatment of choice for early stage vocal cord cancer.

Cancers affecting the supraglottis and subglottic larynx can also produce dysphonia as a result of encroachment into the laryngeal airway, by direct extension to the

vocal cords or infiltration into the intrinsic muscles of the larynx. Initial symptoms are often subtle, so patients frequently present with advanced disease. Common presenting symptoms include stridor, hoarseness, haemoptysis and dysphagia. Cervical neck nodal metastasis is very common with supraglottic cancers, and hence patients may present with a neck lump. Treatment involves surgery, radiotherapy or combined modality therapy.

Neuromuscular disorders Muscle tension dysphonia

Muscle tension dysphonia is a relatively common yet poorly understood cause of hoarseness. It is thought to result from excessive and unnecessary tension of laryngeal muscles during phonation. On examination, patients typically constrict their supraglottic laryngeal muscles to the point where it can be difficult to visualise their vocal cords during vocalisation. It may develop as a compensatory vocal technique in patients with glottic insufficiency such as age related vocal atrophy; alternatively, it may occur as a primary imbalance of laryngeal muscle use. It is thought to be compounded by stress or anxiety.

The major complaint is usually fluctuating hoarseness and vocal fatigue, sometimes with a feeling of tightness or discomfort in the throat. It is important to ask about reflux laryngitis because this may be an exacerbating factor in a significant number of patients. Speech therapy to reduce excessive laryngeal tension during voice use is the cornerstone of management.

Spasmodic dysphonia

Until relatively recently, spasmodic dysphonia was considered a psychiatric diagnosis. It is now recognised as a regional dystonic reaction of the larynx characterised by involuntary spasms of the vocal cords. Like many dystonic reactions, it is absent at rest (therefore breathing is normal) but precipitated by speaking.

The most common form is adductor spasmodic dysphonia, in which there is increased closure of the vocal cords resulting in speech that is punctuated by frequent strangled and constricted stops. Intelligibility of the patient may be impaired markedly. Abductor spasmodic dysphonia, in which sudden increased opening of the vocal cords occurs and results in a breathy voice, is far less common. Other neurological symptoms are sometimes present in patients with spasmodic dysphonia, including tremors and facial dystonia.

Treatment of spasmodic dysphonia has been revolutionised by injection of botulinum toxin type A to temporarily paralyse the hyperfunctioning muscle group. This is done as an outpatient procedure using electromyographic guidance. Excellent results lasting three to four months can be expected.

Presbyphonia

Presbyphonia is hoarseness resulting from age related laryngeal changes. It is very common in elderly patients and characterised by an intermittent hoarse, breathy or wavery voice that often fatigues easily. Laryngeal muscle atrophy results in the vocal cords having a bowed appearance and, in combination with age related loss of vocal cord tone and elasticity, leads to varying degrees of hoarseness. Elderly patients may also be taking medications with anticholinergic side effects, which contribute to vocal dryness.

Speech therapy helps to increase laryngeal muscle tone and improve voice quality. Injection of fat or synthetic materials into the vocal cords is possible in severe cases, but it is rarely indicated.

Vocal cord paralysis

Vocal cord paralysis most commonly occurs as a consequence of paralysis of the recurrent laryngeal nerve (a distal branch of the vagus nerve that innervates the intrinsic laryngeal muscles and ascends from the mediastinum into the root of the

neck along the tracheo-oesophageal groove and is intimately associated with the back of the thyroid gland). Less commonly, the vagus nerve may be paralysed higher in the neck or skull base, resulting in palatal asymmetry in addition to vocal cord paralysis. Patients present with a breathy voice, reduced vocal pitch and significant vocal fatigue. The paralysed cord often lies in an open position, resulting in a large glottic gap that can lead to significant aspiration.

The common causes of vocal cord paralysis are:

- iatrogenic (thyroid or thoracic surgery)
- idiopathic – although unproven, viral neuritis is suspected to be a relatively common aetiological factor because recurrent laryngeal nerve palsy often occurs after an upper respiratory tract infection
- cancer (thyroid, laryngopharynx, lung, oesophageal)
- thoracic aortic aneurysm
- cerebrovascular accident, head trauma (central vagal paralysis).

When the cause is unknown, patients require a comprehensive radiological assessment of the head, neck and chest to exclude malignant infiltration of the vagus or its recurrent laryngeal nerve branch. Subsequent management depends on the cause of the nerve palsy. The treatment options to rehabilitate the paralysed vocal cord include:

- **Nonsurgical management.** If there is no aspiration and the patient is happy with the voice, the paralysed cord can be left alone with the expectation that partial compensation will occur after approximately six months. In cases where the nerve is bruised or temporary neuritis is suspected after an upper respiratory tract infection, complete recovery can be expected.
- **Injection thyroplasty.** This involves injection of fat or artificial substances (Gelfoam, Teflon) into the paralysed vocal cord to medialise it in an attempt to reduce the glottic gap. The

procedure requires a short general anaesthetic and has minimal morbidity.

- **Laryngeal framework surgery.** This involves insertion of a Silastic or Gortex implant into the vocal cord via a small window through the thyroid cartilage resulting in medialisation of the paralysed cord. The procedure can be performed under local anaesthetic and requires an overnight stay in hospital.

Final comments

Everyone experiences hoarseness at some time in their lives. Fortunately it is usually associated with an upper respiratory tract infection or voice overuse and will resolve spontaneously. Persistent unexplained hoarseness should alert the GP to the possibility of a benign or malignant laryngeal lesion, especially when it occurs in a

patient who smokes or has a high alcohol intake and when it is associated with other throat symptoms such as dysphagia, stridor or haemoptysis. Radiological investigations such as CT scans detect only large lesions and miss the majority of vocal cord lesions. Flexible endoscopic nasolaryngeal examination is the most sensitive investigatory tool and can be performed easily in the office setting. Treatment varies according to the cause but often requires collaboration between GP, ENT surgeon and speech pathologist. **MT**

Reference

1. Silverberg MJ, Thorsen P, Lindeberg H, Grant LA, Shah KV. Condyloma in pregnancy is strongly predictive of juvenile-onset recurrent respiratory papillomatosis. *Obstet Gynecol* 2003; 101: 645-652.

DECLARATION OF INTEREST: None.

Who wants your opinion?

WE DO. Did you find a particular article in this issue helpful in your practice? Do you have something to say about an article we have published or some of the opinions expressed? Write and tell us, and we will consider your letter for publication. We are more likely to print short letters (no longer than 250 words), so please be succinct. Write to: Medicine Today, PO Box 1473, Neutral Bay, NSW 2089