

Ranibizumab for wet age-related macular degeneration

H. KWON KANG BSc(Med), MB BS, FRANZCO ROBERT CHONG MB BSc(Med), FRANZCO

The aim of ranibizumab treatment in patients with wet age-related macular degeneration is to prevent further vision loss that will impact on independent living, ability to read and social interaction through facial recognition.

Age-related macular degeneration (AMD) is a common degenerative condition affecting the macula in individuals aged 50 years or older. The macula is the central portion of the retina responsible for fine visual tasks such as reading. AMD is the leading cause of legal blindness in Australia and other western countries. Approximately 2% of the population in the over 50s age group has end-stage AMD. This prevalence rises exponentially with age so that almost one in five people over the age of 85 years will have advanced AMD with impaired vision in at least one eye.

There are two types of AMD: dry and wet (Figure 1). In dry AMD, there is progressive atrophy of the retinal pigment epithelium, choriocapillaris and photoreceptors, resulting in gradual but progressive loss of central vision. The presence of drusen, yellow lipid deposits under the macula, is an early sign of AMD. Wet AMD is characterised by the growth of new but abnormal blood vessels under the macula. Vascular endothelial growth factor (VEGF) is one of the growth factors that are essential in driving the growth of the choroidal new vessels and increasing vascular permeability. This can lead to rapid loss of vision through macular swelling, bleeding and scarring. Patients commonly present with visual distortion (straight lines appearing wavy), a central scotoma or blurred spot. Patients who have these symptoms should be urgently referred to an ophthalmologist within a week.

What is ranibizumab and how does it work?

Ranibizumab (Lucentis) is a drug synthesised through a recombinant DNA process to inhibit all isoforms of VEGF-A.¹ It is the antigen-binding fragment of rodent immunoglobulin G, which has been humanised to minimise immune reaction when used in human eyes. It shares molecular lineage with bevacizumab, which is used in the treatment of a number of cancers. Ranibizumab binds VEGF-A molecules and prevents them from activating VEGF receptors. This restricts the growth of the new vessels and reduces macular swelling.

When is it used?

Ranibizumab is indicated for the treatment of patients with neovascular (wet) AMD and was listed on the PBS (authority required) in August 2007.

How is it administered?

Ranibizumab is delivered into the eye by an intraocular injection. A volume of 0.05 mL is injected with a 30 G needle through the sclera (Figures 2a to c). Topical anaesthetic is sometimes supplemented with a subconjunctival anaesthetic injection. The conjunctival sac is disinfected with povidone iodine prior to the injection.

How effective is it?

Two pivotal prospective, randomised, controlled trials investigating ranibizumab

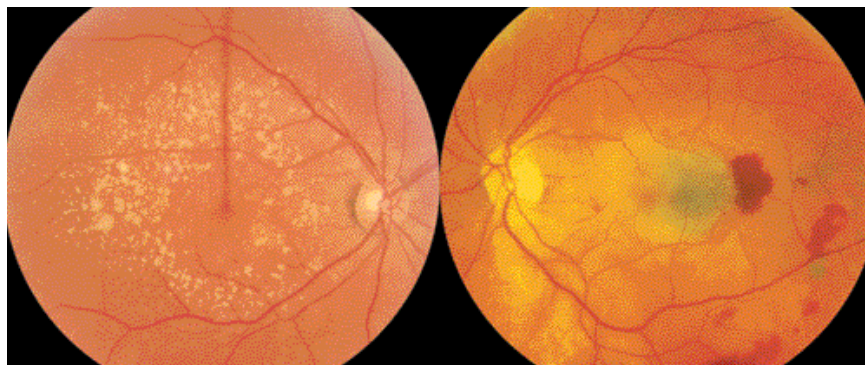
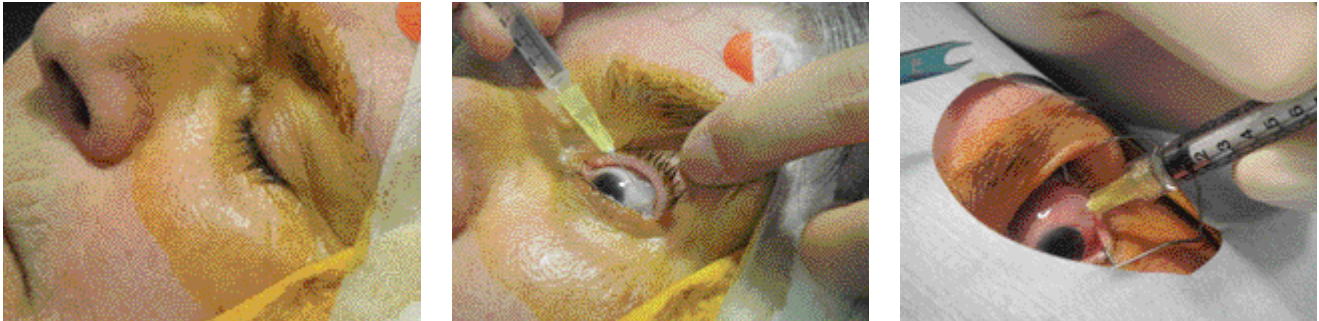

Figure 1. Fundus photographs of dry (left) and wet (right) age-related macular degeneration.

Dr Kang is a Vitreoretinal Surgeon at the Retina & Vitreous Centre, Sydney. Dr Chong is a Retinal Specialist at Southern Ophthalmology, Sydney, NSW.



Figures 2a to c. Steps involved in the intravitreal administration of ranibizumab. a (left). After topical anaesthetic, the eye is sterilised with povidone iodine. b (middle). Subconjunctival anaesthetic is applied to the injection site. c (right). Following further sterilisation, the eye is draped and a speculum is inserted to hold the eyelids open. Ranibizumab is injected approximately 3.5 mm behind the limbus.

are the MARINA trial (Minimally Classic/Occult Trial of the Anti-VEGF Antibody Ranibizumab in the Treatment of Neovascular AMD) and ANCHOR trial (Anti-VEGF Antibody for the Treatment of Predominantly Classic Choroidal Neovascularization in AMD). In these trials ranibizumab prevented any further vision loss in three out of four patients with wet AMD over two years, and more than 90% of patients lost less than two Snellen lines of vision. There was an overall

improvement in vision in the treated group, with one in three patients gaining at least two Snellen lines of vision. The mean vision of patients in the treated group was almost three Snellen lines better than in those in the control group over two years (Figure 3).^{2,3}

Ultimately, the aim of treatment with ranibizumab is to prevent further vision loss that will impact on independent living, ability to read and social interaction through facial recognition.

How long is the course of treatment?

The course of ranibizumab is variable depending on the response of the patient to treatment. Most ophthalmologists will start treatment with monthly injections and then try to reduce the frequency of treatments as the patient's condition stabilises. Treatment has to be individualised to achieve the optimum outcome. The duration of treatment can vary with many patients needing treatment beyond two years. As a general rule, the response is better and quicker if the disease is detected and treated earlier rather than later.

What are the risks?

Minor and temporary side effects can occur for a few days following an injection of ranibizumab. These include floaters, conjunctival haemorrhage, foreign-body sensation and discomfort. There is a small risk of serious eye infection (endophthalmitis) of approximately one in 2000 with each injection. Presenting symptoms of endophthalmitis include increasing blurring, eye pain, increasing redness and periocular swelling. This is a serious complication requiring the urgent attention of an ophthalmologist. Other complications include vitreous haemorrhage, retinal detachment and lens damage that may require surgical repair.

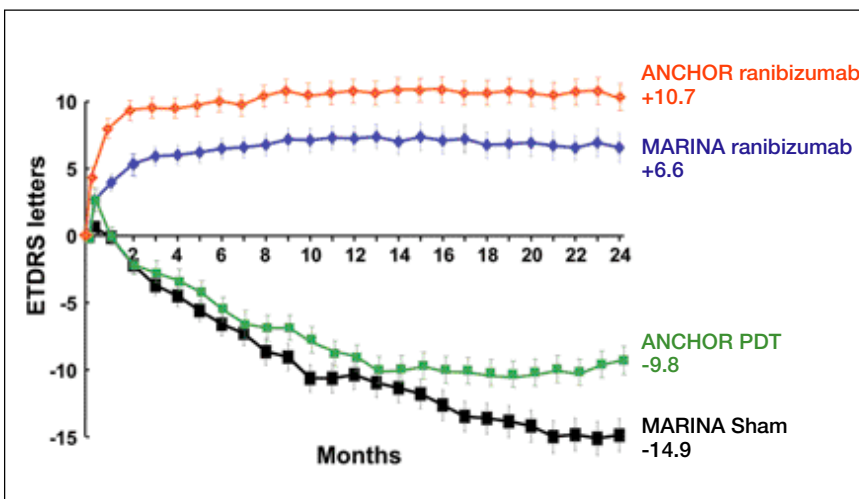


Figure 3. Combined plot of two-year visual outcomes in the ANCHOR and MARINA trials. The ANCHOR trial compared ranibizumab with photodynamic therapy (PDT) for the treatment of predominantly classic lesions. The MARINA trial compared ranibizumab with sham injections for the treatment of minimally classic lesions. Five letters equate to one line of vision on an ETDRS (Early Treatment Diabetic Retinopathy Study) chart. Three ETDRS lines are approximately equivalent to two Snellen lines of vision.

Do patients have to stop antiplatelet or anticoagulant therapy prior to injections?

The early trials (MARINA and ANCHOR trials) included patients who were taking anticoagulants (warfarin) and antiplatelets (clopidogrel and aspirin) but subsequent trials investigating ranibizumab excluded these patients due to concerns of a possible increase in the risk of ocular and nonocular haemorrhage. Ultimately, the decision to continue or stop these drugs in patients receiving injections of ranibizumab is left to the discretion of the treating specialist.

What is the cost to the patient?

Ranibizumab is available on the PBS and the cost of the drug, which was prohibitive, is now heavily subsidised. However, there are strict criteria that have to be fulfilled before Medicare approval is given. As part of the approval process, the location of the neovascular lesion needs to be determined with a fluorescein angiogram of the retina and a copy of the result sent to Medicare. The other costs to the patient include specialist consultation and injection fees, as well as regular retinal imaging with optical coherence tomography to monitor the effect of treatment.

Summary

Ranibizumab has revolutionised treatment of wet AMD by offering hope of visual improvement in some patients and visual stabilisation in most patients. Until new treatments are proven to be better, ranibizumab remains the gold standard in wet AMD therapy. The relatively high frequency of intraocular injections pose significant challenges. Further research is needed to identify longer-acting agents or alternative modes of delivery to reduce the burden of frequent visits on patients. MT

References

1. Ferrara N, Damico L, Shams N, Lowman H, Kim R. Development of ranibizumab, an anti-vascular endothelial growth factor antigen binding fragment, as therapy for neovascular age-related macular degeneration. *Retina* 2006; 26: 859-870.
2. Rosenfeld PJ, Brown DM, Heier JS, et al. Ranibizumab for neovascular age-related macular degeneration. *N Engl J Med* 2006; 355: 1419-1431.
3. Brown DM, Michels M, Kaiser PK, Heier JS, Sy JP, Ianchulev T. Ranibizumab versus verteporfin photodynamic therapy for neovascular age-related macular degeneration: two-year results of the ANCHOR study. *Ophthalmology* 2009; 116: 57-65 e5.

This article is for general information purposes only, and the full product information should be consulted before prescribing any of the mentioned medications.

COMPETING INTERESTS: None.