

# Neck lumps

## A guide to assessment and management

**A wide variety of pathology can present with a neck lump. The two most important investigations that a GP can arrange prior to referral of a patient with a suspicious neck lump are a neck soft tissue CT scan and a fine needle aspiration biopsy.**

### CHRIS HOBBS

BSc, MB BS, MD, FRCS, DLO

### RON BOVA

MB BS, MS, FRACS

Dr Hobbs is an ENT Fellow and Dr Bova is an ENT-Head and Neck Surgeon at St Vincent's Hospital, Sydney, NSW.

Neck lumps are a common presentation in general practice. They are usually first noticed by the patient, although occasionally they are detected on routine physical examination.

A comprehensive history and clinical examination with appropriate investigations is important to determine if the lump is benign or malignant. When in doubt or if clinical assessment suggests a tumour, prompt referral to a head and neck surgeon is important to clarify the diagnosis. Fortunately, neck lumps in children nearly always represent benign reactive lymph nodes, which can be diagnosed on clinical examination alone. However, children with persistent suspicious neck lumps should be referred to a paediatric surgeon. As a general rule, a persistent lateral neck lump in an adult should always be assumed to be malignant until proven otherwise.

This article describes the thorough assessment of a patient with a neck lump and when a patient should be referred to a specialist.

### Assessment

#### What to ask in the history

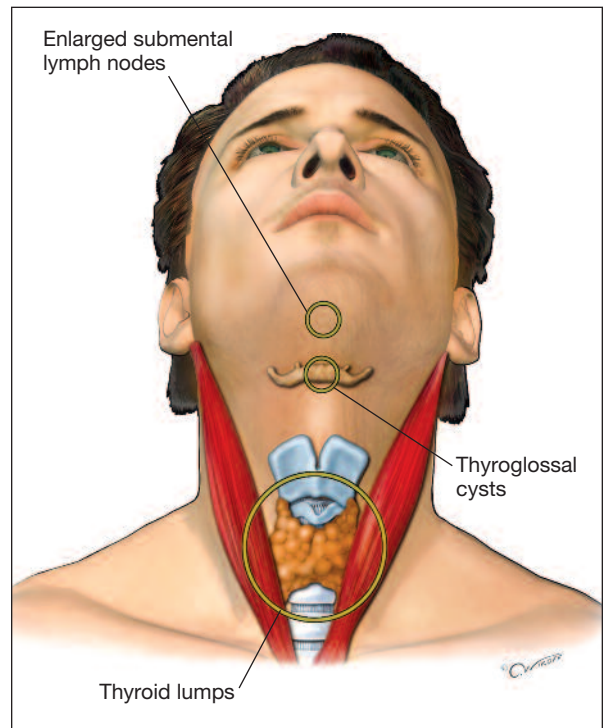
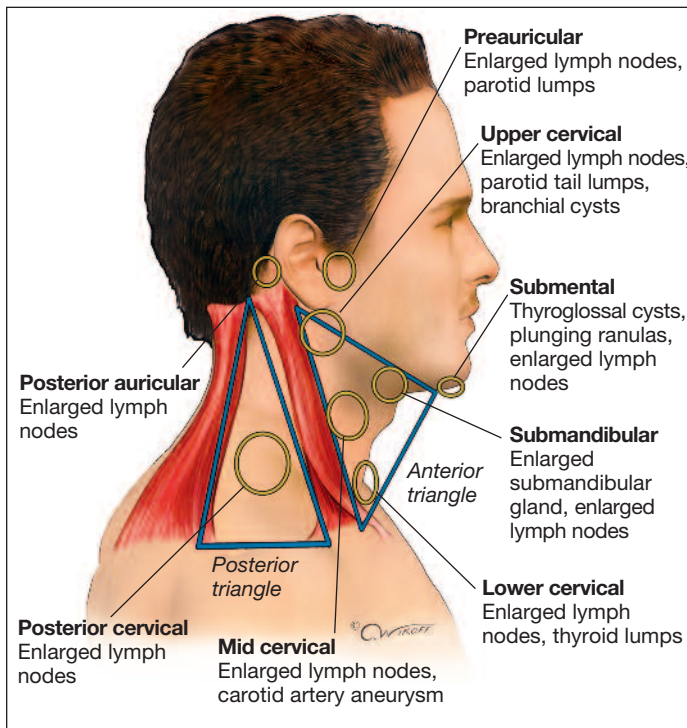
Comprehensive history taking and physical examination are critical in the evaluation of a patient with a neck mass (Table 1).

Children and younger adults presenting with a neck lump of short duration usually have a history suggestive of a preceding infective focus. Examples of such infections are tonsillitis, dental infection, mumps and glandular fever (especially in teenagers); less common infections include toxoplasmosis, cat scratch disease, tuberculosis and HIV infection.

Adults presenting with a neck lump should always be questioned about their risk factors for head and neck cancer (tobacco smoking, excessive alcohol intake and past history of upper aerodigestive tract malignancy). Associated upper aerodigestive tract symptoms such as dysphagia, hoarseness and throat pain, referred otalgia, weight loss and haemoptysis are all possible symptoms

### IN SUMMARY

- Neck lumps can be categorised as congenital/developmental, inflammatory or neoplastic in origin.
- A persistent lateral neck lump in an adult should be considered malignant until proven otherwise.
- A history of smoking, excessive alcohol consumption or previous head and neck or skin cancer should raise suspicion.
- A thorough examination of the head and neck (including skin) is essential.
- The most important investigations in a patient with a suspicious neck lump are a neck soft tissue CT scan with contrast and a fine needle aspiration biopsy.



ILLUSTRATIONS © CHRIS WIKOFF, 2010

### Table 1. Assessment of a neck lump

- Take a full history – including duration, change in size of lump, dysphagia, hoarseness, referred pain (e.g. otalgia), fever, night sweats and weight loss
- Check risk factors – including smoking, alcohol consumption, upper aerodigestive tract malignancy and sun exposure
- Examine the seated patient – inspect the neck from the front and palpate it from behind. Is the lump a midline or lateral neck lump, is it soft or hard, is it mobile or fixed?
- Complete the head and neck examination – the remainder of the neck, the thyroid, oral cavity, oropharynx, nose and ears, and the skin of the scalp and the back of the neck
- Examine the facial nerve for lumps in the parotid region
- Suspicious neck lumps should be investigated with CT scan and fine needle aspiration biopsy
- Thyroid lumps should be investigated with an ultrasound and thyroid function tests
- Consider referral of all suspicious neck lumps to a head and neck surgeon

of a head and neck mucosal malignancy.

Elderly patients, especially those with sun-damaged skin, should also be questioned about previous facial cutaneous cancers. These cancers can metastasise to parotid and cervical lymph nodes sometimes months or years following resection of what may have appeared to be a small trivial skin cancer.

Adults with lymphoma can present with a neck lump and may experience systemic symptoms such as fever, malaise, night sweats or weight loss.

#### What to look for in the examination

The neck is a complex area that requires a systematic approach to examination. Variations in neck size, thickness and prominence of normal structures can all make neck examination challenging. Normal structures such as the thyroid, cricoid cartilage, hyoid bone and upper cervical vertebrae can easily be confused with a deep neck mass.

It is common to feel small (subcentimetre diameter) mobile rubbery lymph nodes in children and young patients with thin necks. These nodes are most commonly found in the posterior triangle and anterior to the upper third of the sternocleidomastoid muscle (jugulodigastric nodes).

Figures 1a and b.

Anatomical divisions of the neck and sites of common pathology. a (left). Lateral neck. b (right). Midline neck.

**Table 2. Classification of neck lumps****Congenital/developmental**

- Cystic hygromas (lymphangiomas)
- Vascular malformation
- Branchial cyst
- Thyroglossal cyst
- Dermoid cyst
- Plunging ranula

**Inflammatory**

- Lymphadenopathy
  - nonspecific lymphadenitis in babies and children
  - viral, e.g. glandular fever (Epstein Barr virus infection), toxoplasmosis
  - bacterial, e.g. tonsillitis, odontogenic infections
  - other, e.g. tuberculosis, brucellosis, cat scratch disease
- Salivary gland inflammation
  - ductal obstruction without infection (due to calculi or strictures)
  - bacterial, e.g. staphylococcal infection
  - viral, e.g. mumps

**Neoplastic****Benign**

- Thyroid – colloid nodule, follicular adenoma, simple cyst
- Salivary gland – pleomorphic adenoma, Wharthin's tumour, monomorphic adenoma
- Neurovascular
  - nerve schwannoma, neurofibroma
  - vascular malformation
- Connective tissue tumours – lipoma, fibroma, etc.

**Malignant**

- Lymphadenopathy
  - primary: lymphoma
  - secondary: SCC (mucosa or skin), melanoma, adenocarcinoma (in upper neck, from salivary gland; in supraclavicular fossa, from stomach)
- Thyroid – papillary, follicular, medullary and anaplastic carcinomas
- Salivary gland
  - primary: mucoepidermoid, acinic cell, adenoid cystic, adenocarcinoma
  - secondary: cutaneous SCC, cutaneous melanoma

ABBREVIATION: SCC = squamous cell carcinoma.

Similarly, in elderly patients the submandibular glands often descend and are palpable as symmetrical soft masses in the submandibular region.

Determining if a neck lump is in the midline or lateral neck is the first step. Lateral neck lumps can further be divided into anterior or posterior triangle neck lumps. Figures 1a and b illustrate the anatomical triangles and common neck lumps found in these locations.

A firm or hard lump should raise alarm bells for metastatic malignancy. Examination of the tongue, floor of the mouth, oropharynx and buccal mucosa can easily be performed with a tongue depressor, gloved finger and a bright light. Examination of the scalp and facial skin for

possible squamous cell carcinoma (SCC) or melanoma is performed, as well as palpation of the parotid and thyroid gland. ENT, head and neck surgeons can comprehensively evaluate the nasal cavity and upper aerodigestive tract by transnasal endoscopy. This is carried out under topical spray anaesthetic in the office.

If lymphoma is suspected, examination of the axillary and inguinal nodes should be performed, and also a complete abdominal examination looking for hepatosplenomegaly.

**What investigations to order**

The two most important investigations that a GP can arrange prior to referral of a patient with a neck lump are a neck CT

scan and a fine needle aspiration biopsy (FNAB).

**Soft tissue CT scan**

A neck soft tissue CT scan with contrast provides superior anatomical definition of any neck lump while also imaging the remainder of the neck tissues. If there are metastatic nodes, this procedure may also facilitate localisation of the primary tumour.

**Ultrasound**

Ultrasound is the imaging modality of choice for thyroid masses. It is useful for differentiating cystic from solid lateral neck masses, but of less utility for assessing malignant lumps.

**FNAB**

FNAB is the most accurate diagnostic tool for investigating neck lumps. It can be performed in most radiology centres (under ultrasound guidance), in major pathology centres (usually in the teaching hospital setting) or by surgeons in their rooms. Although the accuracy of FNAB is high (approximately 90%), false negatives do occur and hence a suspicious neck mass should always be referred for comprehensive evaluation. For example, an FNAB of a cystic nodal metastasis may reveal degenerate benign-looking squamous debris from the central fluid component while missing the solid peripheral tumour rim of the lymph node.

**Blood tests**

Blood tests are occasionally helpful. Lymphocytosis on full blood count in addition to viral serology may help diagnose a systemic viral illness (e.g. Monospot test for Epstein Barr virus, toxoplasma serology and HIV serology). Thyroid function tests are routine when investigating thyroid lumps.

**Classification**

Neck lumps are classified into congenital/developmental lumps, inflammatory/

infective lumps and neoplastic lumps, as described below and summarised in Table 2.

### Congenital/developmental lumps – midline

#### Thyroglossal cysts

Thyroglossal cysts arise from remnants of the thyroglossal duct (a developmental tract of tissue that originates from the tongue base and descends into the lower neck forming the thyroid gland, and which usually involutes *in utero*) and usually present as painless cystic swellings in the region of the hyoid (Figure 2). The cysts occasionally get infected and may present as inflammatory swellings. They can occur in any age group, but are most common in young adults (50% present before age 20 years). Classically they move upwards on tongue protrusion.

Excision is recommended for all cysts to confirm the diagnosis and to prevent future infections.

#### Dermoid cysts

Dermoid cysts are inclusion cysts that occur along lines of fusion (e.g. nose, palate or under the tongue). Occasionally, however, they can result from implantation through trauma, either accidental or iatrogenic following surgery.

Surgical removal is indicated in most cases. When the cysts occur in or around the nose or eyes, prior CT or MRI scanning is essential to exclude deeper connections through the calvarium that may contain a meningocele or encephalocele.

### Congenital/developmental lumps – lateral

#### Cystic hygromas (lymphangiomas)

Cystic hygromas are lymphatic hamartomas rather than true cysts and present as soft, fluctuant and transilluminable masses just under the skin. Nearly all present by the age of 2 to 3 years, with 60% occurring in the head and neck region (usually in the posterior triangle) and most presenting at birth. They are often

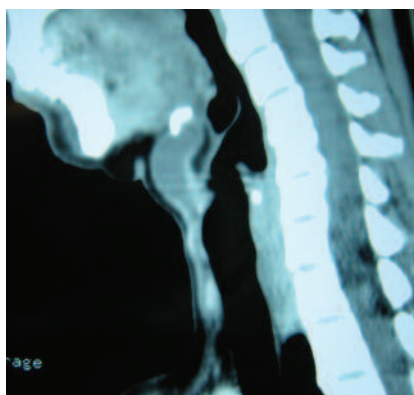


Figure 2. Thyroglossal cyst. CT scan, sagittal view, showing a thyroglossal cyst extending inferiorly from just below the hyoid in a 21-year-old man.

multiloculated and typically painless.

Ultrasound is useful to confirm the diagnosis and CT scanning is essential if surgery is contemplated.

#### Branchial cysts

Branchial cysts usually present as smooth, fluctuant masses in the lateral neck, typically just anterior to the upper sternocleidomastoid, in young adults (Figure 3). They frequently become infected following an upper respiratory tract infection. Most arise from embryonic remnants of the second branchial cleft and may have a small sinus tract into tonsillar fossa.

CT and FNAB are important to confirm the diagnosis and to help exclude malignancy. All branchial cysts should be surgically removed.

#### Plunging ranulas

Ranulas are pseudocysts formed by mucous extravasations from the sublingual gland and typically present as cystic swellings in the floor of the mouth. Occasionally, the mucous ruptures through the floor of mouth musculature and presents as soft neck lumps in the submandibular triangle (plunging ranulas).

They are treated by transoral excision of the sublingual gland, which results in drainage of the ranula. Surgery is curative.

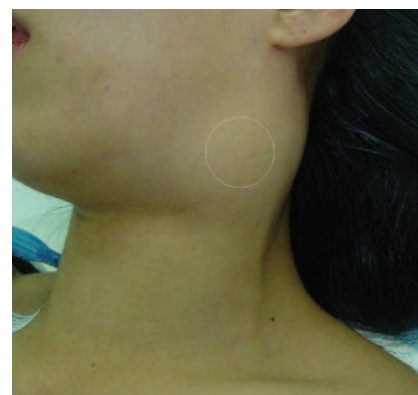

Figure 3. Branchial cyst presenting as a mass in the upper neck anterior to the sternocleidomastoid muscle in a 26-year-old woman.

### Inflammatory/infective lumps

#### Lymphadenopathy (nonspecific lymphadenitis)

Small palpable cervical nodes are very common in children and young adults and are most common in the jugulodigastric region. Such lymphadenopathy can persist for several months and is associated with very few systemic symptoms. It is usually related to an initial nonspecific and self-limiting viral upper respiratory tract infection. If persistent nodes are biopsied to exclude other causes, the histology reveals reactive hyperplasia.

#### Acute lymphadenitis

Acute lymphadenitis can be bacterial (e.g. *Staphylococcus aureus* infection, group A streptococcal infection) or viral (e.g. infectious mononucleosis, mumps) in origin. In bacterial infection, the source is usually tonsillar or dental, with tender nodes typically found in the submandibular or jugulodigastric region.

#### Mycobacterial lymphadenitis

Mycobacterial lymphadenitis should be suspected if an acute lymphadenitis is more indolent in its course, with only mild tenderness and a partial response to antibiotics. Infection with nontuberculous

continued

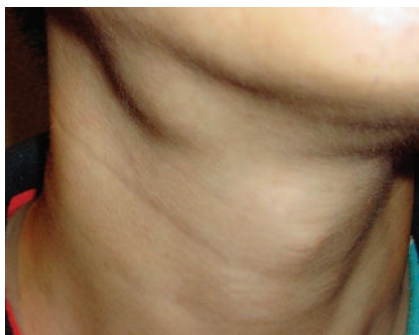

Figure 4. Sialolithiasis. An enlarged submandibular gland resulting from calculus obstruction of the submandibular duct.

mycobacteria (atypical mycobacteria) most commonly affects children under the age of 5 years. Patients are normally well, with a nontender neck mass and no systemic symptoms, although occasionally a discharging sinus will be present. The usual pathogen is an atypical mycobacterium such as *Mycobacterium avium-intracellulare*.

Tuberculosis is more common in adults than children and should be considered if the nodes are bilateral or in the supraclavicular region, and are associated with respiratory symptoms. Other rare granulomatous causes of adenopathy include cat scratch disease and actinomycosis.

#### HIV infection


Cervical lymphadenopathy is very common in patients with HIV infection. Lymphadenopathy syndrome is a mild form of HIV disease that represents one of the initial stages of the infection. Patients can remain stable for months to years, with little in the way of symptoms. This diagnosis should be considered in any adult with persistent generalised lymphadenopathy and the relevant risk factors.

#### Acute sialadenitis

Acute infection of the salivary glands can be bacterial or viral in origin. Bacterial sialadenitis occurs more frequently in the parotid glands, is more common in the elderly and is associated with reduced

salivary flow from dehydration or anticholinergic medication.

Treatment is with broad-spectrum antibiotics covering *S. aureus*, the most common pathogen causing infection of the salivary glands, in addition to supportive measures (rehydration, analgesics and gland massage to encourage salivary flow). Appropriate antibiotics include



flucloxacillin, cephalexin and clindamycin. Surgical drainage may be required if an abscess develops.

Viral sialadenitis is most commonly due to the mumps virus, which typically affects the parotid glands bilaterally. The mumps virus most often affects children, with peak incidence at ages 4 to 6 years. Other causes include coxsackievirus, cytomegalovirus and HIV.

#### Sialolithiasis

Sialolithiasis refers to the presence of calculi in the parotid or submandibular ducts. Patients present with swelling of the affected gland associated with eating or drinking (Figure 4). Initially, the swelling gradually resolves after the patient stops eating; however, with repeated enlargement and inflammation, a permanently swollen gland can result (chronic obstructive sialadenitis).

In the acute noninflammatory stage, expulsion or direct removal of the calculus from the duct is often all that is required. In chronic sialolithiasis or chronic obstructive sialadenitis, salivary gland resection is often necessary.

#### Autoimmune sialadenitis

Sjögren's syndrome, an autoimmune disorder, presents with enlarged parotid glands associated with dry eyes and dry mouth. An autoimmune screen shows raised antinuclear antibodies (anti-Ro and anti-La).

Diagnosis is usually based on history and autoimmune serology. However, biopsy of a lower lip minor salivary gland is diagnostic (minor salivary glands are tiny submucosal glands that occur throughout the oral cavity and upper aerodigestive tract).

#### Sialadenosis

Sialadenosis refers to a non-neoplastic, noninflammatory asymptomatic swelling of the salivary glands. It is usually due to a systemic illness such as endocrine disease (e.g. diabetes, hypothyroidism and Cushing's syndrome), a metabolic disorder (e.g. obesity and cirrhosis), nutritional problems (e.g. vitamin deficiency and bulimia) or drug-induced sialomegaly.

#### Thyroiditis

The most common inflammatory goitre is Hashimoto's thyroiditis. In this autoimmune condition, autoantibodies against thyroid peroxidase are produced, resulting in lymphocytic infiltration of the thyroid and eventually a goitre, which is typically firm and rubbery. Management by an endocrinologist is usually necessary because of the initial hyperthyroidism and subsequent hypothyroidism. Occasionally surgery is required for obstructive symptoms.

Other inflammatory conditions of the thyroid include Riedel's thyroiditis and De Quervain's thyroiditis.

## Neoplastic lumps – benign

A lower central neck lump in an adult is likely to originate from the thyroid gland. However, any structure in the neck can produce a benign growth – these include diverse tumours such as lipomas, fibromas, haemangiomas and neuromas. Those that are present in the skin or subcutaneous tissue (e.g. lipomas) are normally obvious on examination.

### Thyroid nodules

Thyroid nodules are palpable in 5% of the population and approximately 95% are benign. They include hyperplastic or colloid nodules found in multinodular goitre, cysts and follicular adenomas. When thyroid nodules are detected, the challenge facing the GP is to distinguish those patients who have malignancy and therefore require referral for surgical management from patients who have benign nodules and can be followed up non-operatively.

All patients with suspicious or dominant nodules should have thyroid function tests and neck ultrasound, and FNAB of the nodules.

Red flags that should alert the GP to the possibility of a thyroid nodule being malignant include:

- male gender
- extremes of age (younger than 20 years or older than 65 years)
- exposure to ionising radiation, especially during childhood
- family history of thyroid cancer
- large solitary nodules
- hard nodules or with fixation to adjacent neck tissues
- symptoms of local invasion (neck pain, hoarseness or dysphagia)
- nodules that grow rapidly over weeks or months
- thyroid nodules associated with enlarged cervical neck nodes.

Patients with suspicious or symptomatic thyroid nodules should be referred to a surgeon once appropriate investigations have been arranged. Patients with

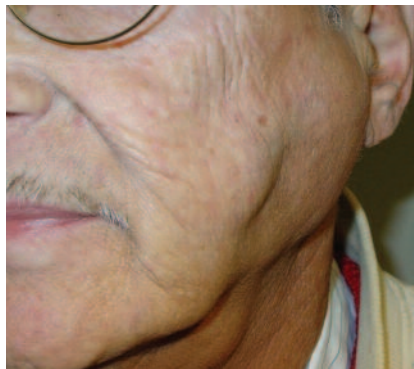


Figure 5. A parotid mass in an elderly man who six months ago had a small cutaneous squamous cell carcinoma (SCC) excised from his left forehead. The parotid mass turned out to be a metastatic SCC from his previous skin cancer.

abnormal thyroid function tests and thyroid nodules should be referred to an endocrinologist for further evaluation.

### Salivary gland tumours

The most common benign salivary tumour is a pleomorphic adenoma. Other benign tumours include Warthin's tumour, oncocytoma and monomorphic adenoma. Most salivary gland tumours (80%) occur in the parotid gland (Figure 5). They less commonly originate in the submandibular gland or minor salivary glands. They generally present as slow growing asymptomatic masses and feel well-circumscribed and firm.

Treatment is surgical excision of the affected gland in all cases except elderly patients or those who are unfit for general anaesthesia.

### Neural tumours

Neurofibromas and schwannomas can arise from any nerve in the neck, most commonly from the vagus or sympathetic chain, and present as well-circumscribed firm masses. Because of their neural origin, FNAB is often very painful.

Surgical resection often results in palsy of the affected nerve and hence observation of small asymptomatic benign neural

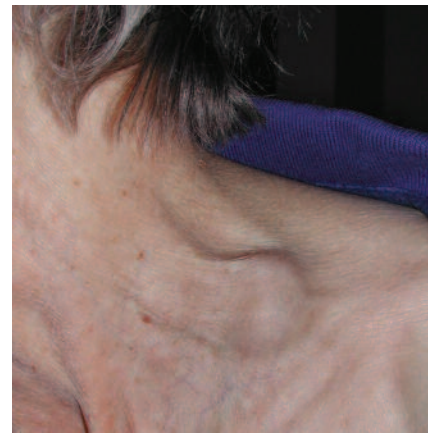

Figure 6. Left-sided supraclavicular lymphadenopathy (Virchow's node or Troisier's sign) in a patient with gastric adenocarcinoma.

tumours may be appropriate in selected patients.

### Carotid body tumours

Carotid body tumours are rare benign tumours of the carotid body neural plexus. They usually present as a painless pulsatile mass at the level of the carotid bifurcation, and typically can be moved side to side but not vertically.

The tumours are extremely vascular, and are diagnosed using a combination of CT scan, MRI, magnetic resonance angiography and carotid doppler scanning. Following comprehensive assessment, surgery is usually performed by a head and neck surgeon and a vascular surgeon.

## Neoplastic lumps – malignant

### Squamous cell carcinoma

SCC is the most common cause of a malignant neck lump. Metastatic SCC most commonly arises from the mucosa of the upper aerodigestive tract (oral cavity, nasopharynx, oropharynx and laryngopharynx). Cutaneous malignancies (SCC and melanoma) may also metastasise to the parotid gland or lateral cervical lymph nodes, sometimes years after the primary tumour was excised.

continued

Nasopharyngeal carcinoma (NPC) should always be considered in adult Asian patients presenting with a neck lump because this is one of the most common cancers in southern China and Hong Kong.

### Lymphoma

Lymphoma can present with a solitary neck node but more commonly multiple lymph nodes are involved. The nodes are typically 'rubbery' in consistency. Associated symptoms include night sweats, lethargy and weight loss. Lymphoma is the most common cause of a malignant neck lump in children and should therefore, despite being rare, be considered in the differential diagnosis of any progressive or persistent childhood lymphadenopathy.

FNAB and CT scan are indicated, with referral to a haematologist if cytology is suggestive of lymphoma.

### Adenocarcinoma


Metastatic adenocarcinoma to the upper cervical lymph nodes may originate from the salivary glands or sinonasal cavity. Metastatic adenocarcinoma in the lower neck may arise from a site below the clavicles (e.g. lung, oesophagus or stomach). Virchow's node (also referred to as Troisier's sign) refers to metastatic adenocarcinoma occurring in the left supraclavicular fossa and usually arising from the stomach (Figure 6).

### Thyroid cancer

Thyroid cancer appears to be increasing in incidence in Western countries. The most common thyroid cancers are the well-differentiated types papillary carcinoma (75%) and follicular carcinoma (15%), which have a more favourable prognosis than medullary carcinoma and undifferentiated types such as anaplastic carcinoma.

Most thyroid cancers present clinically with a palpable thyroid nodule, which is often asymptomatic. About half of thyroid cancers are initially noticed by the patient,

whereas the remainder are detected during routine physical examination, by chance on imaging studies often for unrelated medical conditions or during surgery for benign thyroid disease. Occasionally thyroid cancer can present with a metastatic neck node, and the diagnosis is confirmed on FNAB.



When thyroid cancer is suspected or demonstrated on FNAB, prompt referral to a thyroid surgeon is warranted. Total thyroidectomy and adjuvant iodine ablation therapy is indicated for most patients diagnosed with thyroid cancer.

### Salivary gland malignancy

Salivary gland cancers include mucoepidermoid carcinoma, adenoid cystic carcinoma, acinic cell carcinoma, adenocarcinoma and metastatic cutaneous SCC. The most common malignant parotid lump in Australia is metastatic cutaneous SCC, reflecting the very high incidence of facial cutaneous cancers in this country. Symptoms and signs that suggest malignancy include pain, rapid growth, a hard mass, fixity to the skin or mandible and facial nerve palsy.

FNAB and CT/MRI scanning are essential to assess the extent of disease and to plan surgery. High-grade salivary gland

malignancy often requires neck dissection and postoperative radiotherapy.

### Conclusion

A wide variety of pathology can present with a neck lump. To determine whether the lump is benign or malignant, a comprehensive history and clinical examination are essential. If there is any doubt as to the diagnosis or if clinical assessment suggests a tumour, then prompt referral to a head and neck surgeon is important to clarify the diagnosis and plan further treatment. The two most important investigations that a GP can arrange prior to referral are a neck soft tissue CT scan with contrast and FNAB. MT

### Further reading

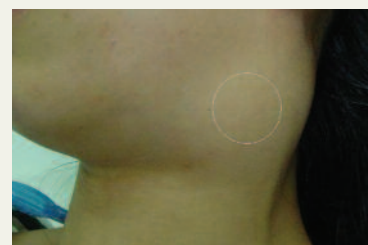
Bova R. A guide to salivary gland disorders. *Medicine Today* 2006; 7(2): 44-48.

Bova R. Head and neck cancer: a guide to diagnosis and an overview of management. *Medicine Today* 2005; 6(4): 54-61.

Gleeson M, Herbert A, Richards A. Management of lateral neck masses in adults. *BMJ* 2000; 320: 1521-1524.

COMPETING INTERESTS: None.

### Online CPD Journal Program



Lymphoma is a rare cause of neck lumps in children. True or false?

Review your knowledge of this topic and earn CPD/PDP points by taking part in *Medicine Today's* Online CPD Journal Program.

Log on to [www.medicinetoday.com.au/cpd](http://www.medicinetoday.com.au/cpd)