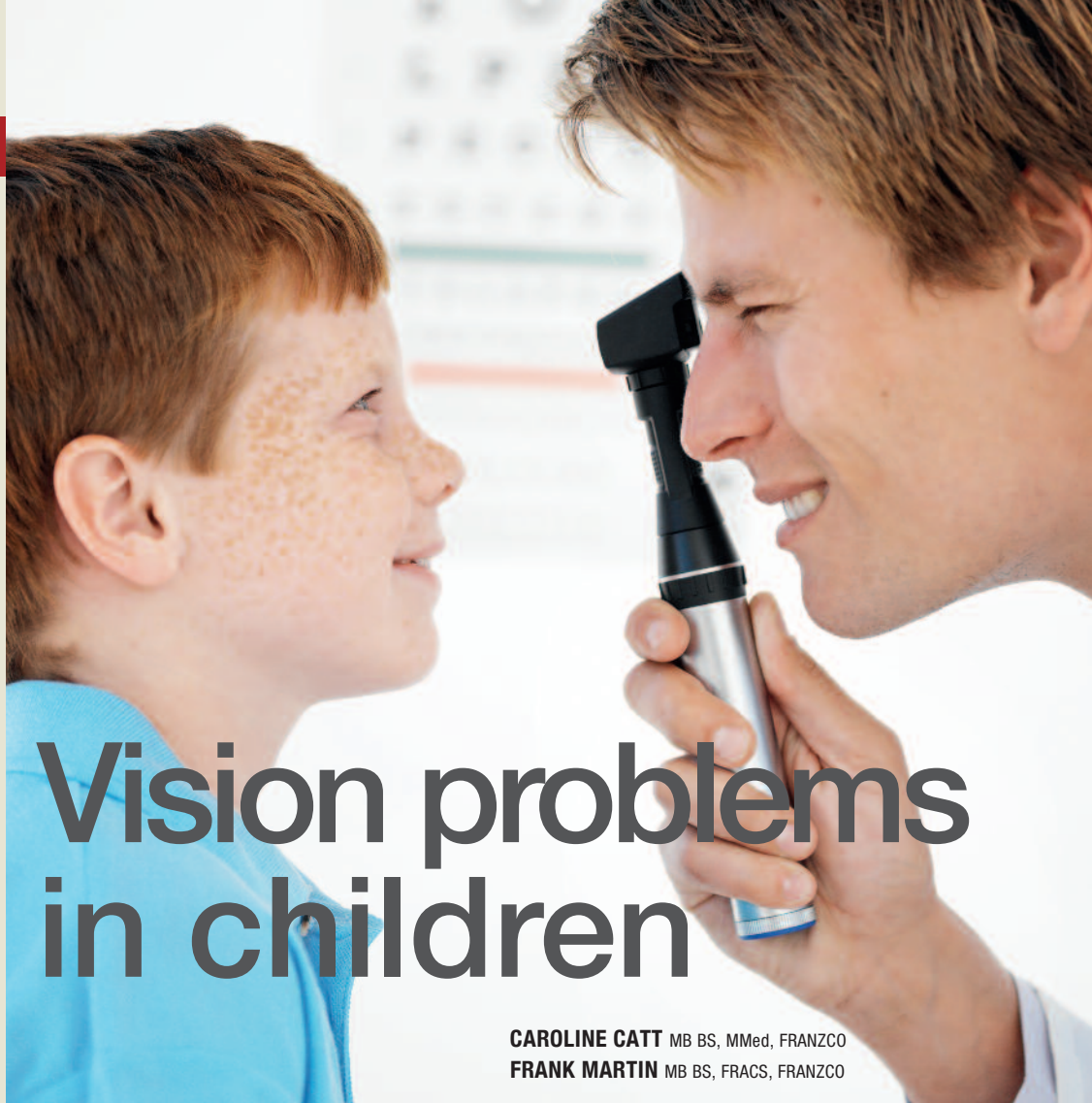



Vision problems in children

CAROLINE CATT MB BS, MMed, FRANZCO

FRANK MARTIN MB BS, FRACS, FRANZCO

Key points

- Most vision problems can be identified by taking a history and performing a clinical examination, including measuring the visual acuity. The age and capacity of the child will dictate which vision test to use.
- Any difference in vision of more than one line between the eyes is abnormal.
- Any strabismus (squint) after the age of four months is abnormal.
- Any nystagmus, pupil abnormality or asymmetry of the red reflex is abnormal.
- It is important to be aware that strabismus may represent intraocular or intracranial disease.
- Many vision problems in children are reversible if identified and treated early.

Vision problems in a child may represent a life- or vision-threatening intraocular or intracranial problem. Vision problems may be reversible if diagnosed and treated early.


A vision problem in a child is an infrequent reason for presenting to a GP, but the timeliness of assessment and referral of the child may have a significant impact on the outcome. Depending on the age of the child and the age of onset of the problem, a vision problem may present in a number of different ways. Importantly, problems with vision may represent underlying intraocular or intracranial pathology. Vision problems may be reversible if diagnosed and treated early, making it important to be able to assess a child's visual system at the presentation.

ASSESSING VISION

It is important to establish rapport with the child who you are assessing by introducing yourself and talking to him or her, as well as the parents. This may allow the child to feel more comfortable and be able to co-operate during the assessment.

A history detailing the reason for presentation and a past medical history should be sought. In particular, the following should be enquired about: prematurity, birth history, any systemic disease or congenital anomalies, growth and development, and if the child is taking any medications or has any allergies.

Dr Catt completed her Ophthalmology Training at Sydney Eye Hospital and will soon be commencing training in Paediatric Ophthalmology. Clinical Professor Martin is Clinical Professor at the Sydney Children's Hospital Network, Sydney, NSW.



Figures 1a to d. Vision tests for children. a (top left). Teller acuity cards. b (top right). Cardiff acuity cards. c (above left). Kay picture cards. d (above right). Lea symbols test.

A family history detailing any refractive error, strabismus, ocular disease or consanguinity is also important.

Observing if the child makes eye contact, responds to a smile or looks at objects around the room is an important part of assessing vision, particularly in preverbal children. An unusual head posture, an obvious strabismus (ocular misalignment or squint) or nystagmus may all be associated with vision problems or intracranial pathology and, if observed, should result in prompt referral of the child to an ophthalmologist.

A formal assessment of acuity should be attempted on each child who presents with a possible vision problem and the method undertaken depends on the age of the child and the equipment available.

Babies

Fixing and following faces or bright attention-grabbing targets indicate whether the child is visually alert. Babies

usually develop this visual response by the age of 8 weeks. Other important components of the examination of a baby include an observation of ocular alignment and use of an ophthalmoscope to assess the red reflex in each eye. Failure to fix and follow after the age of 8 weeks, the presence of any ocular misalignment (strabismus) after the age of 4 months and the presence of a dull, absent or pale red reflex at any age is abnormal and requires immediate referral of the child.

Preverbal children

In the GP's clinic setting, a preverbal child's ability to discriminate small objects can be assessed by testing his or her ability to fixate upon and follow toys of various sizes. The '100s and 1000s' method is used to grossly determine a child's ability to discriminate tiny objects close to them. In this test, a cluster of 100s and 1000s cake decorations are held in the examiner's hand. If the child can see

them he or she will usually reach for them and pick them up. Another subjective test is to assess the child's objection to ocular occlusion: a child with poor vision in one eye usually objects when the eye with good vision is occluded.

In the ophthalmic clinic setting, objective monocular preferential-looking tests such as the Teller acuity (see Figure 1a) and Cardiff acuity (see Figure 1b) cards can be used and are based on the principle that a child will look towards a picture or a pattern, rather than a blank space, if his or her acuity allows the child to discriminate the image from its background. The examiner is required to determine if the child looks directly at the picture or pattern, as the child will lose interest and give an indefinite response at the point where the picture or pattern becomes too small for him or her to see.

Verbal children

In verbal children, an objective measurement of visual acuity may be possible. In a child aged 2 to 3 years, the recommended test is the Kay picture test (see Figure 1c) or Lea symbols test (see Figure 1d). Both tests can be performed monocularly and assess vision at either 3 or 6 metres. The Kay picture test requires the child to name the object in the picture whereas the Lea symbols test allows the child to match what they see to a picture or letter board. A matching test is particularly good for shy children who may see the picture or letter but are not willing to verbalise what they see.

For children aged 3 to 4 years the Sheridan Gardiner test should be used (see Figure 2) and is performed monocularly. In this test, the child is shown a single letter or line of letters and the child either verbalises or matches what they see on a letter board that is held by the child. With the impending age change from 4 to 3 years of age for the 'Healthy Kids Check', GPs may find they need to be familiar with and have the equipment for a variety of visual acuity tests.

IMPORTANT SIGNS TO LOOK FOR

Vision problems in children may manifest in an abnormal head posture, nystagmus, strabismus, abnormal ocular movements, pupil abnormalities or loss of the red reflex. It is important to assess for these features in the child with a suspected vision problem.

Abnormal head posture

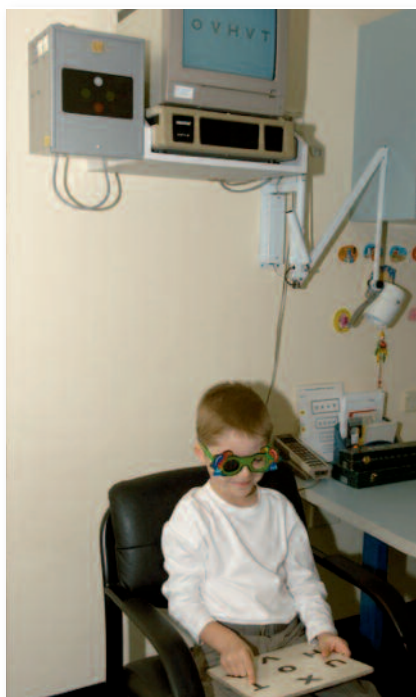A child may develop an abnormal head posture to maintain binocular single vision in the context of a paralytic nerve palsy or some strabismus syndromes.

Nystagmus

Congenital nystagmus manifests around the age of 6 weeks. These children have good near vision. Nystagmus can be associated with childhood strabismus syndromes, be a consequence of impairment of central vision or indicate serious intracranial pathology. Any new-onset nystagmus warrants immediate referral of the child to an ophthalmologist for further assessment.

Strabismus

Strabismus, or ocular misalignment, may be a cause or a consequence of visual impairment in a child. Any strabismus

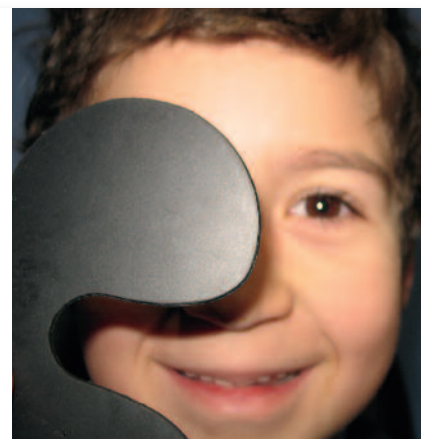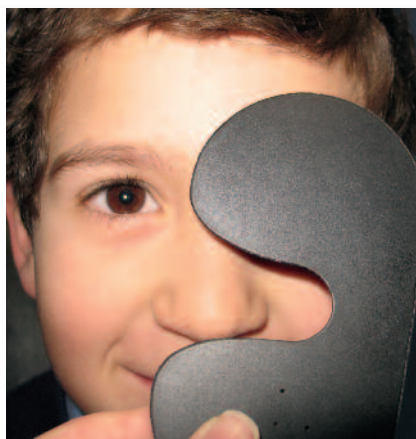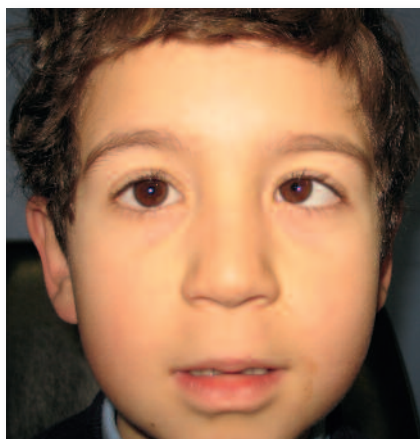


Figures 2a and b. The Sheridan Gardiner letter matching visual acuity test. This is the most appropriate visual acuity test for preschool-aged children. a (left). The child is shown a single letter or line of letters on the Snellen chart and (b, above) they either verbalise or match what they see on a letter board that they hold.

after the age of 4 months is abnormal. A large angle misalignment may be detected with corneal light reflex test ('the Hirschberg test'). In this test, a bright light is shone into the eyes from arm's length while the child looks at the light. If the eyes are properly aligned, the position of the reflection of the light in the cornea

will be symmetrical. If there is ocular misalignment, the reflection will be more or less within the pupil centre in the eye fixating the light and deviated temporally in an esotropic (in-turning) eye or nasally in an exotropic (out-turning) eye.

The gold-standard test for the diagnosis of strabismus is the cover/uncover test



Figures 3a to c. The cover/uncover test. a (above left). The child has a left esotropia. b (above centre). On covering the left eye, the right eye will be observed not to move. c (above right). On covering the right eye, the left eye will be observed to move temporally to take up fixation. This test should be performed with the child fixing on a near target (about 33 cm away) and again at a distance target (about 6 m away).

PERFORMING THE COVER/ UNCOVER TEST

- Step 1. Hold an object about 33 cm from the child's eyes and ensure he or she is fixating on it.
- Step 2. As you apply a cover over one eye, watch the uncovered eye to assess whether it has to move to take up fixation. (An esotropic eye will have to move in a direction away from the nose to take up fixation. An exotropic eye will have to move in a direction towards the nose to take up fixation.)
- Step 3. Remove the cover from the first eye and ensure the child is still fixating upon the object you are holding.
- Step 4. Apply the cover to the second eye and again watch the uncovered eye to assess whether it has to move to take up fixation. In a well-performed cover/uncover test, any movement of the uncovered eye to take up fixation is abnormal and indicates ocular misalignment.

(Figure 3). This test requires no specialised equipment but does require a degree of interest and co-operation from the child being examined. In its simplest form, the cover/uncover test has four steps and should be performed with the child looking at a near target and also at a distance target (see the box on this page for steps on how to perform this test).

Abnormal pupillary light reflexes

An abnormal pupillary light reflex indicates either gross unilateral intraocular retinal pathology (such as a retinal detachment or extensive intraocular tumour) or an intracranial abnormality such as an optic nerve lesion or raised intracranial pressure.

Loss of the red reflex

Assessing the red reflex is important to rule out intraocular causes of impaired vision. Life-threatening conditions such

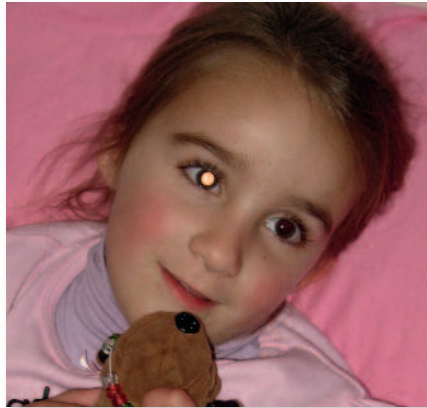

Figure 4. Loss of red reflex in the left eye. The red reflex (as it would be observed through an ophthalmoscope) is bright and reflective in the right eye and very dull in the left eye. An appearance such as this may represent retinoblastoma, which is potentially life threatening and mandates immediate referral to an ophthalmologist for assessment.

as retinoblastoma and vision-threatening problems such as cataract may present with loss of the red reflex (Figure 4).

CAUSES OF REDUCED VISION

Amblyopia

Amblyopia may be defined as defective vision whereby the acuity is diminished by a line or more in an otherwise normal eye and cannot be corrected with glasses. It develops when the visual information provided to the brain from one eye is inferior to or conflicts with that provided by the other eye.

If the condition is treated early, when the afferent visual pathway is still quite plastic, it may be completely reversible. Early detection is therefore the key in determining a successful outcome.

Amblyopia may occur for several reasons including refractive error (particularly anisometropia), strabismus or occlusion from ptosis or cataract. Importantly, any severe occlusion that onsets in the neonatal period will cause irreversible amblyopia if not diagnosed and treated within several weeks.

Refractive error

Refractive error affects 5 to 18% of children in Australia.¹⁻³ It is quite normal for children to be a little hypermetropic and a mild degree of refractive error is tolerable and should not necessarily be corrected. As a general rule, children with hypermetropia need full-time corrective lenses if their refractive error is greater

than four dioptres. Very young children can tolerate larger degrees of myopia but as a general rule a school-aged child with myopia of greater than one dioptre should wear corrective lenses in the classroom.

Strabismus

Strabismus is misalignment of the two eyes such that only one eye is directed at an object of regard at any one time.

Esotropia

Esotropia may be either infantile or accommodative. Management of this condition is likely to involve glasses, surgery and careful management of amblyopia. Infantile esotropia presents within the first six months of life whereas accommodative esotropia usually presents in children aged 2 years and above, and may initially be intermittent (such as when the child is tired or unwell).

Intermittent exotropia

Intermittent exotropia usually presents in preschool or school-aged children. It is typically intermittent and tends to be more obvious when the child is unwell or tired. Looking into the far distance or inattention (day dreaming) will often worsen the exotropia. Treatment of intermittent exotropia may involve glasses, part-time occlusion or exercises prescribed and supervised by an orthoptist. Surgery may be considered if these measures fail to control the problem.

Paralytic strabismus

Paralytic strabismus, most commonly a sixth nerve palsy, may manifest as a sudden-onset esotropia and children may complain of double vision (diplopia). Although most sixth nerve palsies are viral in origin, it is important to look for optic disc swelling because it may also be the result of raised intracranial pressure. Fourth nerve palsies may be congenital (usually manifesting as an abnormal head posture) or acquired (usually after head trauma) and usually result in a hyperopia (upward deviation) of the affected eye. In this instance, the child's parent will often report the precise circumstances in which they have noticed the child squinting. In fact, it is most commonly seen if the child is looking up and to the side opposite the fourth nerve palsy.

Ptosis

Congenital ptosis may be unilateral or bilateral. Children with a marked bilateral ptosis may lift their chin to 'clear' the visual axis. This condition is often associated with refractive error and sometimes with a defective upgaze.


If the ptosis obscures the visual axis and is interfering with visual development, early surgery is indicated. If the ptosis is primarily a cosmetic issue, surgery is best performed when the child is older. Refractive error and management of amblyopia is also very important in these children.

Retinoblastoma

Retinoblastoma is a rare but potentially devastating condition, affecting 11.8 per million children aged between 0 and 4 years.⁴ It presents before the age of 3 years in 75% of cases and is bilateral in 25% of cases. It may present in a variety of ways: strabismus, loss of the red reflex, leukocoria (a descriptive term for a 'white pupil') or an enlarged or cloudy cornea due to intraocular inflammation and secondary glaucoma.

Management of children with retinoblastoma may include local ocular

therapy such as cryotherapy or enucleation and frequently systemic or local chemotherapy. This is best carried out in a dedicated paediatric facility. Family genetic counselling is also important because some cases are heritable.



Cataract

Congenital cataract occurs in about one in 3000 live births and two thirds of these cases are bilateral. Most cases are inherited in an autosomal dominant pattern, but congenital cataract may also be associated with chromosomal abnormalities, metabolic disease or intrauterine infection.

Early detection and management is essential for a good visual outcome. If the cataract is visually significant, management usually involves surgical removal followed by refractive correction (either with a contact lens or glasses). Postsurgical management is critical and aggressive, protracted amblyopia management is essential.

CONCLUSION

A vision problem in a child is an uncommon but important reason for presentation to a GP. As vision problems may indicate underlying intraocular or intracranial pathology, being able to


assess the visual system at presentation is important. In particular, a sudden-onset strabismus, nystagmus, loss of the red reflex and pupil abnormalities are of particular concern. A vision problem arising from amblyopia for any reason is potentially reversible and the best results are achieved with early diagnosis and management. **MT**

REFERENCES

1. Ip JM, Rose KA, Morgan IG, Burlutsky G, Mitchell P. Myopia and the urban environment: findings in a sample of 12-year-old Australian children. *Invest Ophthalmol Vis Sci* 2008; 49: 3858-3863.
2. Ip JM, Robaei D, Kifley A, Wang JJ, Rose KA, Mitchell P. Prevalence of hyperopia and association with eye findings in 6- and 12-year-olds. *Ophthalmology* 2008; 115: 678-685.e1.
3. Huynh SC, Kifley A, Rose KA, Morgan IG, Mitchell P. Astigmatism in 12-year-old Australian children. Comparisons with a 6-year-old population. *Invest Ophthalmol Vis Sci* 2007; 48: 73-82.
4. Broaddus E, Topham A, Singh A. Incidence of retinoblastoma in the United States: 1975-2004. *Br J Ophthalmol* 2009; 93: 21-23.

COMPETING INTERESTS: None.

Online CPD Journal Program



What tests are used to assess vision in preverbal children?

Review your knowledge of this topic and earn CPD/PDP points by taking part in **MedicineToday's** Online CPD Journal Program.

Log in to

www.medicinetoday.com.au/cpd