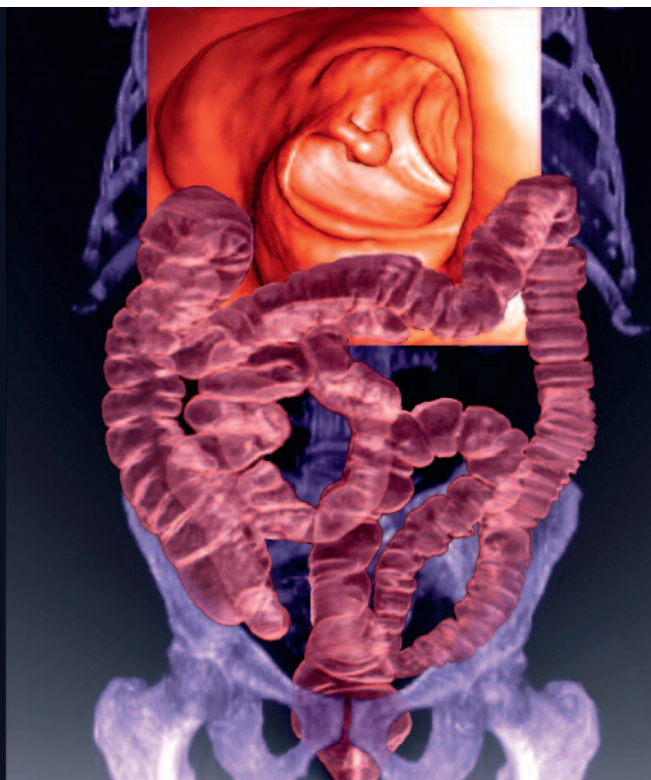


Endoscopic management of large colonic polyps

JOSH BUTT MB BS

GREGOR J. BROWN MB BS, PhD, FRACP



Most large colonic polyps can now be assessed and removed endoscopically, avoiding the need for surgical resection.

MedicineToday 2012; 13(10): 66-68

Dr Butt is Endoscopy Fellow, and Associate Professor Brown is a Gastroenterologist and Head of Endoscopy at the Alfred Hospital, Melbourne, Vic.

SERIES EDITOR: Associate Professor Simone Strasser, MD, FRACP, Clinical Associate Professor, Central Clinical School (Medicine), University of Sydney; and Senior Staff Specialist, AW Morrow Gastroenterology and Liver Centre,

Royal Prince Alfred Hospital, Sydney, NSW.

The views published in this Series are those of the authors and not necessarily indicative of those held by all members of the Digestive Health Foundation or GESA.



REMEMBER

- Most colorectal cancers arise from colonic polyps. Unsurprisingly, polypectomy has been shown to reduce both the expected incidence and mortality of colorectal cancer.^{1,2}
- Large (20 mm or more) colonic polyps are relatively uncommon; over 90% of polyps detected at colonoscopy are 10 mm or less.
- In the past, patients with large polyps were referred for surgical resection because safe and effective endoscopic polypectomy techniques were not available.
- With modern endoscopic techniques virtually any benign polyp can now be safely and completely removed at day-procedure colonoscopy.
- Given the ability to remove even very large colonic polyps endoscopically, the risk of malignancy is the main determinant of whether surgery is required.

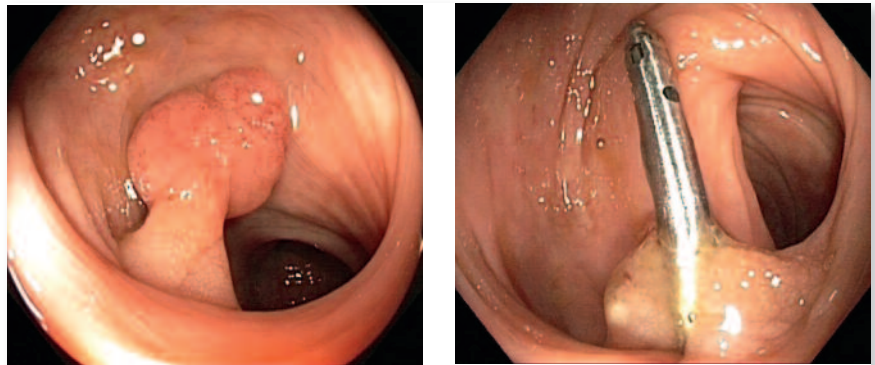
ASSESSMENT

- Polyps may be broadly classified as either pedunculated (with a stalk) or sessile (flat or broad based). This determines the method of endoscopic resection.
- The likelihood of malignancy can be predicted by analysis of polyp morphology, crypt architecture and vascular patterns, using the enhanced optics of modern endoscopes.

- Although biopsy of polyps is also helpful in determining whether the polyp is benign or malignant, histological analysis of complete polypectomy specimens ('the big biopsy') is most accurate.

MANAGEMENT

- Complete polyp resection is crucial to minimise polyp recurrence. Thermal ablative approaches are inadequate and provide no tissue for histological examination.
- Large pedunculated polyps are generally removed with simple snare resection through the stalk. Clips or loop ligators can be applied to the stalk to minimise bleeding (Figures 1a and b).
- Removal of sessile lesions over 20 mm requires specific techniques, including endoscopic mucosal resection and endoscopic submucosal dissection. These techniques require specialised training.
- Endoscopic submucosal dissection involves the use of an electrosurgical knife to resect lesions en bloc; however, the procedure is time consuming, carries greater risk and is generally not used for removing colonic polyps in Australia.
- Surgical resection is appropriate for lesions likely to be malignant or



Figures 1a and b. Resection of a pedunculated colonic polyp. a (left). The polyp before resection. b (right). After resection. A clip has been placed on the base of the stalk to minimise the risk of postpolypectomy bleeding.

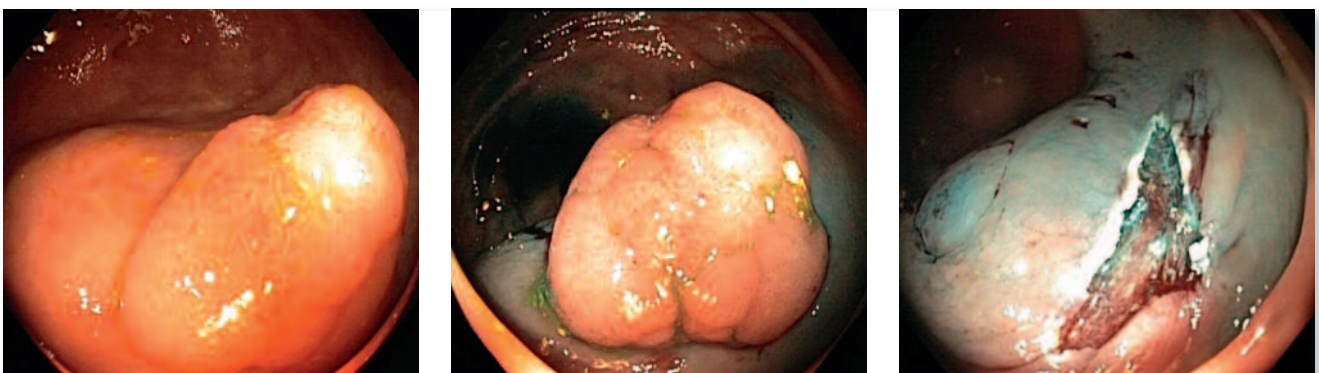involving structures that make endoscopic removal difficult (such as the ileocaecal valve, the appendix or diverticula), or where the necessary endoscopic expertise is not available to perform endoscopic mucosal resection.

ENDOSCOPIC MUCOSAL RESECTION

- Endoscopic mucosal resection is now commonly performed in major centres throughout Australia. Its safety and efficacy are proven, and it does not require expensive or highly specialised equipment. The procedure takes approximately 30 minutes (longer for larger lesions). The patient is usually

discharged on the same day.

- A fundamental component of endoscopic mucosal resection is the injection of a submucosal cushion of fluid to elevate the polyp-affected mucosa (Figures 2a to c). This minimises the risk of perforation and deep thermal injury.
- Polyps that do not 'lift' indicate either malignancy (requiring surgery) or submucosal fibrosis (with higher risk of complications).
- Methylene blue is usually added to the injectate; this preferentially stains the submucosal layer and is helpful in identifying the submucosal plane, the polyp margin, residual adenoma and



Figures 2a to c. Endoscopic mucosal resection of a sessile colonic polyp. a (left). The polyp before resection. b (centre). The polyp after injection to create a submucosal cushion (blue-coloured area). c (right). After resection.

inadvertent deep resection.

- A snare is used to resect the elevated lesion, with the number of snared pieces increasing with the size of the lesion.
- A follow-up colonoscopy to check the polypectomy site is generally undertaken three to four months later. Recurrence of the polyp is uncommon but, if present, is usually small and easily treated endoscopically.³
- There are now prospective data from a large Australian multicentre study of endoscopic mucosal resection of sessile lesions larger than 20 mm:
 - successful excision with endoscopic mucosal resection was 91%³
 - significant postpolypectomy bleeding occurred in 6% of patients, with 15% of these requiring a blood transfusion (unpublished data)
 - the risk of perforation was 1.3%; most cases occurred without peritoneal soiling, and most were managed with endoscopic clips, antibiotics and observation, rather than surgery⁴
 - there were no deaths.
- Compared with surgery, endoscopic mucosal resection for larger sessile polyps results in major health savings – calculated in one study to be about US\$7000 (A\$7000) per person and six bed days.⁵

CONCLUSION

Large colonic polyps can now be assessed and removed endoscopically, avoiding the need for surgical resection in most cases. **MT**

REFERENCES

1. Zauber AG, Winawer SJ, O'Brien MJ, et al. Colonoscopic polypectomy and long-term prevention of colorectal-cancer deaths. *N Engl J Med* 2012; 366: 687-696.
2. Winawer SJ, Zauber AG, Ho MN, et al. Prevention of colorectal cancer by colonoscopic polypectomy. The National Polyp Study Workgroup. *N Engl J Med* 1993; 329: 1977-1981.
3. Moss AWS, Hourigan LF, Brown GJ, et al. Long term recurrence following wide field endoscopic mucosal resection (WF-EMR) for advanced colonic mucosal neoplasia – results of the Australian Colonic EMR (ACE) Multicenter Prospective Study of 940 patients [abstract]. *Gastrointest Endosc* 2012; 75 (4 Suppl): AB177.
4. Moss A, Bourke MJ, Williams SJ, et al. Endoscopic mucosal resection outcomes and prediction of submucosal cancer from advanced colonic mucosal neoplasia. *Gastroenterology* 2011; 140: 1909-1918.
5. Swan MP, Bourke MJ, Alexander S, Moss A, Williams SJ. Large refractory colonic polyps: is it time to change our practice? A prospective study of the clinical and economic impact of a tertiary referral colonic mucosal resection and polypectomy service (with videos). *Gastrointest Endosc* 2009; 70: 1128-1136.

COMPETING INTERESTS: Dr Butt: None.

Professor Brown has had travel costs to speak at conferences reimbursed by Olympus. He has not been paid for this.



Ask an expert

Puzzled by a presentation? Is the diagnosis a dilemma? What would a specialist in the relevant field do? Send us your baffling or hard-to-treat general practice cases for consideration in our 'Clinical case review' series. The case synopsis should be no longer than 150 words and include one or two specific questions that you want answered. Write to: Medicine Today, PO Box 1473, Neutral Bay, NSW 2089, or editorial@medicinetoday.com.au