

Retinal tear and detachment

The need for early diagnosis

ANDREW CHANG MB BS, PhD, FRANZCO, FRACS

MedicineToday 2014; 15(1): 54-57

Flashing lights, visual floaters and a shadow in the peripheral visual field may indicate a retinal detachment. Early diagnosis and referral of patients for diagnosis and surgical treatment are essential to prevent blindness.

WHAT IS THE RETINA AND VITREOUS?

The retina is the light-sensitive neural layer lining the inside of the back of the eye, which is like the 'wallpaper inside a room' (Figure 1). It is similar to photographic film in a camera and 'sees' the image formed by the front of the eye. The centre of the retina is called the macula, which is responsible for fine central reading sight. The vitreous is a clear, jelly-like fluid (resembling egg-white) that fills the inside of the eye and is attached to the retina at certain parts of the eye. These include the optic nerve, macula, and peripheral retina near the ciliary body where areas of retinal thinning called lattice degeneration can be found. Lattice degeneration occurs in 10% of the general population.

WHAT IS A RETINAL DETACHMENT?

A retinal detachment occurs when the retina lifts away from its normal position against the inside of the back of the eye. The detached retina loses function because it is deprived of its blood supply and thus source of nutrition. This results in loss of vision in the area of the retinal detachment.

Dr Chang is a Vitreoretinal Surgeon at Sydney Retina Clinic and Day Surgery (www.sydneyretina.com.au), and Consultant Surgeon at Sydney Eye Hospital, Sydney, NSW.

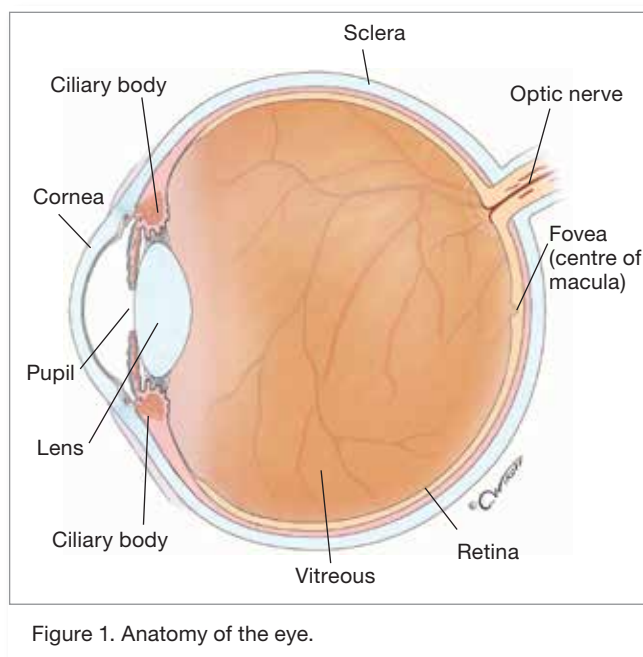


Figure 1. Anatomy of the eye.

© CHRIS WIKOFF

WHAT CAUSES A RETINAL DETACHMENT?

The vitreous consists of a collagen network with fluid in between. With age, the vitreous becomes more of a fluid than a gel due to loosening of the collagen framework. This results in 'sloshing' of the vitreous gel with eye movement. Ultimately, the vitreous separates from its attachment to the inner surface of the retina. This is termed a vitreous detachment (Figure 2).

In most cases a vitreous detachment does not result in significant visual problems; however, in some areas of the eye, the vitreous may have a strong attachment to the retina, and the vitreous traction may be significant enough to tear the retina. The fluid inside the eye then passes through the retinal tear and lifts the retina off the back of the eye. Figure 3 shows a temporal retinal detachment, which is like wallpaper peeling off the wall. Untreated, the retina will usually detach totally from the wall with resulting blindness. Figure 4 shows a more severe retinal detachment with puckering and scarring of the retina.

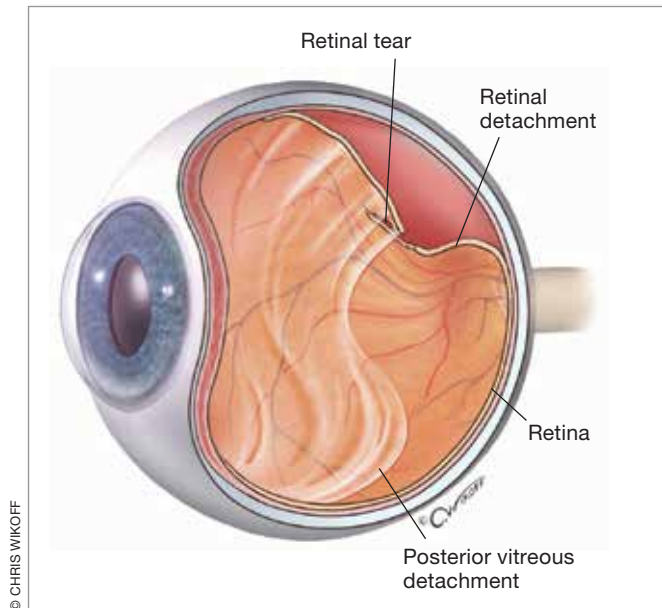


Figure 2. Vitreous detachment causing a retinal tear and subsequent retinal detachment.

A retinal tear and detachment may also result in bleeding into the interior of the eye. This is termed a vitreous haemorrhage.

WHO IS AT RISK OF A RETINAL TEAR?

A person's risk of retinal detachment may be increased if he or she has:

- near-sightedness (myopia)
- had a previous retinal detachment in the other eye
- a family history of retinal detachment

- had previous injury to the eye
- weak areas in the retina (lattice degeneration) where the retina is thinned and the vitreous gel is more adherent to the retina.

WHAT ARE THE IMPORTANT SYMPTOMS?

The perception of flashing lights (photopsia) indicates traction on the light-sensitive retina. The typical symptoms are brief lightening flashes usually seen in the dark and with rapid head or eye movement.

Floater result from the collapse of the vitreous gel. They are areas of condensed collagen fibrils. Patients may find the floaters more noticeable when they are looking at a white-coloured background. Larger floaters may indicate vitreous haemorrhage.

Flashes and floaters will be present in patients who have a posterior vitreous detachment. The symptoms may be very transient or last several months. The duration correlates with the degree of vitreous traction on the peripheral retina.

A peripheral enlarging area of non-sight (scotoma) is the classic symptom of a retinal detachment. Superior detachments associated with an inferior visual field defect usually progress more rapidly. Untreated, a small retinal detachment will progress to a total separation of the retina, including the macula. This results in complete blindness.

WHEN SHOULD PATIENTS BE REVIEWED?

In most patients a vitreous detachment remains uncomplicated and is not vision threatening; however, about 10% of vitreous detachments may be associated with a vitreous haemorrhage, retinal tear or retinal detachment. Patients with a vitreous detachment should therefore be reviewed one to two weeks after the initial diagnosis.

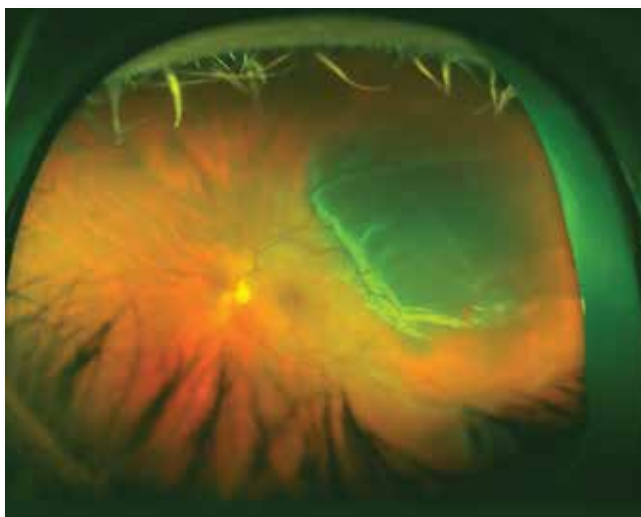

Figure 3. Wide-angle photograph of a temporal retinal detachment.

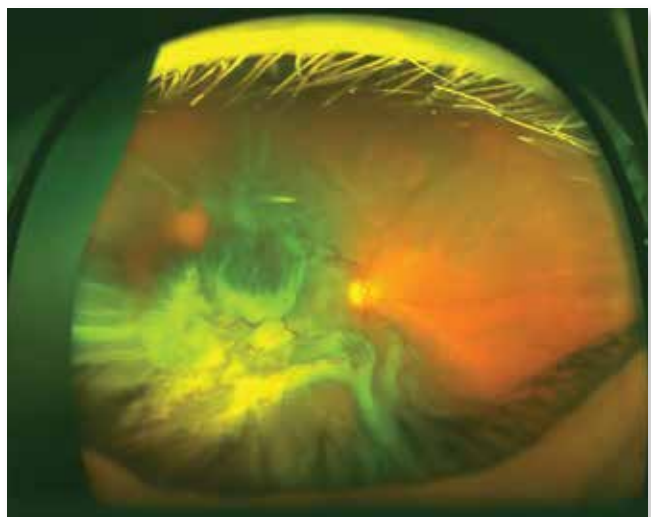
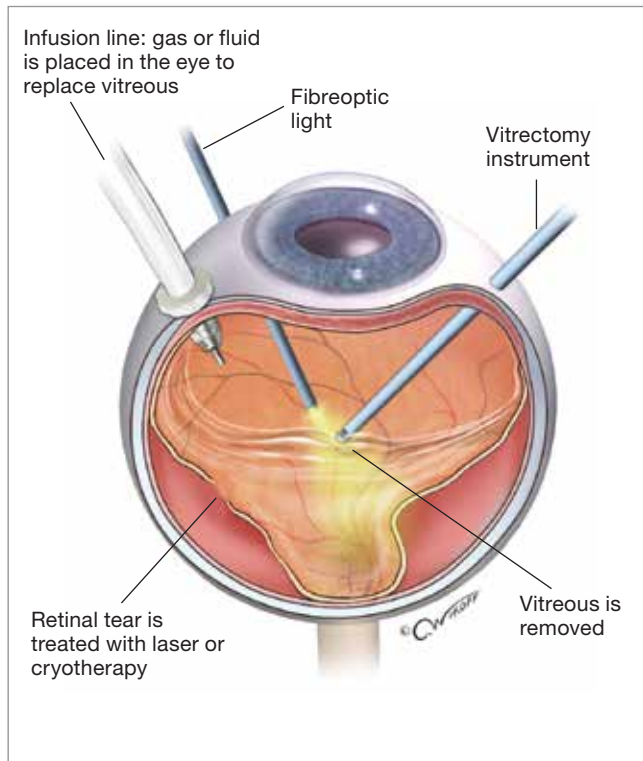
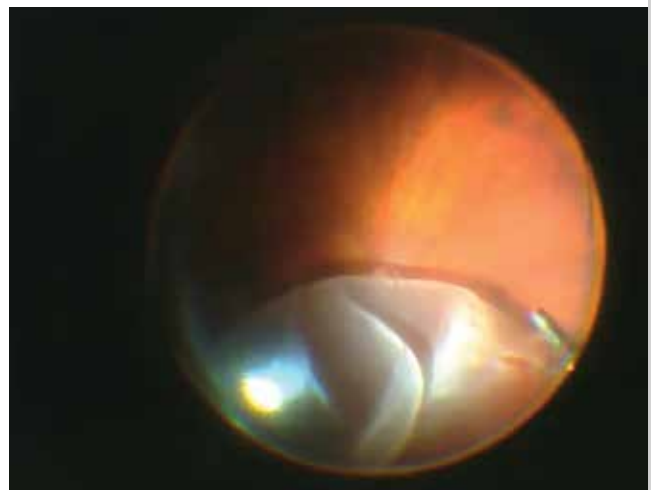
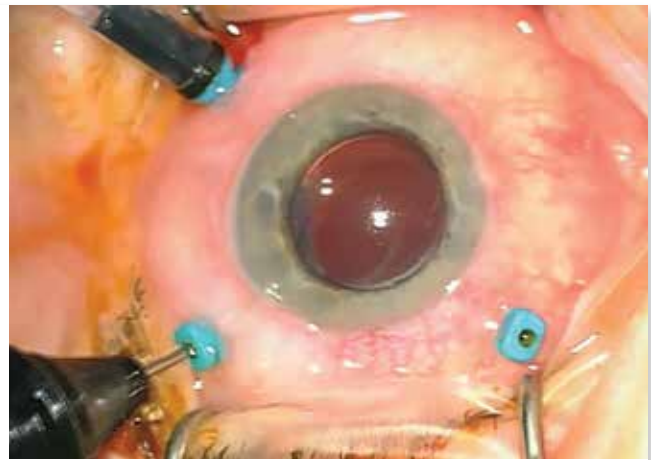


Figure 4. Wide-angle photograph of an extensive retinal detachment with scarring.



© CHRIS WIKOFF



Figures 5a to c. a (above). Illustration of vitrectomy surgery. b (top right). Surgical view of the vitrectomy set up. c (right). Surgical view of the interior of the eye during vitrectomy.

It is important to educate patients with a vitreous detachment on the symptoms of retinal detachment and to ensure that they seek attention urgently if symptoms change. They should be warned to look out for:

- new or increased amount of flashes and/or floaters
- development of a scotoma
- reduced central visual acuity.

WHEN SHOULD PATIENTS BE REFERRED?

Patients should be referred for further assessment if they have any of the following:

- persisting symptoms of photopsia and floaters
- blood or pigment cells in the vitreous, which may suggest a retinal tear or detachment
- a high risk of having a retinal detachment – e.g. have a past or family history of retinal detachment, high myopia or previous ocular trauma
- extensive lattice degeneration.

HOW IS A RETINAL DETACHMENT DIAGNOSED?

Retinal tears and detachment are diagnosed on clinical

examination using slit lamp bimicroscopy and fundus lenses. Such examination will reveal even very small retinal tears or detachment. B scan ultrasonography is used to demonstrate the position and mobility of the vitreous. In some patients the visual field loss resulting from retinal detachment will be diagnosed on visual field testing.

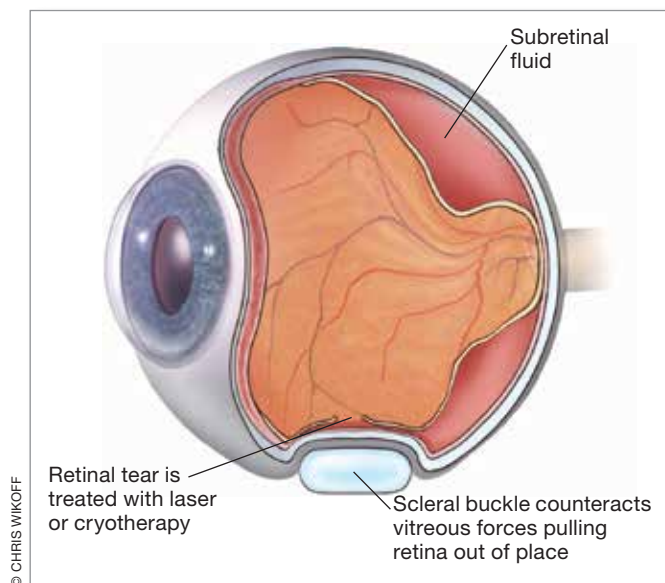
New wide-angle digital cameras are useful in photographing the peripheral retina helping to identify areas of retinal weakness, tears, holes and retinal detachment.

HOW ARE TEARS AND DETACHMENTS TREATED?

Retinal tears

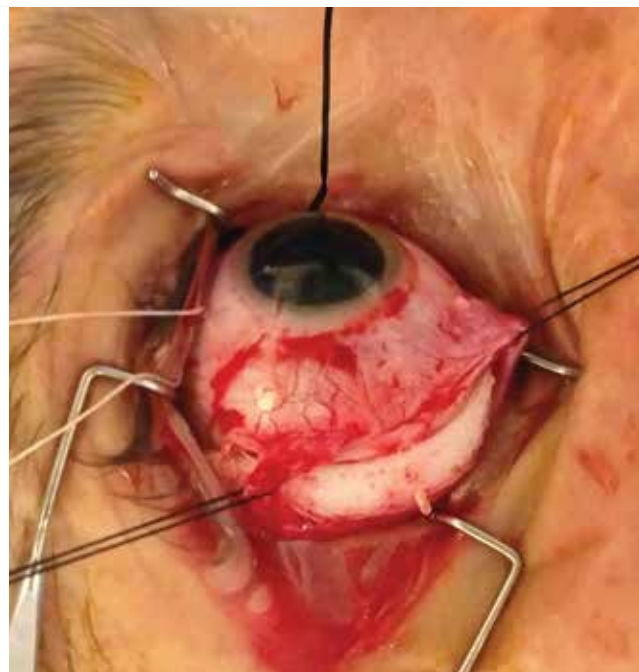
Retinal tears are usually treated in a clinic using laser photocoagulation. The aim of the laser treatment is to ‘encircle’ the area of the tear with laser burns that then induce the formation of small scars, thereby attaching the retina more securely to underlying tissue.

If the tears are obscured by vitreous haemorrhage, have surrounding subretinal fluid or are located too anteriorly, patients may need treatment with cryotherapy, which is undertaken in an operating theatre.



© CHRIS WIKOFF

Figures 6a and b. a (above). Illustration of scleral buckle surgery. b (right). Surgical view of scleral buckle surgery.



Retinal detachment

There are several ways to repair a retinal detachment, depending on the characteristics of the detachment. In each of the methods below, the surgeon locates the retinal tear and seals it using laser surgery or cryotherapy.

Vitreotomy surgery

Vitreotomy surgery is a microsurgical keyhole surgery technique in which the retinal detachment is repaired internally (Figures 5a to c). The vitreous gel, which is pulling on the retina, is removed from the eye and usually replaced with a gas bubble. The vitreous reforms and gradually replaces the gas bubble.

In cases of advanced retinal detachment, where long-term pressure on the retina is required to keep the retina in position, silicone oil or heavy liquid may be used in place of the gas bubble. In such cases, a second operation is required to remove the oil once the retinal position has stabilised.

Scleral buckle surgery

In scleral buckle surgery a silicone band (the scleral buckle) is placed around the outside of the eye to counteract the vitreous force pulling the retina out of place (Figures 6a and b). This pushes the 'wall against the wallpaper'. The surgeon drains the fluid under the detached retina from the eye, repositioning the retina against the inside of the eye. In some cases a gas bubble is placed in the vitreous cavity to tamponade the retina.

Special care after surgery

Patients need to administer eye drops, typically antibiotic and corticosteroid and a cycloplegic/dilating drop for several weeks

after the surgery, in a tapering fashion.

If a gas bubble was placed in the eye, the patient may be required to maintain a certain head position for several days so that the gas places pressure on the area of retinal detachment ('putting the bubble on the trouble'). The gas bubble gradually reabsorbs and disappears over days to weeks, depending on the type of gas used. Patients can hire a special chair to make this positioning more comfortable. It is routine for such patients to wear a wrist brace to warn medical staff against administering nitrous oxide while gas remains in the eye, which could cause the gas to expand. As the gas can also expand with altitude, patients should not fly in an aeroplane or travel to high altitudes until the gas bubble is reabsorbed. A rapid increase in altitude may cause a dangerous rise in eye pressure.

WILL VISION IMPROVE?

It may take many months for a patient's vision to improve, depending on the extent of the initial retinal detachment. If the macula is involved, recovery of fine central vision is usually limited. Therefore, it is important to diagnose and treat the retinal detachment before the macula is damaged. Timely surgery and modern techniques allow the repair of even complex retinal detachments with recovery of vision.

KEYPOINT

Public awareness of retinal detachment is limited and it is thus important to raise awareness of this condition so that patients seek immediate care when symptoms develop. MI

COMPETING INTERESTS: None.