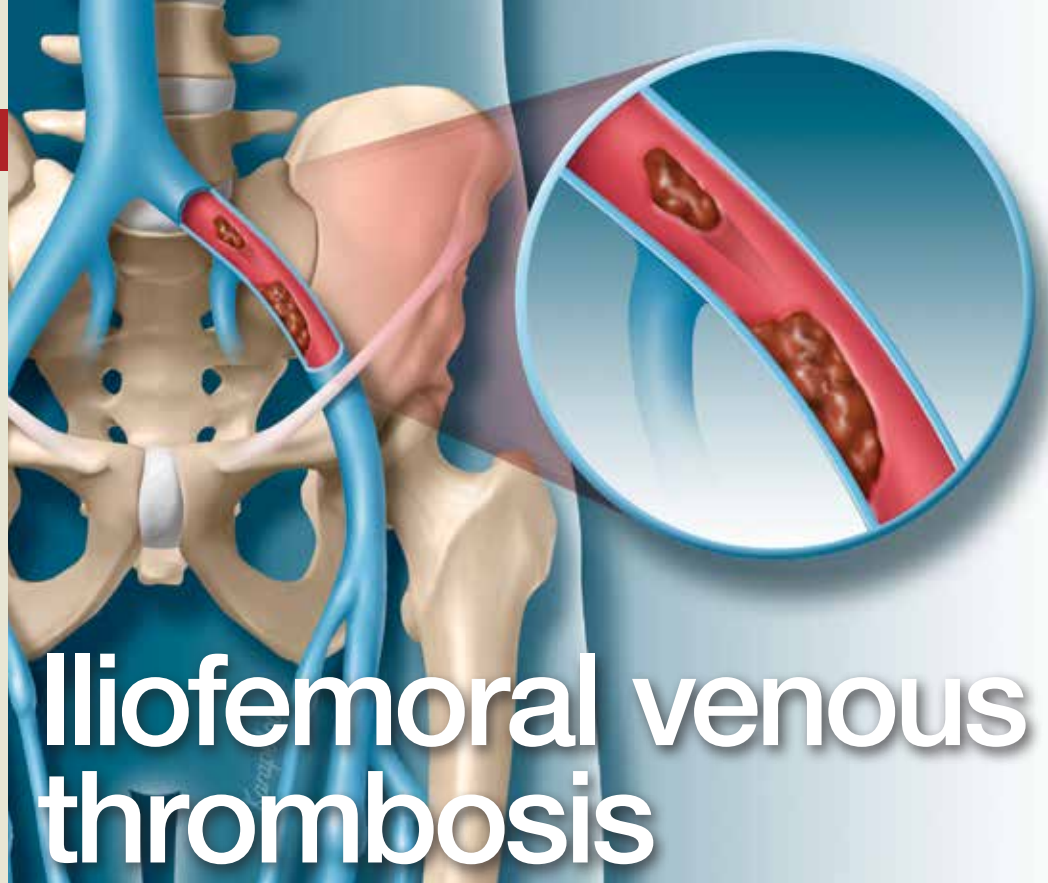

Iliofemoral venous thrombosis

Key points

- Patients with iliofemoral deep venous thrombosis (DVT) may have a more severe spectrum of presentations than those with more distal DVT.
- Post-thrombotic syndrome is more common after iliofemoral DVT than after more distal DVT.
- Early intervention to remove an iliofemoral thrombus and correct underlying anatomical abnormalities, as well as anticoagulation, may help improve long-term outcomes.
- Options for thrombus removal include catheter-directed thrombolysis and pharmacomechanical or surgical thrombectomy.
- In patients with chronic venous problems after iliofemoral DVT, newer endovascular interventions may improve symptoms.

Developments in management

DAVID ROBINSON MA, FRACS

Iliofemoral deep venous thrombosis (DVT) poses a higher risk of ongoing problems than more distal DVT. In selected patients, early treatment with thrombus removal as well as anticoagulants may significantly reduce the incidence of post-thrombotic syndrome. In patients with chronic iliofemoral obstruction, newer endovascular approaches offer promising results.

Management of deep venous thrombosis (DVT) aims to prevent both short- and long-term complications – pulmonary emboli and post-thrombotic syndrome, respectively. DVT involving the iliofemoral venous segment (i.e. between the inferior vena cava and common femoral vein) carries a higher risk of ongoing problems than more distal DVT. These problems are mainly related to post-thrombotic syndrome, caused by destruction of the venous valves and luminal occlusion and obstruction, and manifest as ulceration and venous claudication.

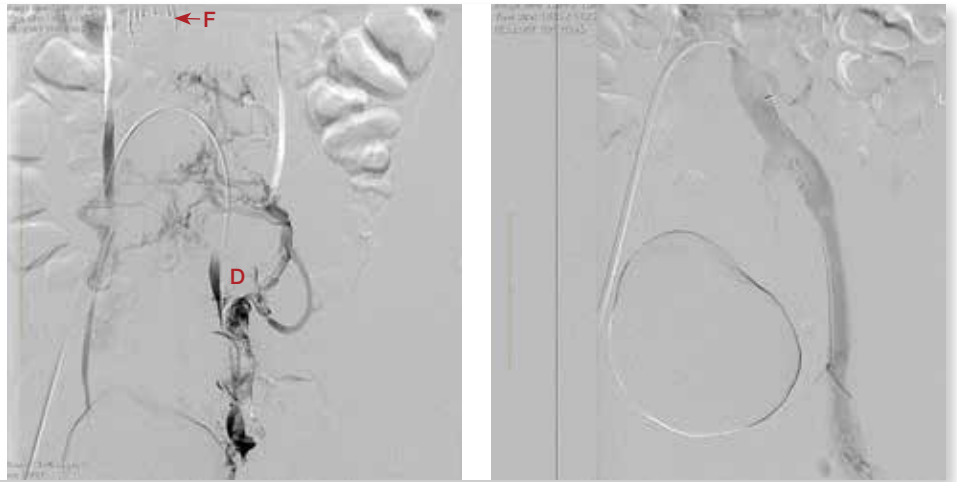
If iliofemoral DVT is treated early with a view to preserving valvular function and the lumen of the vein, the incidence of these long-term consequences can be significantly reduced. Even in patients who present with a chronic venous problem, there are treatments that can often improve their symptoms. This article discusses developments in the management of iliofemoral venous problems.

DIAGNOSIS

DVT involving the iliofemoral segment usually presents in the same fashion as more distal

Dr Robinson is a Vascular Surgeon at Royal Prince Alfred Hospital, Sydney Adventist Hospital, Macquarie University Hospital and Mater Hospital, Sydney, NSW.

Figures 1a and b. Iliofemoral deep venous thrombosis (DVT) before and after catheter-directed thrombolysis in a middle-aged woman. a (right). Before thrombolysis, venography showed a filling defect (D) in the left iliofemoral vein, indicating a DVT. Surrounding collateral veins were distended. The tines of an inferior vena cava filter (F) are also visible. b (far right). Following catheter-directed thrombolysis, the filling defect has cleared.



DVT, with pain and swelling of the leg. However, these problems may be significantly worse in iliofemoral DVT, and a more severe presentation should raise suspicion that the DVT is more proximal. The spectrum of presentations culminates in the phenomenon of phlegmasia (total occlusion of the deep venous system), which may lead in severe cases to venous gangrene.

Generally in iliofemoral DVT, an initial duplex ultrasound scan (combining traditional and Doppler ultrasound) shows involvement of the femoral vein, with the proximal extent of the thrombosis not able to be seen. This should prompt a further, more-proximal duplex ultrasound scan to assess the extent of the thrombus more fully. If duplex ultrasound is unhelpful because of pain or technical issues such as body habitus then CT venography may be a useful adjunct. Although it is a relatively unusual study, CT venography is worth discussing with the radiologist to optimise the investigation.

PATHOPHYSIOLOGY

Left-sided DVT is more common than right-sided DVT. This is thought to be due at least in part to the anatomy of the ilio-caval confluence, with the left common iliac vein lying behind the aortic bifurcation and the right common iliac artery, compressed against the lumbar vertebra L5. Pathological compression is known as

May–Thurner syndrome (also known as iliac vein compression or Cockett syndrome), where the anatomical arrangement leads to scarring within the vein as a result of chronic trauma. This predisposes to thrombus formation, usually in combination with another provoking factor but occasionally without apparent explanation.

**TREATMENT
Anticoagulation**

In patients presenting with an acute iliofemoral DVT, initial treatment consists of anticoagulation as in any other case of DVT (i.e. initial parenteral anticoagulation changing over to warfarin, or alternatively one of the novel oral anticoagulants). The goals are to minimise thrombus extension and prevent emboli. However, anticoagulation will fail to resolve symptoms of pain and swelling in a significant number of patients, and some of these may benefit from more active intervention such as thrombolysis.

Thrombus removal

Treatment aimed at clearing an iliofemoral thrombus is indicated in patients who are:

- young
- active
- without contraindications to thrombolysis (e.g. recent surgery, previous intracranial haemorrhage, recent stroke or trauma).

Thrombus removal has the additional theoretical benefit of preserving venous valvular function. Options for removing thrombus from the iliofemoral segment include catheter-directed thrombolysis, pharmacomechanical thrombectomy and surgical thrombectomy. If thrombus removal is being considered for a patient with an iliofemoral DVT then referral to the local emergency department is usually appropriate.

Catheter-directed thrombolytic therapy

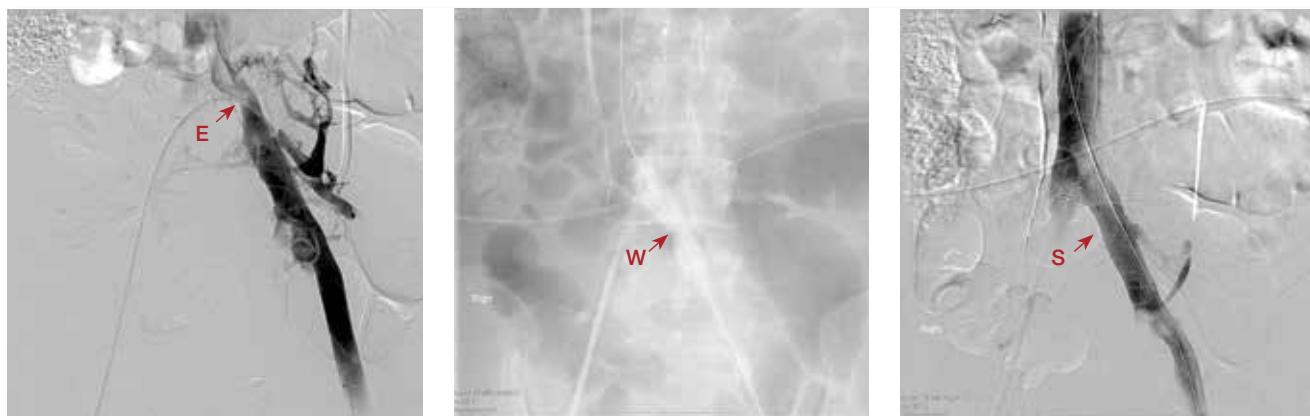Recent guidelines from the UK National Institute of Clinical Excellence (NICE) suggest considering catheter-directed thrombolytic therapy for patients with an iliofemoral DVT who satisfy the following criteria:

- symptom duration of less than 14 days
- good functional status
- life expectancy of at least one year
- a low risk of bleeding.¹

The basis of this recommendation is the recognition that early removal of thrombus may preserve valvular function and lead to better long-term health outcomes (Figures 1a and b).

Pharmacomechanical thrombectomy

Another treatment option is pharmacomechanical thrombectomy. Although mechanical forms of thrombectomy are very effective at removing a significant



Figures 2a to c. Stent insertion to treat venous stenosis that persisted after thrombolysis in the patient shown in Figure 1. a (left). Venography showed good clearance of the thrombus, but effacement (E) of the left common iliac vein and persistent filling of collateral veins indicated continuing venous stenosis. b (centre). An angioplasty balloon inflated in the left common iliac vein showed waisting (W), indicating the area of venous narrowing. c (right). After deployment of a stent (S), the collateral veins were no longer visible, indicating improved flow through the previously obstructed segment.

amount of the thrombus load, in practice some adjunctive pharmacological thrombolysis is almost always required. In patients who have a contraindication to thrombolysis, such as recent surgery, surgical thrombectomy can be considered.

Pharmacomechanical thrombectomy can be performed using several different devices. Some devices use suction to generate a Venturi effect or to aspirate the thrombus, whereas others use simple mechanical disruption or ultrasound. Evidence supporting one device over another is scanty at present, and therefore regional usage depends on familiarity with a particular device.^{2,3}

Minimising treatment complications

Thrombus removal via any of the means discussed above carries the risk of embolisation, and therefore patients usually have a retrievable inferior vena cava filter placed at the beginning of any intervention, with a view to removal in one to two weeks depending on clinical progress.

The other significant complication of thrombolytic therapy is major bleeding. Catheter-directed thrombolysis carries a much lower risk than systemic thrombolysis, with a major bleeding rate of 3 to 4% in recent series, mostly at the access site.

Patients at increased risk of bleeding would generally not be offered thrombolysis, although surgical thrombectomy may be an option.

Stent insertion

After treatment of the clot burden, an underlying anatomical abnormality such as May-Thurner syndrome is often discovered. Optimal treatment includes some form of intervention directed at this. Stenting is more effective than angioplasty because of the high residual elastic force of many of these lesions, and specific stents designed for the venous circulation have recently been made available to clinicians, with promising early results (Figures 2a to c).⁴

Long-term treatment

After successful acute treatment of an iliofemoral DVT with thrombus removal, long-term anticoagulation is recommended even if there is no residual thrombus. Duration depends on factors such as previous history, presence of a provocative lesion and extent of residual thrombus. During the initial phase, treatment is usually with intravenous heparin to allow close titration, but patients will later be transferred onto warfarin or, increasingly, newer alternatives such as rivaroxaban.

If a stent has been used, antiplatelet therapy is usually also indicated. However, the optimal duration of treatment is still unclear.

LONG-TERM OUTCOMES

Conservative treatment of iliofemoral DVT (anticoagulation alone) leads to a significant incidence of post-thrombotic syndrome and venous claudication, with quoted figures of at least 25 to 50%.⁵ These problems are usually caused by the extensive outflow obstruction seen with a proximal lesion, with obstruction of important collateral outflow channels such as the deep femoral vein.

There is some evidence to support the benefit of thrombolysis over short-term (two-year) follow up.⁶ In patients with successful thrombolysis there are quality of life benefits.⁷ There is less information about longer-term outcomes, although studies are ongoing. Another current area of research involves assessment of valvular function following thrombolysis.

Although some form of thrombus reduction in patients with a proximal DVT makes intuitive sense, and we have some early data to support its use in selected patients, there are still many questions that can be answered only by ongoing trials,

especially regarding the cost–benefit ratio of this therapy.

CHRONIC ILIOFEMORAL OBSTRUCTION

As noted above, patients who have received conservative treatment for an iliofemoral DVT may have significant ongoing problems caused by a residual obstructive lesion. This usually presents as either venous claudication or problematic oedema and ulceration. In these patients, it is worth considering intervention. Traditional surgical options such as crossover vein grafts have had poor long-term patency, and the morbidity of the procedure has often outweighed the benefit.

Newer endovascular approaches avoid much of the morbidity of surgical intervention and results are promising, although once again longer-term follow up is awaited. Iliac vein occlusions may be crossed using techniques borrowed from the arterial circulation, followed by

angioplasty and usually stenting to maintain longer-term patency.

CONCLUSION

A DVT can have a significant impact on patients’ quality of life, with iliofemoral DVT posing a major ongoing problem in many patients. Early diagnosis and treatment with thrombolysis or pharmacomechanical thrombectomy in selected patients as well as anticoagulation may have major potential benefits in the long term. **MT**

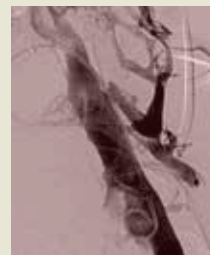REFERENCES

1. National Institute for Health and Clinical Excellence (NICE). Venous thromboembolic diseases: the management of venous thromboembolic diseases and the role of thrombophilia testing (CG144). London: NICE; 2012.
2. Meissner MH, Gloviczki P, Comerota AJ, et al. Society for Vascular Surgery; American Venous Forum. Early thrombus removal strategies for acute deep venous thrombosis: clinical practice guidelines

- of the Society for Vascular Surgery and the American Venous Forum. *J Vasc Surg* 2012; 55: 1449-1462.
3. Ferguson D, O’Sullivan GJ. Which medical device: current devices in the treatment of acute iliofemoral deep vein thrombosis. Newcastle upon Tyne, UK: Which Interventional Device Limited; 2013. Available online at: www.whichmedicaldevice.com/editorial/article/316/current-devices-in-the-treatment-of-acute-iliofemoral-deep-vein-thrombosis (accessed June 2014).
4. Park JY, Ahn JH, Jeon YS, Cho SG, Kim JY, Hong KC. Iliac vein stenting as a durable option for residual stenosis after catheter-directed thrombolysis and angioplasty of iliofemoral deep vein thrombosis secondary to May–Thurner syndrome. *Phlebology* 2013 May 28.
5. Saunders JH, Arya PH, Abisi S, et al. Catheter directed thrombolysis for iliofemoral deep vein thrombosis. *Br J Surg* 2013; 100: 1025-1029.
6. Enden T, Haig Y, Klöw NE, et al; CaVenT Study Group. Long-term outcome after additional catheter-directed thrombolysis versus standard treatment for acute iliofemoral deep vein thrombosis (the CaVenT study): a randomised controlled trial. *Lancet* 2012; 379: 31-38.
7. Comerota AJ, Throm RC, Mathias SD, Haughton S, Mewissen M. Catheter-directed thrombolysis for iliofemoral deep venous thrombosis improves health-related quality of life. *J Vasc Surg* 2000; 32: 130-137.

COMPETING INTERESTS: Dr Robinson has received honoraria for speaking from Bayer and Merck Sharp & Dohme.

Online CPD Journal Program



How does iliofemoral DVT usually present?

Review your knowledge of this topic and earn CPD points by taking part in **MedicineToday’s** Online CPD Journal Program.

Log in to www.medicinetoday.com.au/cpd