

Pancreatic ductal adenocarcinoma

Optimal patient management

JUSTIN GUNDARA PhD, FRACS; **JASWINDER SAMRA** DPhil, FRACS
ANUBHAV MITTAL BHB, MB ChB, PhD, FRACS

Patients with pancreatic ductal adenocarcinoma, the most common type of pancreatic cancer, typically present late with advanced disease. The very nature of pancreatic surgery (with its associated complication profile) means that the management of pancreatic cancer continues to pose significant challenges.

Pancreatic ductal adenocarcinoma (PDAC) has an increasing incidence in Australia, with an estimated 3030 new cases diagnosed in 2015 compared with 1205 cases in 1982. In 2015, PDAC was the tenth most commonly diagnosed cancer type in Australia but the fourth most common cause of cancer-related death. The risk of pancreatic cancer increases with age, and the average age at diagnosis is approximately 70 years.¹

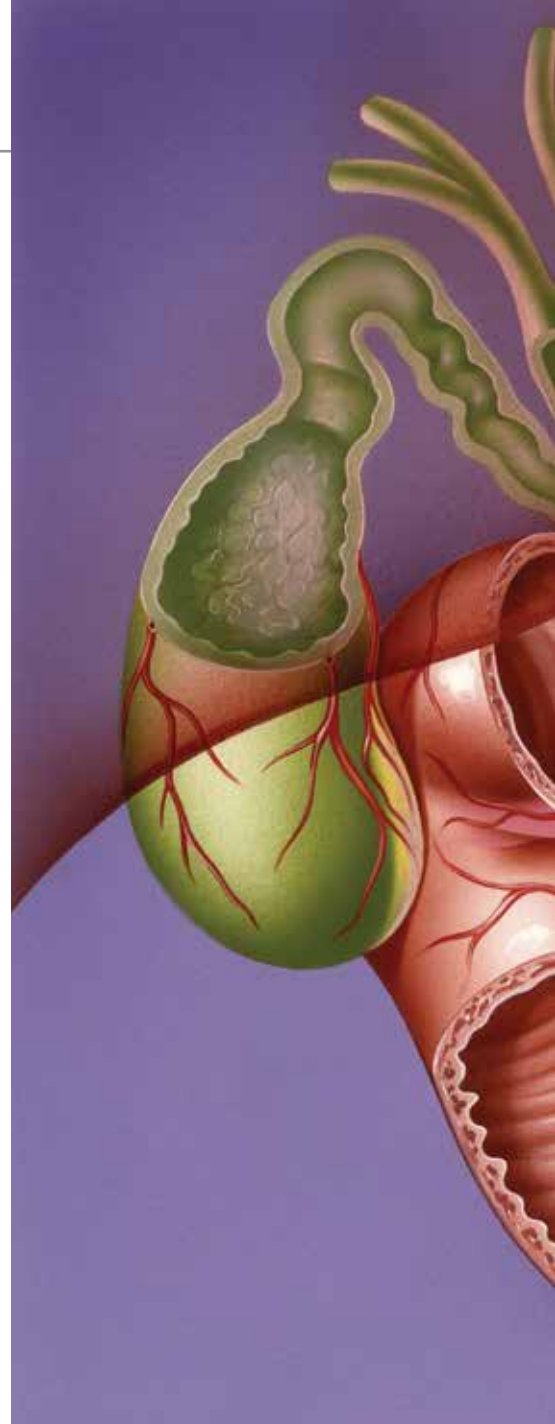
Despite the vast amount of clinical and basic science research conducted in Australia and across the globe, there was

only a marginal increase between 1982 and 2011 in the five-year survival of patients with PDAC (from 4% to 6%).^{1,2} However, there has been a significant reduction in operative morbidity, with clear evidence that patients treated at high-volume pancreatic centres have a better outcome compared with patients treated by low-volume surgeons.^{3,4}

Patients with PDAC typically present late with advanced disease, and the very nature of pancreatic surgery (with its associated complication profile) means that the management of pancreatic cancer continues to pose significant challenges. This brief review summarises the current evidence and up-to-date management protocols that should be used for treating patients with PDAC.

Pathology

Pancreatic cancer can arise from both the exocrine and endocrine parenchyma of the pancreas. However, the vast majority of cancers of the pancreas are exocrine in type, and most of these originate from the



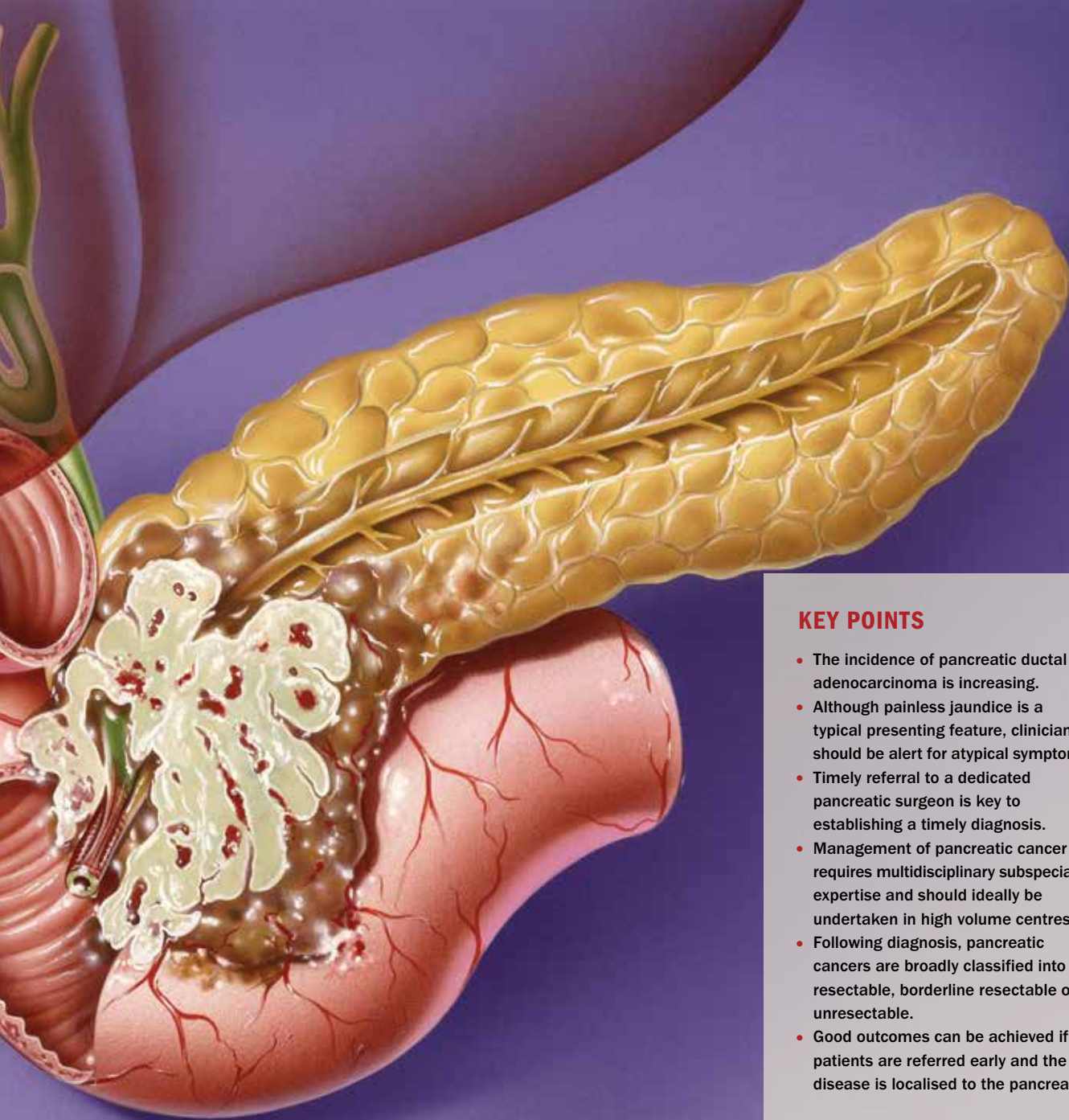ductal epithelium of the pancreas. This review therefore focuses on PDAC.

The most common precursor lesion to PDAC is pancreatic intraepithelial neoplasm (PanIN), followed by intraductal pancreatic mucinous neoplasm (IPMN) and mucinous cystic neoplasm.⁵ PanINs are small, microscopic (less than 5 mm) mucinous-papillary lesions that can become invasive carcinoma through an adenoma–carcinoma sequence. IPMNs and mucinous cystic neoplasms become neoplastic by stepwise genetic alterations.

Recent genetic studies have outlined hundreds of genetic mutations that occur

MedicineToday 2016; 17(4): 14-20

Dr Gundara is Clinical Associate Lecturer and Fellow in Hepatopancreatobiliary (HPB) Surgery, Clinical Professor Samra is a Consultant HPB Surgeon, and Dr Mittal is a Senior Lecturer and Pancreatic Surgeon at the Upper Gastrointestinal Surgical Unit, Royal North Shore Hospital and North Shore Private Hospital, and The University of Sydney, Sydney, NSW.



KEY POINTS

- The incidence of pancreatic ductal adenocarcinoma is increasing.
- Although painless jaundice is a typical presenting feature, clinicians should be alert for atypical symptoms.
- Timely referral to a dedicated pancreatic surgeon is key to establishing a timely diagnosis.
- Management of pancreatic cancer requires multidisciplinary subspecialist expertise and should ideally be undertaken in high volume centres.
- Following diagnosis, pancreatic cancers are broadly classified into resectable, borderline resectable or unresectable.
- Good outcomes can be achieved if patients are referred early and the disease is localised to the pancreas.

in pancreatic cancer.² The common mutations include:

- activation of oncogenes such as *KRAS* (Kirsten rat sarcoma viral oncogene homolog), which is found in more than 90% of pancreatic cancers
- inactivation of tumour suppressor genes such as *TP53* (tumour protein 53), *p16/CDKN2A* (cyclin-dependent kinase inhibitor p16/cyclin-dependent kinase inhibitor 2A) and *SMAD4* (SMAD family member 4)
- inactivation of genes responsible for the repair of DNA, such as *MLH1*

(mutL homolog 1) and *MSH2* (mutS homolog 2).

Most of these mutations are not inherited.

Symptoms and diagnosis

The early symptoms of PDAC are primarily from either or both of mass effect and tumour infiltration of the nerve plexuses adjacent to the pancreas. Most PDAC (60 to 70%) arises in the head of the pancreas, 20% in the body and the tail, and the remaining 10 to 20% diffusely throughout the pancreas.

Tumours located in the body and tail

of the pancreas can grow to a larger size than can tumours located in the head before causing any mass-related symptoms, and are likely to be diagnosed at a more advanced stage than tumours elsewhere in the pancreas. Tumours in the pancreatic head tend to present earlier with obstruction of the pancreatic duct and the common bile duct.⁶

Common presenting symptoms of PDAC can include:

- obstructive symptoms
 - jaundice (common bile duct obstruction)
 - steatorrhea (pancreatic duct

AN APPROACH TO THE INVESTIGATION AND MANAGEMENT OF PANCREATIC DUCTAL ADENOCARCINOMA

Patient presents with suspected pancreatic cancer: jaundice, pain or an incidental finding

Refer patient to a pancreatic surgeon

Perform CT scan (pancreas CT protocol)

Pancreatic mass without biliary obstruction

Pancreatic mass with biliary obstruction

- Confirm PDAC by cytology – endoscopic ultrasound with fine needle aspiration biopsy

- Confirm PDAC by retrograde cholangiopancreatography with brushings
- Insert biliary stent

Classify tumour resectability according to the features below and multidisciplinary team discussion

- Assess stage of cancer
 - CT scan
 - CA 19-9 level
 - laparoscopy
- Assess patient fitness for surgery
 - echocardiogram
 - spirometry
 - comorbidities
 - cardiology, respiratory, anaesthetic assessment

Resectable PDAC

Borderline resectable PDAC

Unresectable PDAC

Perform pancreatoduodenectomy (Whipple resection) or distal pancreatectomy and splenectomy

Treat with neoadjuvant chemotherapy

Consider palliative chemotherapy ± radiotherapy

Re-stage tumour and discuss result with multidisciplinary team

If resectable PDAC, perform extended pancreatoduodenectomy

If unresectable PDAC, consider palliative chemotherapy ± radiotherapy

Abbreviations: CA = cancer antigen; PDAC = pancreatic ductal adenocarcinoma.

- obstruction)
 - gastric outlet obstruction
- infiltrative symptoms
 - abdominal pain (infiltration of nerve plexuses)
- paraneoplastic symptoms
 - weight loss
 - new-onset diabetes.

The diagnosis of a pancreatic mass lesion is usually made through multi-modality investigations. Cross-sectional imaging (CT) is supplemented by a tissue diagnosis of PDAC, via endoscopic retrograde cholangiopancreatography (ERCP; with brushings for cytology) or endoscopic ultrasound (EUS; with fine needle aspiration biopsy).

Preoperative investigations and tumour classification

The aim of preoperative investigations for pancreatic cancer is to classify the pancreatic cancer as resectable, borderline resectable or unresectable.⁷ Both patient factors and tumour-related factors are used to make these distinctions. The investigations should include:

- CT scan of the chest and abdomen with the pancreas CT protocol (triple phase CT) to determine the extent of tumour spread
- ERCP and stenting of the bile ducts with brushings for cytology if there is obstruction of the common bile duct
- EUS and fine needle aspiration of the mass lesion if indicated
- positron emission tomography (PET) if there are indeterminate lesions on CT scan suspicious for metastatic disease
- serum cancer antigen 19-9 (CA 19-9) levels
- anaesthetic work-up, including an echocardiogram and spirometry
- staging laparoscopy to exclude occult peritoneal disease.

The tumour can then be classified as follows:⁷

- resectable – the patient is fit for anaesthesia and the tumour is resectable without vascular resection

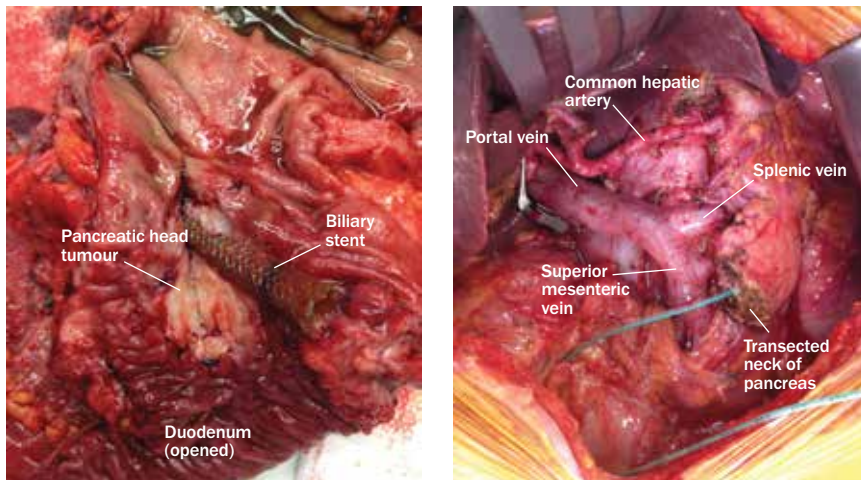


Figure 1. Pancreatic ductal adenocarcinoma. a (left). Resected tumour (with biliary stent). b (right). Resection bed following tumour resection.

- borderline resectable – the tumour can be resected with an extended pancreatoduodenectomy (i.e. with vascular resection [portal vein,

superior mesenteric vein or short segment of the hepatic artery] or with resection of an adjacent organ such as the colon)

- unresectable – the patient is unfit for resection, there is metastatic disease, venous resection is not possible because of lack of suitable reconstructive options, or the tumour involves a long segment of the hepatic artery/superior mesenteric artery/coeliac axis.

A simplified schema for the management of a patient with PDAC from presentation through to treatment is presented in the flowchart.

It is important to note that patients should be referred to an experienced pancreatic centre as soon as the presence of pancreatic disease is suspected. Investigation, staging and intervention occur in parallel in centres with dedicated expertise and infrastructure, a fact that cannot be overstated given the aggressive nature of this disease. Current evidence suggests that delays with diagnosis can lead to far worse oncological outcomes.⁸

Treatment

The treatment of PDAC is based on the classification of the tumour as described above.

Resectable PDAC

The treatment for patients with resectable PDAC is an operation with an aim to remove all of the cancer (microscopically margin-negative – or R0 – resection; Figures 1a and b). For tumours in the head or neck of the pancreas, a pancreatoduodenectomy (Whipple procedure) is performed, with resection of the distal stomach, duodenum, head of the pancreas, bile duct and gallbladder and local lymph node clearance, followed by a reconstruction using a loop of jejunum. Tumours in the body and tail of the pancreas are resected by performing a distal pancreatectomy and splenectomy. Rarely, for diffuse tumours of the pancreas, a total pancreatectomy (pancreatoduodenectomy

and distal pancreatectomy and splenectomy) is performed.

Once the patient has recovered from the surgery, adjuvant chemotherapy is commenced. This has been shown to significantly improve survival.⁴ The choice of chemotherapy drug(s) is based on the patient's performance status after the operation and usually includes gemcitabine either by itself or in combination with paclitaxel. The combination treatment fluorouracil, leucovorin, irinotecan and oxaliplatin is a more toxic combination chemotherapy for PDAC and is reserved for the younger and fitter patient with more advanced disease.⁹

Borderline resectable PDAC

The treatment for patients with borderline resectable PDAC is neoadjuvant chemotherapy followed by re-staging and then an extended pancreatoduodenectomy if appropriate. If there is biliary or gastric

outlet obstruction, endoscopic stenting may be required before starting neoadjuvant chemotherapy; endoscopic stenting is favoured over surgical bypass where technically feasible.¹⁰ If there is pancreatic duct obstruction, oral pancreatic enzyme replacement therapy is prescribed.

Many studies have shown a survival benefit of neoadjuvant chemotherapy for borderline resectable PDAC by improving patient selection for surgery, reducing the number of cancer cells in local lymph nodes and increasing rates of margin-negative (R0) resections.¹¹ Our unit has shown that an extended pancreatoduodenectomy can be carried out safely without an increase in immediate complications or 90-day mortality.¹²

Unresectable PDAC

Patients with unresectable PDAC should be managed without surgery if at all possible. There are plentiful data showing

that palliative surgery in the setting of unresectable PDAC increases morbidity and decreases survival.¹³

Obstruction of the common bile duct and gastric outlet can both be successfully managed by endoscopic insertion of self-expanding metal stents. Palliative chemotherapy with or without radiotherapy is then considered, based on the patient's performance status. The patient should also be referred to palliative care services.

Surgical morbidity

Pancreatic resection carries a risk of significant surgical morbidity. We have shown that pancreatic resections, including vascular and multivisceral resections, can be carried out with low and acceptable morbidity and mortality.^{12,14,15} These results are in agreement with previously published reports that patients have a better outcome if they are operated upon by high-volume pancreatic surgeons.^{3,4}

Follow up

After surgery for pancreatic cancer, patients should have regular follow up with their surgeon and their oncologist. After adjuvant chemotherapy has finished, follow up should be six-monthly with the surgeon, who should request repeat cross-sectional imaging and measurement of serum CA 19-9 level.

It is important that nutritional and endocrine (diabetes) assessment is part of the routine follow up after pancreatic resection. Patients should be asked about their ability to eat fatty meals without developing diarrhoea and to maintain their weight. Six-monthly measurement of glycated haemoglobin (HbA_{1c}) levels and faecal elastase levels (a measure of pancreatic exocrine function) should also be requested.

If the patient has had a splenectomy with the pancreatic resection, local immunisation and prophylactic antibiotic guidelines should be followed for the prevention of overwhelming postsplenectomy sepsis.

The future

The era of personalised medicine is upon us. There are well over 160 biomarkers currently under review for identification of patients likely to benefit from surgical intervention for PDAC.¹⁶ The genetics of pancreatic cancer are also being unravelled and innumerable key driver mutations have been identified to date.² Future research will focus on our ability to identify patients who will benefit most from surgery based on serum/urinary biomarkers and pancreatic cancer genetics from pre-operative biopsy samples. It is also hoped that a better understanding of tumour genetics will help identify new therapeutic targets for oncological therapy. **MT**

References

1. Australian Institute of Health and Welfare (AIHW). Cancer in Australia: an overview 2014. Cancer series No 90. Cat. no. CAN 88. Canberra: AIHW; 2014.
2. Waddell N, Pajic M, Patch AM, et al. Whole genomes redefine the mutational landscape of pancreatic cancer. *Nature* 2015; 518: 495-501.
3. Birkmeyer JD, Siewers AE, Finlayson EV, et al. Hospital volume and surgical mortality in the United States. *N Engl J Med* 2002; 346: 1128-1137.
4. Bilimoria KY, Bentrem DJ, Ko CY, et al. Multimodality therapy for pancreatic cancer in the US: utilization, outcomes, and the effect of hospital volume. *Cancer* 2007; 110: 1227-1234.
5. Cooper CL, O'Toole SA, Kench JG. Classification, morphology and molecular pathology of premalignant lesions of the pancreas. *Pathology* 2013; 45: 286-304.
6. Porta M, Fabregat X, Malats N, et al. Exocrine pancreatic cancer: symptoms at presentation and their relation to tumour site and stage. *Clin Transl Oncol* 2005; 7: 189-197.
7. Katz MH, Pisters PW, Evans DB, et al. Borderline resectable pancreatic cancer: the importance of this

emerging stage of disease. *J Am Coll Surg* 2008; 206: 833-846; discussion 46-48.

8. Gobbi PG, Bergonzi M, Comelli M, et al. The prognostic role of time to diagnosis and presenting symptoms in patients with pancreatic cancer. *Cancer Epidemiol* 2013; 37: 186-190.

9. Gresham GK, Wells GA, Gill S, Cameron C, Jonker DJ. Chemotherapy regimens for advanced pancreatic cancer: a systematic review and network meta-analysis. *BMC Cancer* 2014; 14: 471.

10. Mittal A, Windsor J, Woodfield J, Casey P, Lane M. Matched study of three methods for palliation of malignant pyloroduodenal obstruction. *Br J Surg* 2004; 91: 205-209.

11. Assifi MM, Lu X, Eibl G, Reber HA, Li G, Hines OJ. Neoadjuvant therapy in pancreatic adenocarcinoma: a meta-analysis of phase II trials. *Surgery* 2011; 150: 466-473.

12. De Reuver PR, Mittal A, Neale M, Gill AJ, Samra JS. Extended pancreatoduodenectomy as defined by the International Study Group for Pancreatic Surgery is associated with worse survival but not with increased morbidity. *Surgery* 2015; 158: 183-190.

13. Spanheimer PM, Cyr AR, Liao J, et al. Complications and survival associated with operative procedures in patients with unresectable pancreatic head adenocarcinoma. *J Surg Oncol* 2014; 109: 697-701.

14. Mittal A, de Reuver PR, Shanbhag S, et al. Distal pancreatectomy, splenectomy, and celiac axis resection (DPS-CAR): common hepatic arterial stump pressure should determine the need for arterial reconstruction. *Surgery* 2015; 157: 811-817.

15. Wang F, Gill AJ, Neale M, et al. Adverse tumor biology associated with mesenterico-portal vein resection influences survival in patients with pancreatic ductal adenocarcinoma. *Ann Surg Oncol* 2014; 21: 1937-1947.

16. Petrushko W, Gundara JS, De Reuver P, Hugh TJ, Samra JS, Mittal A. Systematic review of biomarkers in pancreatic ductal adenocarcinoma. *HPB* (accepted).

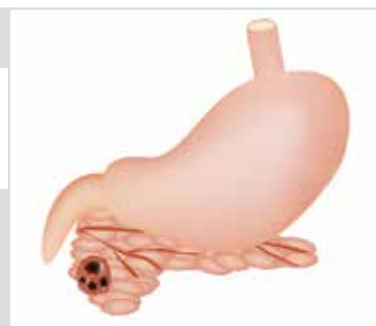COMPETING INTERESTS: None.

ONLINE CPD JOURNAL PROGRAM

What are the common presenting symptoms of pancreatic ductal adenocarcinoma?

Review your knowledge of this topic and earn CPD points by taking part in [MedicineToday's](#) Online CPD Journal Program.

Log in to www.medicinetoday.com.au/cpd



© MIKROSTOKER/DEPOSITPHOTOS