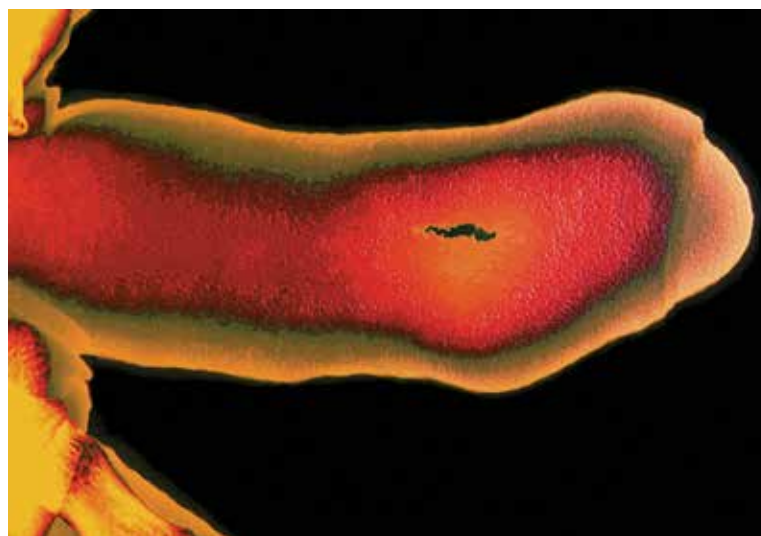


# Peyronie's disease

## Underdiagnosed and undertreated

**CHRISTOPHER LOVE** MB BS, FRACS(Urol)  
**DARREN J. KATZ** MB BS, FRACS(Urol)

**Peyronie's disease is a condition commonly seen in urological practice, but is probably still poorly identified and understood in the wider medical community, and certainly by most of the public. Identifying the condition and appropriately referring affected patients can significantly lessen the physical and psychological effects.**



**T**he development of a bent erection, usually for no obvious reason, causes real concern to men who develop Peyronie's disease (PD), and there is reluctance to talk about it. François Gigot de La Peyronie first described the condition in 1743, but we still do not understand it fully and it has proven resistant to 'cure'.<sup>1</sup> None of our current treatments are able to return the penis to its predisease state, but there is much that treatment can do to improve the patient's situation.

### Aetiology and clinical presentation

Up to 9% of men will have evidence of PD, although the number of men presenting with symptoms is far fewer.<sup>2,3</sup> Peak incidence is in the age range 55 to 60 years. Patients most commonly present with penile curvature, or report feeling a mass in the penis, which is the other common symptom. Painful erection is reported by more than half of patients.<sup>3,4</sup> A history of a remembered penile trauma is reported by about 10% of patients with PD.<sup>5</sup> It should be noted that this disease can have a variable onset, and this variability and unpredictability are features of the condition.

PD is known to be associated with erectile dysfunction (ED), and about 30% of patients with PD have diabetes.<sup>6</sup> PD also has a significant association with obesity, hypertension, hyperlipidaemia, smoking and pelvic surgery.<sup>5-7</sup> An association with Dupuytren's contracture is well recognised.<sup>6</sup>

The condition can cause significant emotional stress, in part as a result of the deformity and associated difficulties with sexual function, but often because of the penile shortening that occurs in almost all patients with PD. Up to 50% of men with PD may be diagnosed with clinical depression.<sup>5</sup>

PD is an abnormal wound healing condition in genetically predisposed men, with the condition precipitated by trauma – presumably predominantly non-remembered microtrauma – to the structural layers of the penis.<sup>8</sup> Abnormal healing results in a fibrous inelastic scar characterised by a palpable mass, which, with an erection, causes curvature, shortening and narrowing of the penis and a hinge effect because the affected part of the penis will not 'stretch'.<sup>9</sup> It is a progressive process, with most

MedicineToday 2016; 17(9): 59-62

Dr Love is a Visiting Urology Consultant at Monash Medical Centre, Melbourne; a Director and Consultant Urological Surgeon at Bayside Urology, Melbourne; a Specialist in Prosthetic Urology at Love Urology, Melbourne; and a Urologist and Penile Implant Surgeon at Men's Health Melbourne, Melbourne (www.drlove.com.au). Dr Katz is the Medical Director at Men's Health Melbourne, Melbourne; a Consultant Urologist, Prosthetic Surgeon and Male Fertility Microsurgeon at various hospitals in Melbourne including Epworth Hospital, Cabrini Hospital, Holmesglen Private Hospital and Western Health; and a Urologist at Bayside Urology, Melbourne.

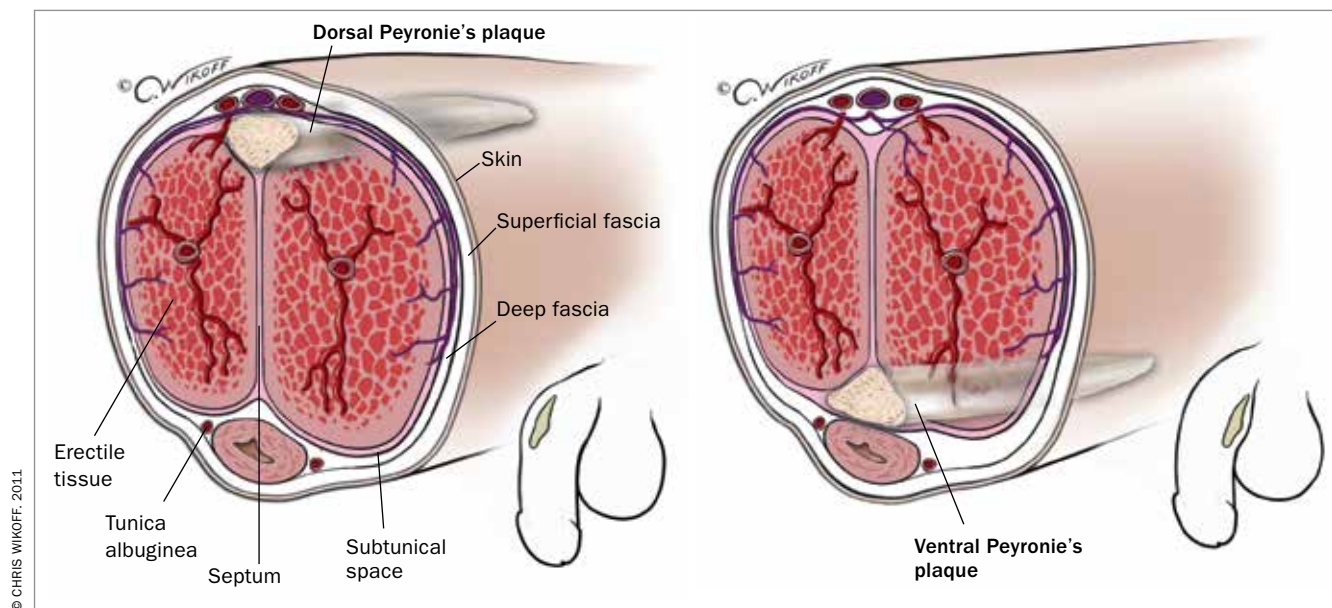


Figure 1. Location of plaques in Peyronie's disease.

men having progression in the first few months after onset, which may not be influenced by early treatment.<sup>10</sup> The condition is generally divided into two phases:

- an acute inflammatory phase that may involve penile pain and curvature progression, although the pain typically resolves spontaneously within 12 months and the curvature usually stabilises;<sup>10</sup>
- a chronic phase, commonly defined as resolution of pain and stability of the curvature for more than three months.

### Patient evaluation

The diagnosis of PD is usually clear from the patient's history and penile examination. The history is important to establish whether the disease is still active, the nature of the curvature and the presence of pre-existing or coexistent ED.

Short disease duration (less than 12 months), ongoing penile pain and continuing changes in penile deformity are likely indications of active inflammatory disease and patients in this phase are not yet surgical candidates.

A patient with PD will usually have either an obvious penile plaque or an area of induration that is palpable on physical examination, even though he may be unaware of it.<sup>11</sup>

In two-thirds of patients, the plaque is located on the dorsal surface of the penis with a corresponding dorsal penile deformity. Lateral and ventral-sited plaques are less common, although these may result in more difficulties with penetration. Multiple plaques located on opposite sides of the penis or plaques appearing in the septum may cause penile shortening with or without a penile deformity (Figure 1).<sup>12</sup>

### Investigations

Generally the diagnosis of Peyronie's disease is based on clinical features. Ultrasound is a useful investigation and can identify the site, extent and consistency of plaque, including calcification. When ultrasound is combined with an intracavernosal vasoactive agent, duplex studies of a patient's penile blood flow parameters facilitate objective assessment of the curvature in the clinic by the specialist.<sup>13</sup>

### Noninvasive therapies

#### Oral therapies

Several oral therapies have been studied in men with PD. They are all used 'off-label' and generally based on low-level evidence. Two of the more commonly used drugs are discussed below.

#### Pentoxifylline (oxpentifylline)

Pentoxifylline (oxpentifylline) is a non-specific phosphodiesterase inhibitor that may increase penile levels of nitric oxide and therefore may prevent progression of PD or reverse its characteristic fibrosis. One study has shown some improvement based on a decrease in plaque calcification among patients with PD taking this medication.<sup>14</sup>

Some patients find pentoxifylline difficult to take, given that ideally it should be used three times per day and that about 5% of patients taking it experience gastrointestinal symptoms (such as nausea, abdominal pain) and/or headache and dizziness.

#### Tadalafil

The phosphodiesterase type 5 (PDE5) inhibitors used to treat ED have been

shown in an animal model to reduce the collagen/smooth muscle and collagen type III/I ratios in the Peyronie's disease-like plaque.<sup>15</sup> In a retrospective study that compared men with ultrasound-confirmed isolated septal scars with a control group without septal scars, daily administration of the PDE5 inhibitor tadalafil resulted in statistically significant resolution of septal scar in 69% of patients compared with 10% in the control group.<sup>16</sup>

The most commonly prescribed medication is tadalafil 5 mg daily. This medication, like all PDE5 inhibitors, can cause headache, facial flushing and dyspepsia in a minority of patients.

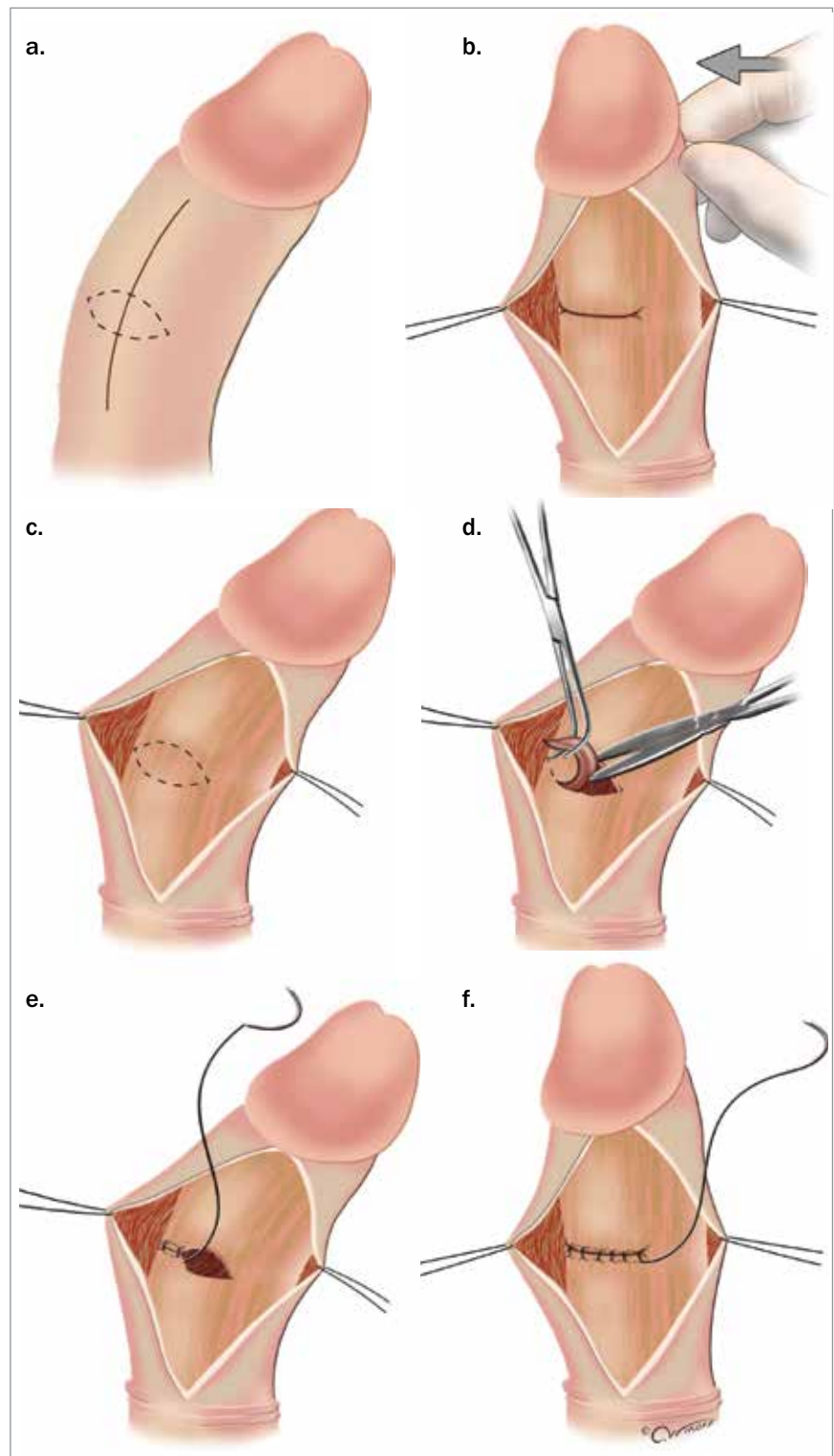
### Intralesional injections

For patients with mild to moderate penile curvature (between 30° and 60° of curvature) and plaques that are not calcified, the use of intralesional injections of collagenase clostridium histolyticum plus physical modelling of the penis has been reported to cause decreases in curvature.<sup>17</sup> In combined analysis of two large (each more than 400 men) prospective randomised, placebo-controlled, double-blind studies the overall response in the treatment group was an average improvement of 34% in penile curvature, whereas in the placebo arm it was 18.2% ( $p < 0.0001$ ).<sup>18</sup> This use of collagenase clostridium histolyticum has just been approved by the TGA in Australia. The treatment involves a series of injections into the Peyronie's plaque. Practitioners interested in learning how to administer the drug should contact the manufacturers of collagenase clostridium histolyticum.

Intralesional verapamil (off-label use) has been shown to affect fibroblast cellular activity. Studies have shown that intralesional verapamil injection induces a significant reduction in penile curvature.<sup>19</sup>

### Other noninvasive therapies

Extracorporeal shock wave therapy has been shown to have only very minor benefit in men with PD; however, some studies



**Figure 2.** Penile plication. In the Nesbit technique (a to f), the penis is straightened by shortening its convex side by excising one or more ellipses of the tunica albuginea at the most prominent part of the curve and then plicating the tunica.

© CHRIS WIKOFF, 2016

### TREATMENT OF MEN WITH PEYRONIE'S DISEASE

#### If rigidity is adequate preoperatively (with or without pharmacotherapy)

- Tunica albuginea plication when:
  - curvature of less than 60°
  - no destabilising hourglass or hinge deformities
  - predicted adequate erectile length
- Plaque incision or excision and grafting when:
  - curvature of more than 60°
  - destabilising hinge or 'hourglass' deformities
  - short penis

#### If rigidity is suboptimal and refractory to medical treatments

- Penile prosthesis implantation, with or without ancillary procedures

have suggested that there is a significant improvement in penile pain with this treatment.<sup>20,21</sup>

It has been shown that gradual expansion of tissue by traction results in the formation of new connective tissue by cellular proliferation in several tissue models including Dupuytren's scar.<sup>22</sup> For patients who are very motivated, a six-month trial of regular, everyday use of a vacuum erection device or penile traction device may result in an improvement in curvature of up to 25%.<sup>23</sup>

### Surgical treatments

Surgery remains the gold standard for correcting erect penile deformity in men with stable disease, particularly as there can be a variable response to other treatments and an unpredictable outcome overall. The most important part of surgery for men with Peyronie's disease is to set appropriate expectations for the patient and to review with them the potential complications of surgery.

Guidelines have advised that surgery is indicated when the man has had stable disease for more than six months, has no pain, difficulty with or inability to engage in sex because of the deformity and desires

the most rapid and reliable result.<sup>24</sup> Various authorities have different recommendations on the minimum time for stable disease before surgery; we believe an absolute minimum of three months of stable, pain-free disease is required before surgery.

The aim of surgery is to correct curvature so the penis is 'functionally' straight (less than 20° of curvature), allowing satisfactory intercourse. Some patients, including some with lesser curvatures, may request surgery for psychological or body image reasons. In the preoperative consultation it is very important to be sure that the patient understands the aim of surgery and that the penis cannot be restored to its previous state. As some men have minor deformities that are functionally not significant, they need to fully understand the risks and realistic outcomes of surgery versus the minor deformity they may have, and in many cases need to be dissuaded from surgery.

There is fairly general agreement that for men with adequate preoperative erectile function and rigidity and curvature of less than 60° some form of procedure to shorten the 'long' (convex) side of the curved penis, such as a tunica albuginea plication (of which the Nesbit procedure is one technique), is indicated (Figure 2). The procedure does not affect erectile function but there may be some perceived length loss and patients may palpate the permanent sutures under the skin.

For men with more severe deformity but still good preoperative rigidity, plaque incision or excision and grafting (lengthening the 'short' side) is recommended.<sup>25</sup> This operation allows patients to maintain penile length but is a complex procedure that requires the mobilisation of all the sensory nerves of the glans and, therefore, has the risk, albeit small, of ED and some sensation loss.

For patients with a significant curvature and impaired erectile function or rigidity that cannot be improved pharmacologically, penile prosthesis implantation with or without ancillary procedures is

recommended.<sup>26</sup> For very complex cases, penile disassembly and reassembly techniques with penile prosthesis implantation may be recommended.<sup>27</sup>

The decision pathway to the appropriate surgical treatment is summarised in the Box.

### Conclusion

PD remains an underdiagnosed and hence undertreated condition. Until the introduction of the recently TGA-approved intralesional collagenase, nonsurgical therapy had limited efficacy. However, because of cost limitations of this drug, surgical correction of PD still remains the most commonly used treatment to achieve a functionally straight penis in most patients. Changes and improvements in surgical techniques, ancillary therapies and the availability of better grafting materials have helped to make surgery for PD a viable and successful treatment option for appropriate patients.

Surgical therapy is beneficial for properly selected and counselled patients, and can greatly improve their quality of life. The urologist must tailor the therapy for each patient.

MT

### References

A list of references is included in the website version of this article ([www.medicinetoday.com.au](http://www.medicinetoday.com.au)).

COMPETING INTERESTS: Dr Love is a paid consultant for American Medical Systems and Coloplast, both of which are manufacturers of penile implants; and a member of the Australian Scientific Advisory Panel for Actelion, suppliers of collagenase clostridium histolyticum. Dr Katz is a member of the Australian Scientific Advisory Panel for Actelion, suppliers of collagenase clostridium histolyticum.



### Studying medicine?

Or know someone who is? For our special subscription rates for medical students, contact: Therese on (02) 9908 8577 or email: [reception@medicinetoday.com.au](mailto:reception@medicinetoday.com.au)

# Peyronie's disease

## Underdiagnosed and undertreated

**CHRISTOPHER LOVE** MB BS, FRACS(Urol); **DARREN J. KATZ** MB BS, FRACS(Urol)

### References

- Musitelli S, Bossi M, Jallous H. A brief historical survey of 'Peyronie's disease'. *J Sex Med* 2008; 5: 1737-1746.
- Smith CJ, McMahon C, Shabsigh R. Peyronie's disease: the epidemiology, aetiology and clinical evaluation of deformity. *BJU Int* 2005; 95: 729-732.
- Mulhall JP, Creech SD, Boorjian SA, et al. Subjective and objective analysis of the prevalence of Peyronie's disease in a population of men presenting for prostate cancer screening. *J Urol* 2004; 171: 2350-2353.
- Taylor FL, Levine LA. Peyronie's disease. *Urol Clin North Am* 2007; 34: 517-534.
- Kadioglu A, Tefekli A, Erol B, Oktar T, Tunc M, Tellaloglu S. A retrospective review of 307 men with Peyronie's disease. *J Urol* 2002; 168: 1075-1079.
- Bjekic MD, Vlajinac HD, Sipetic SB, Marinkovic JM. Risk factors for Peyronie's disease: a case-control study. *BJU Int* 2006; 97: 570-574.
- Arafa M, Eid H, El-Badry A, Ezz-Eldine K, Shamloul R. The prevalence of Peyronie's disease in diabetic patients with erectile dysfunction. *Int J Impot Res* 2007; 19: 213-217.
- Devine CJ Jr, Somers KD, Jordan SG, Schlossberg SM. Proposal: trauma as the cause of the Peyronie's lesion. *J Urol* 1997; 157: 285-290.
- Brock G, Hsu GL, Nunes L, von Heyden B, Lue TF. The anatomy of the tunica albuginea in the normal penis and Peyronie's disease. *J Urol* 1997; 157: 276-281.
- Mulhall JP, Schiff J, Guhring P. An analysis of the natural history of Peyronie's disease. *J Urol* 2006; 175: 2115-2118.
- Pryor J, Akkus E, Alter G, et al. Peyronie's disease. *J Sex Med* 2004; 1: 110-115.
- Pryor JP, Ralph DJ. Clinical presentations of Peyronie's disease. *Int J Impot Res* 2002; 14: 414-417.
- Berookhim BM. Doppler Duplex ultrasonography of the penis. *J Sex Med* 2016; 13: 726-731.
- Smith JF, Shindel AW, Huang YC, et al. Pentoxifylline treatment and penile calcifications in men with Peyronie's disease. *Asian J Androl* 2011; 13: 322-325.
- Ferrini MG, Kovanecz I, Nolzaco G, Rajfer J, Gonzalez-Cadavid NF. Effects of long-term vardenafil treatment on the development of fibrotic plaques in a rat model of Peyronie's disease. *BJU Int* 2006; 97: 625-633.
- Chung E, Deyoung L, Brock GB. The role of PDE5 inhibitors in penile septal scar remodeling: assessment of clinical and radiological outcomes. *J Sex Med* 2011; 8: 1472-1477.
- Jordan GH. The use of intralesional clostridial collagenase injection therapy for Peyronie's disease: a prospective, single-center, non-placebo-controlled study. *J Sex Med* 2008; 5: 180-187.
- Gelbard M, Goldstein I, Hellstrom WJ, et al. Clinical efficacy, safety and tolerability of collagenase clostridium histolyticum for the treatment of peyronie disease in 2 large double-blind, randomized, placebo controlled phase 3 studies. *J Urol* 2013; 190: 199-207.
- Levine LA, Goldman K, Greenfield J. Experience with intraplaque injection of verapamil for Peyronie's disease. *J Urol* 2002; 168: 621-626.
- Hauck EW, Hauptmann A, Bschiepfer T, Schmelz HU, Altinkilic BM, Weidner W. Questionable efficacy of extracorporeal shock wave therapy for Peyronie's disease: results of a prospective approach. *J Urol* 2004; 171: 296-299.
- Hatzichristodoulou G, Meisner C, Gschwend JE, Stenzl A, Lahme S. Extracorporeal shock wave therapy in Peyronie's disease: results of a placebo-controlled, prospective, randomized, single-blind study. *J Sex Med* 2013; 10: 2815-2821.
- Chung E, De Young L, Solomon M, Brock GB. Peyronie's disease and mechanotransduction: an in vitro analysis of the cellular changes to Peyronie's disease in a cell-culture strain system. *J Sex Med* 2013; 10: 1259-1267.
- Chung E, Brock G. Penile traction therapy and Peyronie's disease: a state of art review of the current literature. *Ther Adv Urol* 2013; 5: 59-65.
- Ralph D, Gonzalez-Cadavid N, Mirone V, et al. The management of Peyronie's disease: evidence-based 2010 guidelines. *J Sex Med* 2010; 7: 2359-2374.
- Levine LA, Lenting E. A surgical algorithm for the treatment of Peyronie's disease. *J Urol* 1997; 158: 2149-2152.
- Mulhall JP, Anderson M, Parker M. A surgical algorithm for men with combined Peyronie's disease and erectile dysfunction: functional and satisfaction outcomes. *J Sex Med* 2005; 2: 132-138.
- Perovic SV, Djordjevic ML. The penile disassembly technique in the surgical treatment of Peyronie's disease. *BJU Int* 2001; 88: 731-738.